

**Luis A. Sanchez, M.D.**  
Chief Medical Examiner



(713) 796-9292  
FAX: (713) 796-6844


**JOSEPH A. JACHIMCZYK FORENSIC CENTER**

STATE OF TEXAS


COUNTY OF HARRIS

I, Luis A. Sanchez, M.D., Chief Medical Examiner of Harris County, do hereby certify that the attached autopsy report and toxicology report (where applicable) represent a true and correct copy of the Autopsy/External Examination findings on the body of Edward S. Fatu, Case # ML09-3869.

Witness my hand in Harris County, Texas, this 16 day of March, 2010.

  
\_\_\_\_\_  
Chief Medical Examiner  
Harris County, Texas

Subscribed and sworn to before me this 16 day of March, 2010.



  
\_\_\_\_\_  
Notary Public, Harris County, Texas

Luis A. Sanchez, M.D.  
Chief Medical Examiner



(713) 796-9292  
FAX: (713) 796-6844

JOSEPH A. JACHIMCZYK FORENSIC CENTER

AUTOPSY REPORT

Case No. ML09-3869

December 5, 2009


ON THE BODY OF

Edward S. Fatu  
6003 Pinecreek Ridge Court  
Spring, Texas

CAUSE OF DEATH: Acute toxicity due to the combined effects of  
hydrocodone, carisoprodol, and diazepam

MANNER OF DEATH: Accident

DATE OF DEATH: December 4, 2009

 3/4/10  
Roger A. Mitchell, Jr., M.D. MMDDYY  
Assistant Deputy Chief Medical Examiner

ML09-3869

-2-

## POSTMORTEM EXAMINATION ON THE BODY OF

Edward S. Fatu  
6003 Pinecreek Ridge Court  
Spring, Texas

**HISTORY:** This is a 36 year old Asian-Samoan male, with a past medical history of cardiac disease and substance abuse, who was pronounced dead in the emergency room at Houston Northwest Medical Center 29 hours after arrival at 4:20 p.m. on December 4, 2009.

**AUTOPSY:** The autopsy is performed in the Joseph A. Jachimczyk Forensic Center of Harris County by Assistant Deputy Chief Medical Examiner Roger A. Mitchell, Jr., M.D., pursuant to Article 49.25, Texas Code of Criminal Procedure, beginning at 9:30 a.m. on December 5, 2009.

**CLOTHING:** The body is received unclad.

**EXTERNAL APPEARANCE:** The body is of a well developed, well nourished, large-framed, 78 inch, 406 pound Asian-Samoan male whose appearance is consistent with the given age of 36 years. The black straight scalp hair is shaven on the sides and back, and has a 13 inch ponytail off the top of the head. The face has a goatee with stubble about the chin and cheeks. The eyes have brown irides and the conjunctivae are without petechiae, jaundice or hemorrhage. The mouth has natural teeth in good repair. The torso is unremarkable except for a protuberant abdomen. The extremities have needle track marks or injuries. The external genitalia are of a normal circumcised man.

**SCARS:** There is a 3 inch oblique well healed scar on the left side of the abdomen and lower chest.

**TATTOOS:** There are multiple monochromatic and polychromatic tattoos involving the bilateral shoulders, chest and forearms. There is a complex design monochromatic tattoo involving the entire back, as well as the word "SAMOA" across the anterior belly. There are multi-complex design tattoos on the back of the calves bilaterally.



Edward S. Fatu

ML09-3869

-3-

**POSTMORTEM CHANGES:** There is moderate symmetrical rigor mortis of the upper and lower extremities, neck and jaw. The lividity is pink, posterior, and partially blanching. The body is cool subsequent to refrigeration.

**THERAPEUTIC PROCEDURES:** In place are an endotracheal tube and an orogastric tube. There is a cutaneous thermometer device on the forehead. There is a triple lumen intravenous access catheter in the left subclavian region and the right femoral triangle. There is double intravenous access in the left antecubital fossa and posterior surface of the right hand. There is a Foley urinary catheter in place.

**EVIDENCE OF INJURIES, EXTERNAL AND INTERNAL:** There are none.

**INTERNAL EXAMINATION:**

**BODY CAVITIES:** The organs are in their normal situs. There are 300 milliliters of bloody ascites fluid in the peritoneal cavity. The pericardial and pleural cavities are without hemorrhage, adhesions or excess fluid.

**HEAD AND CENTRAL NERVOUS SYSTEM:** The scalp has no contusion. The skull has no fracture. There is no epidural, subdural, or subarachnoid hemorrhage. The brain weighs 1450 grams and has a glistening leptomeninges. The brainstem and cerebellum are unremarkable. The cerebral vessels are without aneurysms or atherosclerosis. The cranial nerves are normally distributed. Cut sections reveal an unremarkable gray and white matter and deep nuclear structures. The ventricles have a normal size and shape. There are no focal lesions.

**NECK:** The cervical vertebrae, hyoid bone, tracheal and laryngeal cartilages, and paratracheal soft tissues are unremarkable except for posterior pharyngeal soft tissue hemorrhage secondary to traumatic intubation. The upper airway is patent. The tongue is unremarkable.

**CARDIOVASCULAR SYSTEM:** The heart weighs 700 grams and has a normal distribution of right predominant coronary arteries without atherosclerotic stenosis of any epicardial vessels. The myocardium is dark red and firm without hemorrhage, softening, or fibrosis. The left ventricular wall measures 2.1 centimeters, and the right measures 0.6 centimeter thick. The endocardial surfaces and four cardiac valves are

Edward S. Fatu

ML09-3869

-4-

unremarkable. The valvular circumferences are as follows: tricuspid valve 14 centimeters, pulmonic valve 7 centimeters, mitral valve 12 centimeters, and aortic valve 7 centimeters. The aorta is unremarkable. The pulmonary arteries are without thrombus or embolus.

**RESPIRATORY SYSTEM:** The right lung weighs 1225 grams and the left weighs 1200 grams. The markedly congested and edematous pulmonary parenchyma is without consolidation, obstruction or emphysema. The bronchi are moderately hyperemic.

**HEPATOBIILIARY SYSTEM:** The liver weighs 2300 grams and has an intact capsule. The red-brown and yellow parenchyma has early putrefactive changes, with green discoloration. There is no fibrosis and there is slight steatosis. The gallbladder contains 23 milliliters of green viscous bile without stones.

**RETICULOENDOTHELIAL SYSTEM:** The spleen weighs 250 grams and has an intact capsule. The color, red and white pulp, and consistency are unremarkable. There are no enlarged lymph nodes. The bone marrow, where observed, is unremarkable.

**ENDOCRINE SYSTEM:** The thyroid and adrenal glands have a normal color, size, and consistency. There is peripancreatic hemorrhage with focal involvement of the head of the pancreas.

**GENITOURINARY SYSTEM:** The right kidney weighs 300 grams and the left weighs 290 grams. The markedly congested and edematous kidneys have a slightly granular appearance. The architecture and vasculature are unremarkable. The ureters maintain uniform caliber into an unremarkable empty urinary bladder. The urinary bladder mucosa has focal areas of hyperemia and submucosal hemorrhage secondary to Foley urinary catheter placement. The prostate is not enlarged. The testicles are unremarkable.

**GASTROINTESTINAL SYSTEM:** The esophagus and gastroesophageal junction are unremarkable. There is diffuse hyperemia of the duodenum and small bowel with serosal hemorrhage involving the duodenum and pancreatic head. There are 450 milliliters of granular, brown gastric contents. The gastric mucosa is unremarkable. There are 3500 milliliters of bloody fluid in the small and large intestines. The



Edward S. Fatu

ML09-3869

-5-

vermiform appendix is present. The mucosal surfaces of the small and large intestines are unremarkable.

**MUSCULOSKELETAL SYSTEM:** The clavicles, sternum, ribs, and pelvis are without fractures. The musculature is normally distributed.

**TOXICOLOGY:** Specimens are submitted for toxicological evaluation.

**HISTOLOGY:** Specimens are submitted for histological evaluation.

#### PATHOLOGICAL DIAGNOSES

- I. Acute Toxicity due to the combined effects of hydrocodone, carisoprodol, and diazepam
  - A. Hydrocodone (blood 12/3/09 @ 1150) - 0.22 mg/L
  - B. Carisoprodol (blood 12/3/09 @ 1150) - 11 mg/L
  - C. Diazepam (blood 12/3/09 @ 1150) - 0.06 mg/L
- II. Hypertensive cardiovascular disease
  - A. Hypertrophy of the heart (700 grams)
    1. Left ventricular hypertrophy (2.1 centimeters)
    2. Myocardial fibrosis, marked
  - B. Pulmonary congestion and edema, marked
  - C. Bronchopneumonia, moderate to marked
- III. Clinical diagnosis of:
  - A. Disseminated intravascular coagulopathy with epistaxis (nose bleed/oropharyngeal bleeding)
    1. 3500 milliliters of bloody diarrhea found in lower gastrointestinal tract
  - B. Anion gap metabolic acidosis
  - C. Acute renal failure
  - D. Acute hepatic injury ("shock liver")
    1. Elevated transaminase (elevated liver enzymes)
  - E. Anoxic encephalopathy

OFFICE OF THE MEDICAL EXAMINER OF HARRIS COUNTY  
JOSEPH A. JACHIMCZYK FORENSIC CENTER  
1885 OLD SPANISH TRAIL  
HOUSTON, TEXAS 77054-2098

Roger A. Mitchell, Jr., M.D.  
Assistant Deputy Chief Medical Examiner

ML09-3869

MICROSCOPIC EXAMINATION


HEART Diffuse myocyte hypertrophy, marked; patchy interstitial fibrosis; patchy replacement fibrosis with myocyte drop-out; focal myocyte necrosis, moderate; conduction system within normal limits

LUNG Diffuse intra-alveolar neutrophils and reactive macrophages; patchy intra-alveolar hemorrhage; focal septal necrosis, moderate

LIVER No significant histological abnormality

KIDNEY Small and medium vessel hyalinization, moderate to marked

BRAIN No significant histological abnormality

  
Roger A. Mitchell, Jr., M.D.

3/4/10

MMDDYY

Assistant Deputy Chief Medical Examiner

JOSEPH A. JACHIMCZYK FORENSIC CENTER  
1885 OLD SPANISH TRAIL  
HOUSTON, TEXAS 77054-2098

CASE NO: ML09-3869DECEDENT'S NAME: Edward Fatu

DOCTOR'S SIGNATURE: \_\_\_\_\_

9:30A

12/5/09

13" pony Tail  
H Shaved on side

E: S22 PPHH

E: P

M. Good

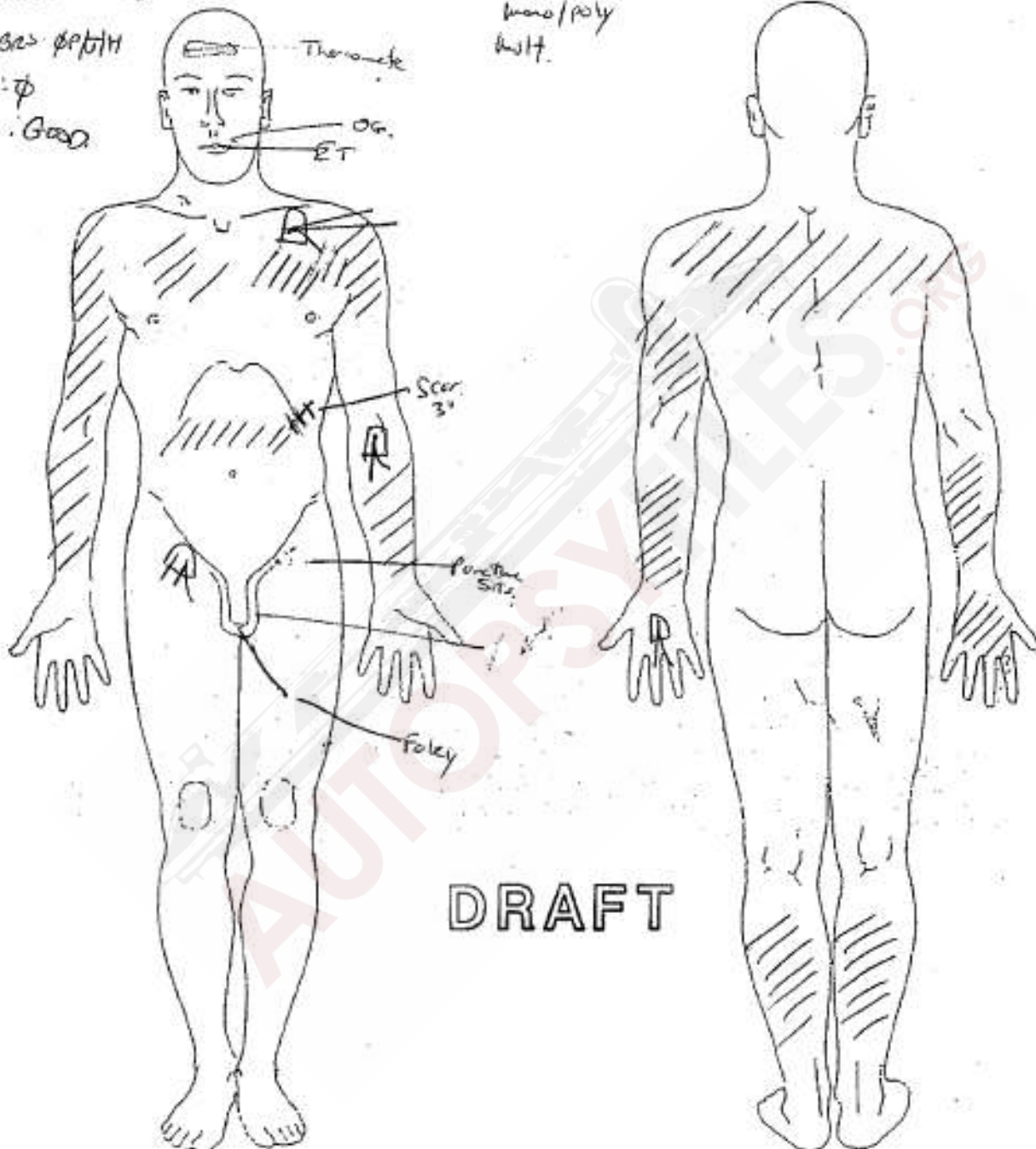
////-Tattoo  
mono/poly  
bult.

78"

406lbs

36yo

AM



DRAFT



**OFFICE OF THE MEDICAL EXAMINER OF HARRIS COUNTY  
JOSEPH A. JACHIMCZYK FORENSIC CENTER**

1885 Old Spanish Trail  
Houston, Texas 77054-2098  
Phone: 713-796-6830 Fax: 713-796-6838

**LABORATORY REPORT**

December 31, 2009

LABORATORY NUMBER: ML09-3869



Deceased: EDWARD S. FATU

**Submitted By:**

Roger Mitchell, Jr., M.D.  
Assistant Medical Examiner  
Harris County Medical Examiner  
1885 Old Spanish Trail  
Houston, TX 77054

Agency Number: ML09-3869  
Submission Date: December 05, 2009

**Specimen: Blood (12/03/09@1150)**

Analyte	Result	Analytical Method
Carisoprodol	11 mg/L	GC/MS
Diazepam	0.06 mg/L	LC/MS/MS
Hydrocodone	0.22 mg/L	LC/MS/MS
Hydromorphone	Less than 0.01 mg/L	LC/MS/MS
Meprobamate	32 mg/L	GC/MS
Nordiazepam	0.04 mg/L	LC/MS/MS
Standard Basic Drug Screen	Quantity not sufficient	GC/MS

**Specimen: Stomach Contents**

Analyte	Result	Analytical Method
Carisoprodol	Less than 125 mg/L	GC/MS
Meprobamate	Less than 125 mg/L	GC/MS

**Specimen: Vitreous Humor**

Analyte	Result	Analytical Method
Chloride	121 mEq/L	Ion Selective Electrode
Creatinine	0.8 mg/dL	Spectrophotometric
Potassium	11.2 mEq/L	Ion Selective Electrode
Sodium	153 mEq/L	Ion Selective Electrode
Urea Nitrogen	28 mg/dL	Spectrophotometric

**Specimen: Blood (12/03/09@1150)**

Analyte	Result	Analytical Method
6-monoacetylmorphine	None Detected	LC/MS/MS
7-aminoclonazepam	None Detected	LC/MS/MS
Alprazolam	None Detected	LC/MS/MS
Amphetamine	None Detected	Immunoassay
Barbiturates	None Detected	Immunoassay
Clonazepam	None Detected	LC/MS/MS
Cocaine Metabolite	None Detected	Immunoassay

Medical Examiner's Initial 

Unless otherwise requested, toxicology specimens will be discarded one year after date of receipt.  
This Laboratory is Accredited by ASCLD/LAB-International and ABFT.

Page 1 of 2

LABORATORY NUMBER: ML09-3869

DATE: December 31, 2009

**Specimen: Blood (12/03/09@1150)****Analyte**

Codeine  
Desalkylflurazepam  
Ethanol, Methanol, Isopropanol, Acetone  
Lorazepam  
Marijuana Metabolite  
Methadone  
Methamphetamine  
Morphine  
Other Standard Acidic Drugs  
Oxazepam  
Oxycodone  
Phencyclidine  
Temazepam  
Triazolam

**Result**

None Detected  
None Detected  
None Detected  
None Detected  
None Detected  
None Detected  
None Detected  
None Detected  
None Detected  
None Detected  
None Detected  
None Detected  
None Detected  
None Detected

**Analytical Method**

LC/MS/MS  
LC/MS/MS  
Headspace GC  
LC/MS/MS  
Immunoassay  
Immunoassay  
Immunoassay  
LC/MS/MS  
GC/MS  
LC/MS/MS  
LC/MS/MS  
Immunoassay  
LC/MS/MS  
LC/MS/MS

**Specimen: Vitreous Humor****Analyte**

Glucose  
Ketones

**Result**

None Detected  
None Detected

**Analytical Method**


Spectrophotometric  
Color Test



Meagan Wilbur, B.S., CLS-CC, FTS-ABFT  
Toxicologist II  
December 31, 2009



Fesseesework Gualle, DVM, D-ABVT, FTS-ABFT  
Toxicologist I  
December 31, 2009

Medical Examiner's Initial 

Unless otherwise requested, toxicology specimens will be discarded one year after date of receipt.  
This Laboratory is Accredited by ASCLD/LAB-International and ABFT.

Page 2 of 2