

PROVISIONAL ( )  
FINAL (X)

TENNESSEE DEPARTMENT OF PUBLIC HEALTH  
OFFICE OF THE CHIEF MEDICAL EXAMINER  
858 Madison Avenue  
Memphis, Tennessee 38103

CASE NO. A68-252  
COUNTY Shelby

## AUTOPSY REPORT

NAME OF DECEDENT Martin Luther King, Jr. RACE N SEX M AGE 39  
HOME ADDRESS Atlanta, Georgia  
NUMBER OR STREET CITY OR TOWN STATE

COUNTY MEDICAL EXAMINER J. T. Francisco, M.D.  
ADDRESS Memphis, Tennessee


DISTRICT ATTORNEY GENERAL Phil A. Canale  
ADDRESS Memphis, Tennessee

ANATOMICAL DIAGNOSIS Gunshot wound to body and face with:  
Fracture of mandible  
Laceration vertebral artery, jugular vein and sub-  
clavian artery, right,  
Laceration of spinal cord (lower cervical, upper  
thoracic),  
Intrapulmonary hematoma, apex, right upper lobe

CAUSE OF DEATH Gunshot wound to spinal column, lower cervical, upper  
thoracic

NARRATIVE OF FINDINGS Death was the result of a gunshot wound to the  
chin and neck with a total transection of the lower cervical and  
upper thoracic spinal cord and other structures in the neck. The  
direction of the wounding was from front to back, above downward and  
from right to left. The severing of the spinal cord at this level  
and to this extent was a wound that was fatal very shortly after its  
occurrence.

The purpose of this report is to provide a certified opinion to the County Medical Examiner and the District Attorney General. The facts and findings to support these conclusions are filed with the office of the State Medical Examiner.

DATE April 11, 1968 SIGNATURE:  M.D.  
ADDRESS 858 Madison Avenue-Memphis, Tennessee

Form 388

**THE CITY OF MEMPHIS HOSPITALS  
AUTOPSY PROTOCOL**

Autopsy No. A68-252      Service Med. Ex.      Hospital No.  
Name Martin Luther King, Jr.      Age 39      Race Negro Sex Male  
Date of Admission DOA      Date and Hour of Death 4-4-68 P.M. Unknown-Approximately  
Date and Hour of Autopsy 4-4-68 10:45 P.M.  
Pathologist Drs. Sprunt and Francisco      Assistant  
Checked by      Date Completed 4-11-68

FINAL PATHOLOGICAL DIAGNOSIS

PRIMARY SERIES:

- I. Distant gunshot wound to body and face
  - A. Fracture of right mandible
  - B. Laceration of vertebral artery, jugular vein and subclavian artery, right
  - C. Fracture of spine (T-1, C-7)
  - D. Laceration of spinal cord (lower cervical, upper thoracic )
  - E. Submucosal hemorrhage, larynx
  - F. Intrapulmonary hematoma, apex right upper lobe

SECONDARY SERIES:

1. Remote scars as described
2. Pleural adhesions
3. Fatty change liver, moderate
4. Arteriosclerosis, moderate
5. Venous cut-downs
6. Tracheostomy

LABORATORY FINDINGS:

Blood Alcohol - 0.01%

A68-252

EXTERNAL EXAMINATION OF THE BODY

This is a well developed, well nourished Negro male measuring 69 1/2 inches in length and weighing approximately 140 pounds. The hair is black, the eyes are brown. There is a line mustache present.

EXTERNAL MARKS AND SCARS

There is a remote midline scar present in the center of the chest and a remote scar present extending to the right axilla measuring 8 inches in length. There is a sutured vertical surgical incision present at the base of the neck. A sutured incision is present in the right chest at the anterior axillary line. Three needle punctures are present in the precordium, having no hemorrhage present surrounding the area. There are blood splatters present on the palm and dorsum of the right hand. A remote scar is present in the right lateral chest. Sutured incisions are present in the left ante cubital fossa, one that is obliquely directed measuring 2 inches in length, one that is horizontally directed measuring 1 inch in length. There are two sutured incisions present on the medial aspect of the left ankle. The superior incision measuring 2 inches in length, the inferior incision measuring 1/4 inch in length. There is an extensive excavating lesion affecting the right side of the face beginning at a point 1 inch lateral to the right corner of the mouth and 1/2 inch inferior to the right corner of the mouth that measures approximately 3 inches in length. At the superior aspect of this gaping wound there is an abrasion collar that measures 1/8 of an inch in maximum thickness, having brownish discoloration present at the superior margin. Adjacent to this area there is extensive laceration of the soft tissues of the face with a fracturing of the right side of the mandible. A re-approximation of the tissues reveals the laceration to extend to the base of the neck and into the base of the neck with intervening skin unaffected in this area. The second penetrating wound at the base of the neck in the superior aspect of the chest measures 3 inches in length. The missile path is through the external jugular vein and vertebral artery. There is a penetration into the lateral aspect of the base of the neck into the upper thoracic and lower cervical cord totally severing the lower cervical and upper thoracic cord passing through the spinal column at the level of C7 and T1 into the posterior aspect of the back. The bullet is removed from the posterior aspect of the back, 56 inches superior to the right heel and 55 1/2 inches superior to the left heel, 3 inches to the left of the midline of the spine in the medial aspect of the left scapula. The entrance wound is 61 1/2 inches superior to the right heel and 59 inches superior to the right heel with the head turned and positioned so that the wound in the face corresponds with the path of the missile into the neck and spine. The total thickness from the entrance wound to the posterior aspect of the back is 8 1/2 inches in thickness. The angle of the penetrating wound is approximately 45° from a sagittal plane at an angle from right to left inferiorly and anterior to posteriorly at about a 30° angle with a coronal plane.

SECTION

The abdominal panniculus measures an inch in maximum thickness. The skeletal muscles are red and fibillary. There is scarring present over the right anterior-superior chest with pleural adhesions present in this area.

continued.....

Page 2.....  
A68-252

BODY CAVITIES

There is approximately 25cc. of blood present within the right thoracic cavity and some subpleural hemorrhage that is present affecting the right and the left in the posterior apex. The missile did not enter the right pleural cavity.

GROSS DESCRIPTION OF THE ORGANS

**HEART:** The heart weighs 450 grams. The myocardium is pale brown. The valvular surfaces reveal no significant changes. There is focal yellowing of the subendocardial areas affecting the left aspect of the interventricular septum. The right ventricle measures 5mm. in maximum thickness. The left ventricle measures 20mm. in maximum thickness. The coronary ostia originate in normal position and have a normal distribution over the epicardial surface. There is minimal intimal proliferation present. Focal yellow plaquing is present in the ascending aspect of the aortic arch but ulceration is not present. There is no significant dilatation affecting the chambers of the heart.

**AORTA:** Focal yellow plaques are present throughout the aorta but ulceration and calcification is not present. The great vessels originate normally. There is perivascular hemorrhage affecting the right carotid artery but no penetration of the wall. The right subclavian artery is lacerated.

**ESOPHAGUS:** Partially digested food fragments are present throughout the esophagus.

**TRACHEA:** Hemorrhagic mucoid material is present throughout the upper trachea.

**LUNGS:** The right lung weighs 300 grams. The left lung weighs 325 grams. There is diffuse congestion, consolidation and hemorrhage affecting the right upper lobe of the lung. Frothy fluid is expressible from the sectioned surface. There is minimal wrinkling of the pleura diffusely throughout the pulmonary parenchyma.

**BRAIN:** The brain weighs 1400 grams. There is some flattening of the gyri and narrowing of the sulci. The cerebral vessels are symmetrical. There is no subdural, epidural, or extradural hemorrhage present. There is no significant flattening throughout the cerebral vessels.

**KIDNEYS:** The kidneys weigh 175 grams on the left and 150 grams on the right. The capsular surface is smooth. The parenchyma is of normal coloration. The cortical-medullary junction is prominent.

continued.....

Page 3.....  
A68-252

**PANCREAS:** The pancreatic parenchyma is well preserved. The lobular pattern is preserved. There is no fatty infiltration present. The parenchyma is yellowish-grey.

**LARYNX:** There is diffuse hemorrhage present throughout the superior larynx along with submucosal hemorrhage that is present within the intra-laryngeal areas. There is a tracheostomy perforation that is superior to the thyroid penetrating to the right of the pyramidal lobe.

**THYROID:** No significant changes.

**SPLEEN:** The spleen weighs 80 grams. The capsule is wrinkled. There is no capsular thickening present. The follicles are not prominent.

**STOMACH:** The stomach contains approximately 10cc. of partially digested food fragments. There is no ulceration present.

**DUODENUM:** No significant changes.

**GALLBLADDER:** The gallbladder contains approximately 5cc. of light green bile. No stones are present.

**LIVER:** The liver weighs 1600 grams. The parenchyma is pale yellowish-brown. The lobular pattern is accentuated. The parenchyma is quite soft.

**BLADDER:** There is approximately 25cc. of cloudy yellow urine present.

**PROSTATE:** No significant gross abnormalities are present.

**COLON:** The appendix is present. The colonic contents is normal.

**SMALL INTESTINE:** There is alternately liquid and gaseous distention present throughout the small intestine.

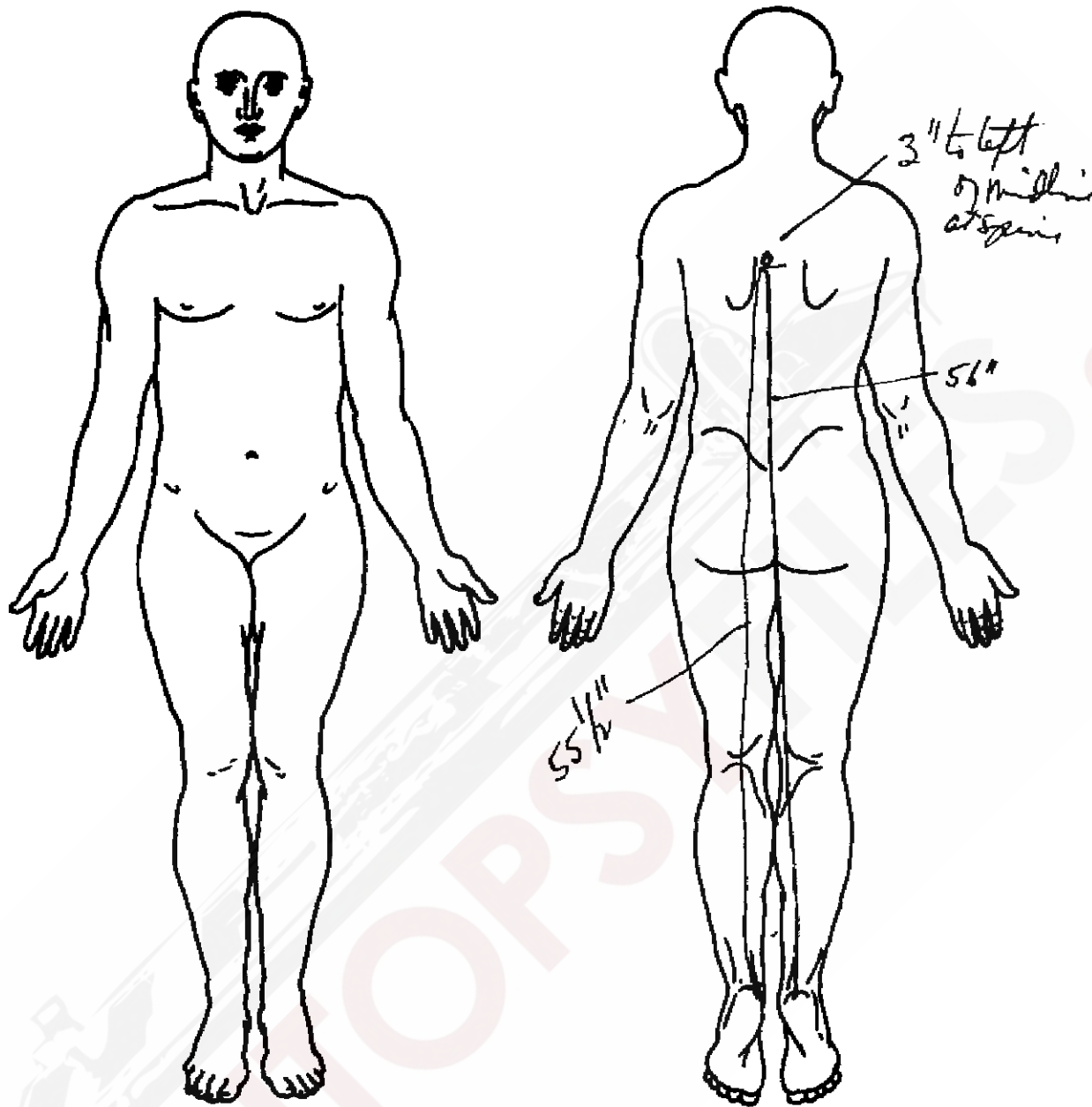
**ADRENALS:** The adrenals are in normal position and weigh 8 grams together. The cortex is bright yellow. The medulla is grey.

FORM #11

Special Chart 11

Autopsy No. \_\_\_\_\_

A68-252



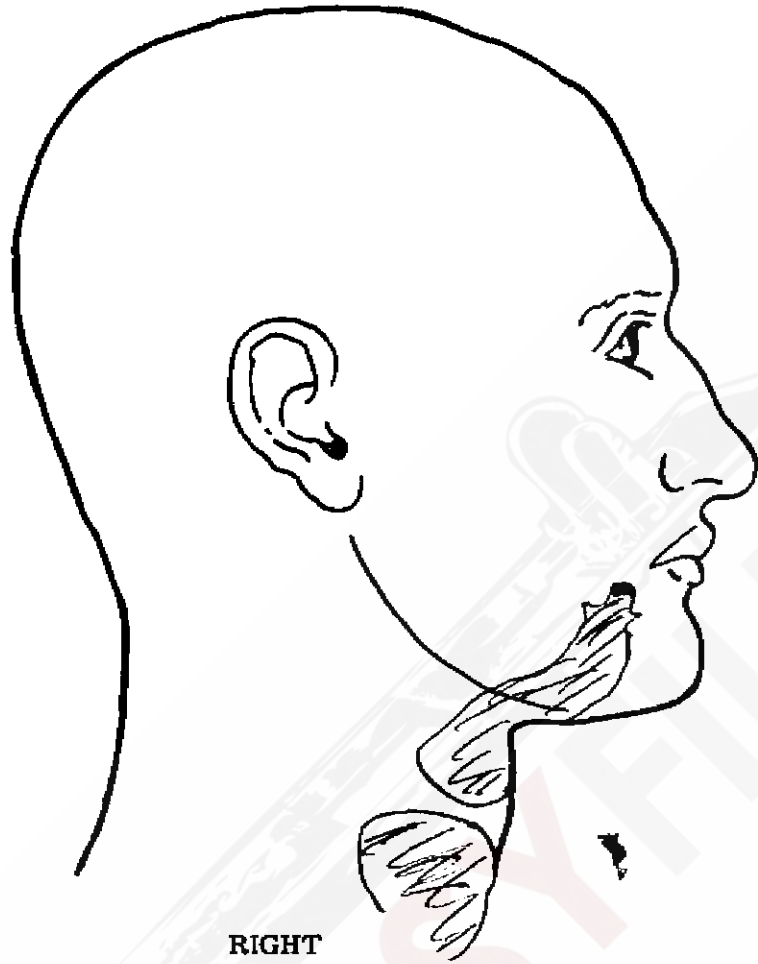
FORM NO. 48

RIGHT HEAD

Special Chart 14

Autopsy No. \_\_\_\_\_

A68-252



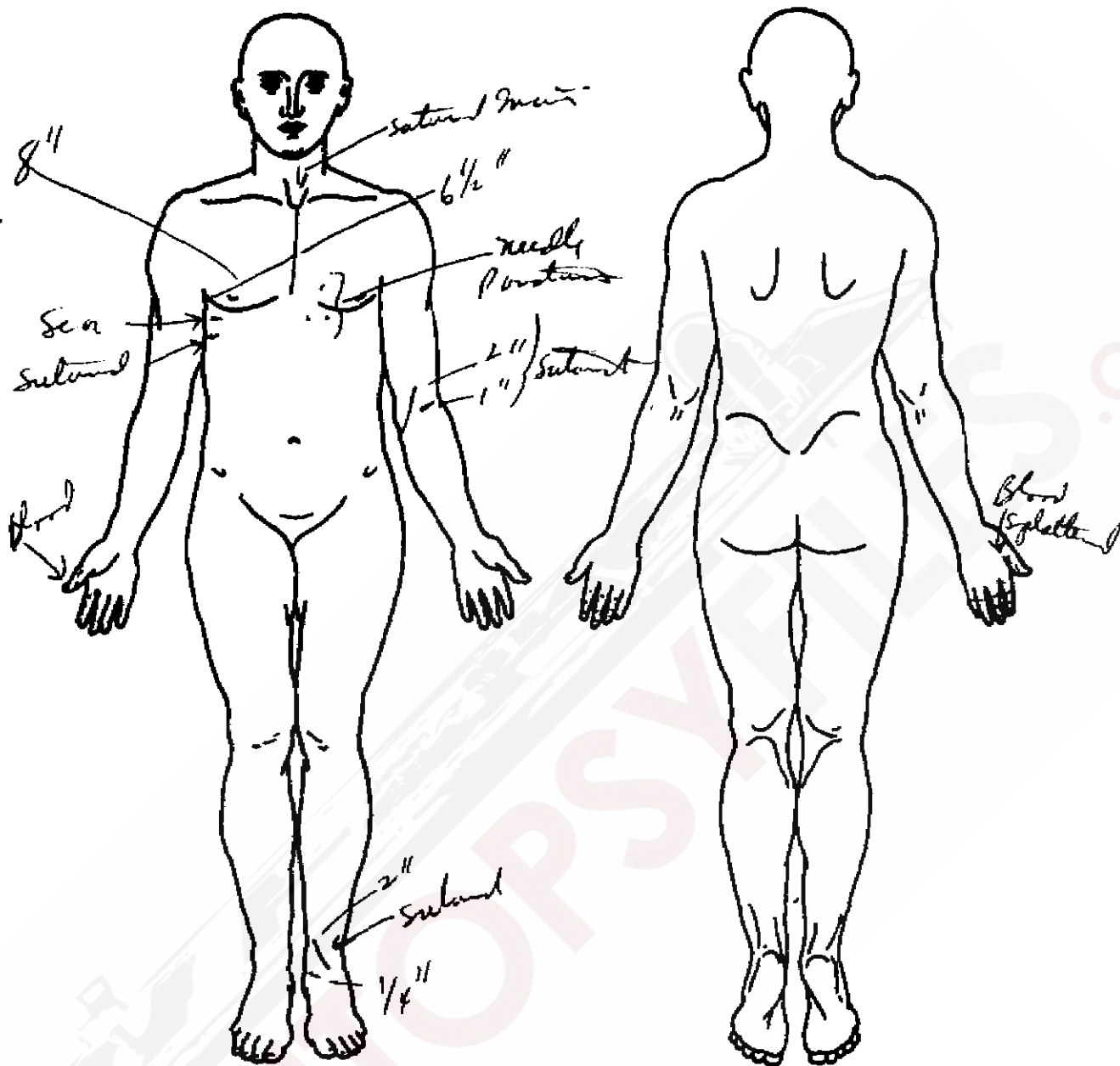
AUTOPSYFILES.ORG

FORM 5711

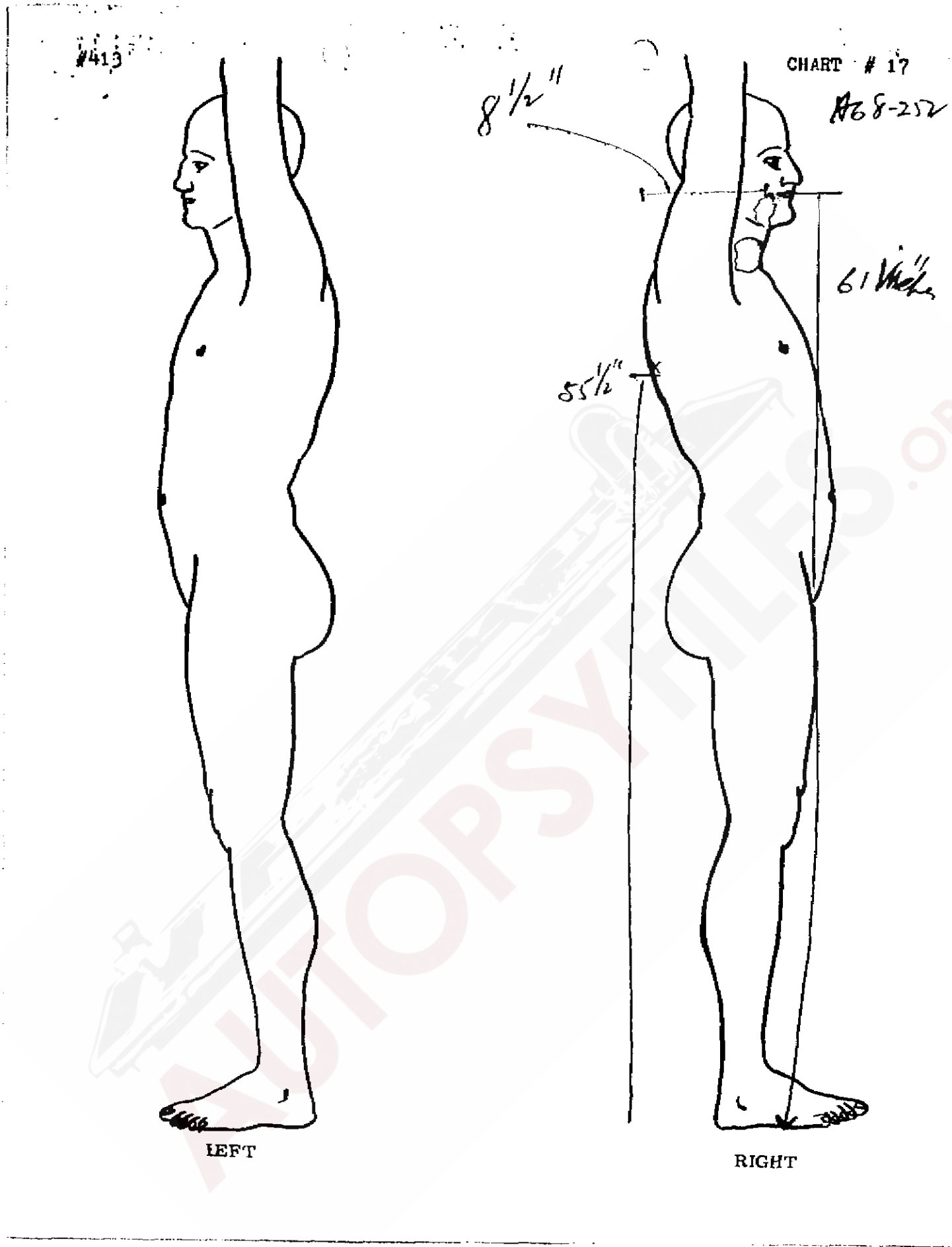
Special Chart II

Autopsy No. \_\_\_\_\_

A68-252







A68-252

MICROSCOPIC SUMMARY

- LUNG:** Focal areas of intra-alveolar hemorrhage are present throughout. Otherwise the alveoli are well preserved without hyperdistention or collapse. There is a loss of bronchial epithelium free within the lumens of the bronchioles. The pulmonary vessels reveal no significant changes.
- PANCREAS:** The pancreatic parenchyma is well preserved. The islets and acini are well preserved. There is minimal congestion present but no fibrosis or hemorrhage.
- KIDNEY:** The glomeruli and tubules are well preserved. There is no parenchymal fibrosis evident or vascular proliferation present. The tubules are filled with eosinophilic material. There is no collapse of the tubular lumen.
- THYROID:** The follicles are uniform and regular. There is a small quantity of extravasation of mature erythrocytes into peri-follicular locations. Cellular inflammatory reaction is not present. There is no margination of polymorphonuclear leucocytes within the areas of hemorrhage.
- LIVER:** There is diffuse cytoplasmic vacuolation throughout the hepatic cytoplasm being distributed throughout the lobules and in both pericentral and periportal locations. A small number of mononuclear cells are present in portal areas. There is some variation in size, shape of the hepatic nuclei. The vacuoles that are present are irregular in size, being numerous in some cells and being single large vacuoles in others with a disruption of cytoplasmic borders in some.
- ADRENAL:** There is congestion of the inner cortical zones of the adrenal. The cytoplasm is otherwise well maintained. The cortico-medullary ratio is maintained.
- SPLEEN:** The follicles are present but without secondary reactive centers. There is some congestion of the pulp but focal hemorrhage is not present.
- HEART:** The myocardial fibers are well preserved. The nuclei are regular. Fibrosis is not present throughout the myocardium and cellular inflammatory reaction is not present. The atrium reveals no significant changes.
- SKIN:** There is dermal hemorrhage present but no accumulation of polymorphonuclear leucocytes. Blackened debris is present throughout the hemorrhagic area of the dermis having no identifiable form. There is pronounced eosinophilia of the collagen bundles. There is hemorrhage into the dermal layers with an alteration in the tinctorial properties of the epithelium with focal fragmentation of the epithelium adjacent to the area of dermal hemorrhage.

Continued.....

A68-252 Continued..... Page 2.  
MICROSCOPIC SUMMARY

**CORONARY:**

There is moderate intimal proliferation along with an extra cellular deposition of lipid within the sub-intimal areas along with lipid filled macrophages present in this location. Small foci of perivascular mononuclear cells are present in the regions of most pronounced intimal proliferation.

**PROSTATE:**

The glandular elements are well preserved without any significant increase in collagenous connective tissue. Inflammatory reaction is not present.



BILL OF COST

5-2-68  
DATE

Charges for autopsy performed on the body of

Martin L. King  
Name of Decedent

4-5-68  
Date of Autopsy

by order of the District Attorney General, Shelby County, Tennessee  
under provisions of Tennessee Code Annotated, 38-706.

  
J. A. Francisco, M.D.  
Physician Performing Autopsy

AUTOPSYFILES.ORG