

Division of Medical Examiner
 175 South Lena Road
 San Bernardino, CA 92415-0037
 (909) 387-2542
 Fax (909) 387-2989



Frank Sheridan, M.D.
 Chief Medical Examiner

_____, M.D., Deputy M.E.

**San Bernardino County Sheriff's Department
 Coroner Division**

Autopsy Protocol

Coroner's Case Number: 701204304

Autopsy Number: A-0761-12

Name:	Rodney Glenn King	Age: 47	Sex: Male
Time of Death:	Reported 0611 hours, June 17, 2012		Race: Black
Time of Autopsy:	1000 hours, June 18, 2012		
Place of Autopsy:	San Bernardino County Coroner's Facility		Deputy: Lay

HISTORY OF DEATH: The history as obtained by the deputy coroner investigating officer is to the effect that the subject's girlfriend awoke at about 0526 hours on June 17, 2012 to hear the subject screaming "Baby, come and help me!" at the rear patio sliding door. The girlfriend found the subject in the bushes next to the sliding glass door with his underwear down to his knees. She went into the residence to find her cell phone and then went back outside to the backyard where she saw the subject face down at the deep end of the pool. The subject was naked. The girlfriend called 911. The call was received at 0526 hours on June 17, 2012. Officers arrived on the scene at about 0529 hours, jumped into the pool and pulled the subject out. The subject was unresponsive. CPR was initiated by members of the Rialto Fire Department and ACLS measures were also initiated. The subject was transported to Arrowhead Regional Medical Center (ARMC), arriving at 0605 hours. Resuscitative measures were to no avail and he was pronounced dead at 0611 hours.

According to the fire department run sheet, the subject was in asystole when removed from the swimming pool and was still in asystole on arrival at the hospital.

The deputy coroner investigating officer examined the body at the hospital at 0720 hours on June 17, 2012. Examination revealed a number of cutaneous injuries on the torso and upper and lower extremities. The injuries were primarily contusions and abrasions, at least some of which appeared old. In addition, multiple old scars were noted on the arms and legs. There was also an approximately 1 inch long fresh cut in the skin of the left thumb. There were no apparent fractures and there was also no evidence of injury to the mouth. No ocular petechiae were noted but there was bilateral conjunctival congestion. There was some bloody discharge from the right naris. The body was generally cool to the touch but the lower abdomen felt warm. Rigor mortis and lividity were not present.

The deputy coroner investigating officer also went to the scene. A number of empty beer bottles, as well as a partly empty bottle of gin and an empty champagne bottle were found in the kitchen. No illicit drug paraphernalia was found.

Off of the kitchen was a small covered patio with a concrete floor. There were some blood droplets on the patio floor and on the south side of the patio there was a broken wooden rectangular table with blood on it. On the outside of the patio sliding glass door were numerous smear marks and a shovel propped against the door. To the east of this was a flat planter with green plant covering. The plant covering had been smashed. South of the planter was a pair of

KING AUTOPSY CONTINUED
PAGE 2
A-0761-12

light blue boxer-style undershorts.

Near the southeast end of the patio was an oval-shaped pool. The water was semi-clear as if the pool had not been well maintained. A pitchfork and a hoe were seen at the bottom of the deep end along with a vacuum pool sweeper. The subject's girlfriend stated that she had used these to try and arouse the subject in the pool as she was not a good swimmer and was afraid to enter the water.

According to the subject's girlfriend, the subject had been drinking throughout the previous day and into the night with a male friend. They also smoked marijuana. The girlfriend stated that she drank with them for some time but did not smoke any marijuana. According to the girlfriend, there were no problems during the time they were drinking and smoking the marijuana. At about midnight the subject and his girlfriend took the male friend home. According to the girlfriend, the subject was heavily intoxicated so she drove the car. After they returned to the residence, the girlfriend did some laundry and the subject continued drinking. At some point the subject apparently cut his thumb.

At about 0245 hours on the morning of April 17, 2012 the girlfriend went to bed but the subject stayed up. At about 0526 hours the girlfriend woke to hear the subject pounding on the closed rear patio sliding glass door. She described him making grunting and growling sounds and having frothy secretions coming from his mouth. The subject at that time was wearing his underwear down around his knees and then apparently fell backwards onto the planter on the patio covering just east of the patio sliding glass door. When the girlfriend went back into the residence to get her cell phone, she heard a splash in the pool and went out to the backyard to find the subject face down on the bottom of the deep end of the pool. The girlfriend was not a good swimmer so she used a pitchfork and a hoe from the backyard to try to jab at the subject to arouse him.

The subject did not have a private medical physician and was not on any prescription medications. He did, however, smoke marijuana, reportedly medicinal. There was a past history of drug and alcohol abuse, as well as a history of involvement with law enforcement on a number of occasions, most notably in 1991 when the subject was involved in a highly publicized police beating incident. According to family members, however, the subject had been doing well for some time and was adjusting his life. He had recently been on a number of tours promoting a book. According to the subject's brother, the subject had no history of cardiovascular disease, cancer or seizures. He was fond of skateboarding and, according to the brother, some of the old abrasions on his body were probably related to falls while skateboarding.

There was reportedly no recent use of illicit drugs, other than marijuana and, according to the subject's girlfriend there was no recent domestic violence. According to the deputy coroner, the subject's girlfriend, when interviewed, appeared distraught and possibly intoxicated. The deputy coroner did not see any obvious signs of injury on her body and scene investigation showed no indication that a struggle had taken place in the residence.

In April 2003 the subject crashed his car into a house and was admitted to ARMC. The medical records from this admission list diagnoses of facial injuries and concussion, as well as a right sternoclavicular dislocation and sacral fracture. There was no intracranial trauma. He was hospitalized for three days and then discharged home.

On November 29, 2007 the subject was shot with a shotgun while riding his bicycle and was treated at ARMC. The medical records indicate that the subject sustained several pellet injuries involving the face, neck, chest and abdomen. Diagnostic studies were done and the subject was

KING AUTOPSY CONTINUED
PAGE 3
A-0761-12

observed overnight in hospital. The records indicate additional diagnoses of alcohol intoxication and polysubstance abuse.

Also refer to Coroner's Investigative Report 701204304.

EXTERNAL EXAMINATION: The body is that of an apparently normally developed, well-nourished, muscular Black male appearing about the stated age of 47 years. The body is not embalmed but is well preserved following refrigeration. The weight is 235 pound, the height 74 inches. The hair is dark brown, eyes brown, the complexion medium to dark brown.

Therapeutic appliances present include an endotracheal tube in the mouth, a nasogastric tube in the left naris, a vascular line in the left antecubital fossa, and ECG pads on the right side of the abdomen.

There is a hospital identification tag on the right ankle and a toe tag on the right big toe.

The following is a general description. Injuries, recent and old, present on the body will be described below separately.

The head is normocephalic and symmetrical. There is moderately advanced male pattern balding. The hair on the top and back of the scalp is dark brown, curly and of medium length. The corneae are slightly cloudy. There is bilateral conjunctival congestion, more prominent on the right than the left. There is one petechial hemorrhage in the left lower eyelid. There is also slight scleral hemorrhage on the medial aspect of the right eye. There are no facial petechiae. Blood is present in the nares. The teeth are natural and in good state of repair. There is no evidence of trauma to the lips, alveolar ridges, teeth or tongue. A moustache and goatee beard are present. There is also several days' growth of hair in the remainder of the beard area.

The neck, chest and abdomen are normally formed. The abdomen is soft to palpation. The pubic hair is of normal adult male distribution. The penis and scrotum appear anatomically normal and without evidence of injury or other abnormality.

The upper extremities are normally formed. The fingernails are short with no evidence of nail breakage. (Nail clippings and hair samples are taken into evidence). On the posterolateral aspect of the mid right upper arm there is a very faint unreadable tattoo consisting apparently of a single word. Fingerprint ink is present on the hands. No old needle tracks are identified in the skin of the upper extremities.

The lower extremities are normally formed. The toe nails are short, somewhat roughened in appearance, especially the nail of the left big toe.

There is moderate posterior lividity.

INJURIES:

The injuries described below are depicted in the accompanying diagrams (A through C).

Head & Neck:

There are three old curvilinear scars in the skin of the face. The uppermost of these is just in front of the hairline in the left upper frontal area. This scar is 3 cm in length. The second scar is about 3.5 cm inferior to the above-mentioned scar, situated about 2.5 cm above the left supraorbital

KING AUTOPSY CONTINUED
PAGE 4
A-0761-12

ridge. This scar measures about 2 cm in length. The third scar is situated on the lateral aspect of the right upper eyelid. This scar measures about 1 cm in length and the skin is slightly indented. There is no evidence of fresh trauma to the scalp, face, or neck.

Anterior Torso:

Injuries on the anterior chest and abdomen include the following:

A horizontally oriented, depigmented, 1.5 cm long scar to the right of the midline at the level of the xiphoid process.

An approximately 3 mm diameter circular red punctate abrasion in the right anterior mid axillary line at a level of about 9 cm below the right nipple.

A faint equivocal area of linear scarring at the right costal margin measuring about 3 cm in length.

An almost horizontally oriented curvilinear scar crossing the umbilicus with a total length of about 7 cm.

Right Upper Extremity:

There are old and a few recent cutaneous injuries on the right upper extremity. These include:

On the medial aspect of the distal right upper arm just above the elbow joint an approximately circular 7 mm diameter reddish-purple ecchymosis.

On the anteromedial aspect of the right proximal forearm a curvilinear, partially interrupted healing abrasion about 7 cm in length.

On the posteromedial aspect of the right forearm just below the elbow a 5 mm diameter healing abrasion.

There is a horizontally oriented, slightly irregular but generally curvilinear well healed scar with healed suture marks on the anterior aspect of the mid forearm. This measures about 7.5 cm in length.

There are multiple linear, curvilinear and slightly irregularly-shaped healed old scars on the posterior aspect of the right distal upper arm, elbow and forearm. Most of these scars are somewhat ill-defined. They vary in length from about 6 cm to about 1.5 cm. These scars mostly show some degree of hypopigmentation.

On the dorsum of the right hand there are four approximately circular healing abrasions on the skin of the third, fourth and fifth metacarpophalangeal joints. There is an additional smaller, possibly healing, abrasion also over the fourth metacarpophalangeal joint.

There are no fractures of the right upper extremity.

KING AUTOPSY CONTINUED

PAGE 5

A-0761-12

Left Upper Extremity:

Injuries on the left upper extremity including the following:

A 1 cm long well healed vertical scar on the medial aspect of the left elbow.

A 3.5 cm long curvilinear scar on the anterior aspect of the proximal left forearm.

Three small punctate-like healing abrasions on the anterior aspect of the left wrist.

An approximately 1 cm diameter round to oval fresh abrasion on the back of the left elbow just below the bony prominence of the elbow.

An approximately triangular-shaped fresh red abrasion on the dorsoulnar side of the proximal left forearm. This measures about 3.5 cm vertically by, on average, about 2.5 cm horizontally.

Immediately distal to the above injuries is a cluster of small healed scars, some linear, some oval-shaped, spanning an area of about 6 cm vertically by 3 cm horizontally.

There is a hyperpigmented healed apparent skin graft on the back of the left hand, involving the dorsal aspect of the index finger, the proximal portion of the dorsal aspect of the third finger, and the metacarpophalangeal area of both of these fingers.

There are recent, possibly fresh, small abrasions on the ulnar side of the index, third and fifth fingers of the left hand over the proximal interphalangeal joints.

On the dorsal aspect of the left thumb over the interphalangeal joint is an approximately 1.5 cm long linear fresh sharp force injury. The injury is superficial, going primarily through the epidermis.

There are no fractures of the left upper extremity.

Left Lower Extremity:

Cutaneous injuries on the left lower extremity include the following:

On the anterolateral aspect of the proximal left thigh there is a vertically oriented rectangular area of hyperpigmentation measuring about 15.5 cm vertically by about 8 cm horizontally with a small medially pointing extension on the upper end about 1 cm x 1 cm. The edges are well defined and the lesion is consistent with a healed skin graft donor site.

On the anterior aspect of the upper left thigh an obliquely oriented well healed scar about 2 cm in length.

A 2.5 cm x 5 mm healed scar on the anteromedial aspect of the distal left thigh just above the knee.

Over the left patella an approximately curvilinear, partially interrupted healing abrasion about 4 cm in length.

KING AUTOPSY CONTINUED

PAGE 6

A-0761-12

On the front of the left shin and dorsum of the left foot there are some small irregular areas of hyperpigmentation and possibly small nondescript faint scars.

On the posteromedial aspect of the left thigh, at about the junction of the upper and middle thirds, is an approximately 2 to 2.5 cm circular fresh contusion. Incision of this lesion shows fresh underlying hemorrhage.

Right Lower Extremity:

There are some very faint equivocal linear healed scars on the lateral aspect of the proximal right thigh.

On the anterior aspect of the right knee is an area of slightly puckered irregular faint scarring measuring up to about 5 cm in length.

On the medial aspect of the right patella are two healing abrasions, one measuring about 1 cm x 3 mm, another measuring 2 cm x 1 cm, the third measuring about 1 cm x 1 cm.

There are scattered areas of hyperpigmentation and one or two equivocal healed scars on the front of the right shin.

On the medial aspect of the metacarpophalangeal joint of the right big toe are three superficial, red, small abrasions forming a cluster of about 1.5 cm x 5 mm in diameter. There is also a very small superficial abrasion about 2 mm in diameter on the mid dorsum of the right foot.

On the dorsal aspect of the right distal calf are two clusters of healing abrasions, each consisting of at least four vertically oriented, partially interrupted abrasions. Each of these two areas has a somewhat irregular pattern, suggestive of contact with a patterned surface or object.

Posterior Torso:

There are multiple fresh abrasions in the skin of the posterior torso. These include an approximately 5 cm x 1 cm horizontally oriented linear abrasion on the dorsal aspect of the left shoulder. Close to this are multiple fainter, partially interrupted linear and curvilinear abrasions spanning an area over the left scapula about 8 cm x 8 cm. There are also some additional scattered abrasions on the posterolateral aspect of the ribcage on the left side, and another area of abrasions with some associated contusion on the right side of the lower chest area. These latter injuries span an area of about 21 cm vertically by about 3 cm horizontally.

On the right upper posterior torso in the upper scapular area is a somewhat irregularly-shaped 4 cm x 3 cm fresh ecchymosis. Incision of this lesion shows fresh underlying hemorrhage. Over the lower left posterior chest are several areas of hyperpigmentation of the skin of various sizes, ranging up to about 1.5 cm in diameter. Incision of these lesions shows no underlying subcutaneous hemorrhage.

KING AUTOPSY CONTINUED
PAGE 7
A-0761-12

X-RAYS: Total body x-rays are taken prior to autopsy.

X-rays of the head show several small pellets consistent with birdshot pellets. One of these is situated in the scalp in the midline frontal area with another in the scalp in the left frontal area. There is one pellet on the left side of the face, one on the right side of the face, and one at the chin. All of the pellets appear to be in the subcutaneous and/or muscle tissue. No recent fractures are identified. There is no obvious opacification of the cranial air sinuses.

X-rays of the chest, abdomen and pelvis show several birdshot pellets (approximately twenty). These are situated mostly in the lower left abdominal and pelvic area, including around the left hip.

There are multiple birdshot pellets in the x-ray of the right upper extremity. One of these is situated in the musculature of the upper part of the right arm. Three are situated just above the elbow joint, nine in the forearm, four in the wrist, and four in the hand. Most, if not all, of these pellets appear to be in the soft tissues. There are no right upper extremity fractures.

X-rays of the left upper extremity show multiple birdshot pellets. Four of these are in the left shoulder area, five in the left deltoid area, four in the distal half of the left upper arm, two in the elbow area, and four in the left forearm. Most, if not all, of these pellets appear to be in the soft tissues. There are no recent fractures.

An x-ray of the left lower extremity shows four pellets in the left thigh and one in the lower leg. Most, if not all, of these pellets appear to be in the soft tissues. No fractures are identified.

An x-ray of the right lower extremity shows no pellets or other unusual features.

No fractures are identified in any of the x-rays described above. There is no evidence of skeletal disease or deformity.

INTERNAL EXAMINATION:

CHEST & ABDOMEN: There is some blue suture material in the subcutaneous tissue at the umbilicus subjacent to the scar described on external examination. The subcutaneous fat of the abdominal wall is up to about 4 cm thick. There is no evidence of blunt force or penetrating trauma to the chest or abdominal wall. The clavicles, sternum and ribs are intact. The thoracic and lumbar vertebral column and pelvis are intact. The pleural, pericardial and peritoneal membranes are smooth and glistening, and there is no abnormal fluid accumulation in any of the body cavities.

CARDIOVASCULAR SYSTEM: The heart is 480 grams (expected weight for height: 355 +/- 40 grams). The epicardial and endocardial surfaces are smooth and glistening and the valves are all normal. The myocardium on section is uniformly firm and red-brown with no focal lesions. There is concentric left ventricular hypertrophy. There are no mural thrombi in any of the cardiac chambers. The blood in the heart and great vessels is liquid and appears slightly diluted. The coronary arteries on section show a normal anatomic distribution and show no evidence of atherosclerosis or other abnormalities. The aorta and great veins of the chest and abdomen are anatomically normal with no evidence of trauma or disease. There is no evidence of pulmonary thromboembolism.

KING AUTOPSY CONTINUED

PAGE 8

A-0761-12

RESPIRATORY TRACT: The tracheobronchial tree is intact, the tip of the endotracheal tube in the trachea with the cuff inflated. There is no blood or other foreign material in the airway. The right lung is 765 grams, the left 655 grams. The lungs are normally formed. The cut surfaces show severe generalized vascular congestion but no evidence of consolidation or other focal lesions.

GASTROINTESTINAL TRACT: The tongue, oropharynx, esophagus, stomach, small intestine, large intestine and appendix are all normally formed and show no evidence of trauma or disease. The stomach contains about 250 ccs of opaque greenish-brown fluid with some unrecognizable suspended small food particles. The tip of the nasogastric tube is in the stomach cavity. No obvious tablet fragments are identified. There is no evidence of hemorrhage or other abnormality throughout the lumen of the gastrointestinal tract.

PANCREAS: The pancreas is of normal size and shape and shows no unusual features, apart from early autolysis.

HEPATOBIILIARY SYSTEM: The liver is 2015 grams. The capsule is intact. The parenchyma is uniformly firm and red-brown. There is no evidence of cirrhosis. No trauma or other focal lesions are identified. The gallbladder is normal.

GENITOURINARY TRACT: The right kidney is 160 grams, the left 165 grams. The cortical surfaces are smooth and the cut surfaces show normal corticomedullary demarcation with no focal lesions. The pelves and ureters are normal. The bladder contains about 100 ccs of clear urine. The prostate is of normal size, shape and consistency and shows no unusual features, externally or on section. The testes are anatomically normal, without evidence of trauma.

LYMPHOID SYSTEM: The spleen is 85 grams. The capsule is intact. The parenchyma is purple-tan with the normal follicular pattern. Lymph nodes throughout the body are small and inconspicuous. No thymic tissue is identified.

ENDOCRINE SYSTEM: The pituitary, thyroid and adrenals are grossly normal, externally and on section.

NECK: There is no soft tissue hemorrhage in the subcutaneous tissue, musculature, deep connective tissue or other structures in the neck. The hyoid bone and laryngeal cartilages are intact. The cervical spine is intact.

HEAD: There is no scalp hemorrhage. In the midline frontal area of the scalp a small gray lead metallic, slightly deformed, shotgun pellet is embedded in the periosteum of the skull. The pellet measures about 2 mm in diameter. There is no other evidence of pellet injury to the skull. There are no skull fractures. The dura is normal with no associated hemorrhage. The arachnoid is thin and transparent, and the CSF is clear. The brain is 1390 grams. The brain, immediately after removal, is x-rayed. No pellets are noted in the x-ray. The cerebral hemispheres are symmetrical and show a normal anatomic pattern of major fissures, sulci and gyri. There is no external evidence of trauma, edema or herniation, and the circle of Willis is intact with no evidence of vascular disease. The brainstem and cerebellum appear grossly normal. The brain is partially sectioned and shows no unusual features. The brain is then fixed in formalin for later complete examination.

The brain is examined again after fixation in formalin. The cerebrum, brainstem and cerebellum show normal anatomic features externally and on section with no evidence of trauma or other unusual features.

KING AUTOPSY CONTINUED
PAGE 9
A-0761-12

MICROSCOPIC EXAMINATION:

Cassette 1 – interventricular septum and left coronary artery:

Cassette 2 – left ventricular free wall:

Cassette 3 – right ventricle and right coronary artery:

The sections of the left ventricle show moderate myocyte nuclear pleomorphism and hyperchromatism and multifocal areas of perivascular fibrosis. There is no evidence of acute infarction or of myocarditis. The section of interventricular septum shows no evidence of myofiber disarray. The epicardial and endocardial surfaces in all sections are normal. A section of right ventricle shows normal epicardium, endocardium and myocardium. Multiple sections of the coronary arteries show no evidence of atherosclerosis, vasculitis or other abnormalities. An occasional intramyocardial arteriole shows evidence of mild intimal hypertrophy.

Cassettes 4, 5, 6 – lungs:

All of the lung sections show generalized vascular congestion with scattered areas of intra-alveolar hemorrhage. There is no evidence of interstitial pneumonitis or broncho-pneumonia. The mucosal linings of the bronchi are mostly autolyzed but the bronchial submucosa appears normal with no evidence of asthma or other inflammatory disease. The intrapulmonary vessels and hilar lymph nodes appear normal. There is a moderate amount of anthracotic pigment in all of the lung sections. Examination of the lungs under polarized light reveals no birefringent material in the pulmonary interstitium.

Cassette 7 – pancreas, liver:

A section of pancreas shows moderate autolysis but no evidence of pancreatitis or other abnormality. A section of liver shows normal histological lobular architecture. There is no evidence of steatosis, hepatitis or cirrhosis.

Cassette 8 – kidneys:

Sections of both kidneys show normal histological architecture throughout the cortices and medullae. The glomeruli, including the afferent and efferent arterioles, appear normal.

Cassette 9 – prostate and testis:

Sections of prostate and testis are normal.

Cassette 10 – spleen:

A section of spleen shows a normal distribution of lymphoid follicles and red pulp.

Cassette 11 – adrenals:

Sections of both adrenals are normal.

Cassette 12 – pituitary and thyroid:

Sections of pituitary and thyroid are normal.

KING AUTOPSY CONTINUED
PAGE 10
A-0761-12

Brain Sections:

Cassette 13 – frontal lobe:
Cassette 14 – temporal lobe:
Cassette 15 – right hippocampus:
Cassette 16 – left hippocampus:
Cassette 17 – parietal lobe:
Cassette 18 – basal ganglia and internal capsule:
Cassette 19 – occipital lobe:
Cassette 20 – cerebellum:
Cassette 21 – midbrain:
Cassette 22 – pons:
Cassette 23 – medulla:

Microscopic examination of all of the above sections shows normal histological architecture throughout the cerebrum, brainstem and cerebellum. There is no evidence of inflammation, hemorrhage, neoplasm, degenerative disease or vascular disease in any of these sections.

KING AUTOPSY CONTINUED

PAGE 11
A-0761-12

- DIAGNOSIS:**
- I. 47-year-old male found at bottom of swimming pool at residence. Pronounced dead in the emergency room.
 - A. Drowning
 1. History consistent with drowning.
 2. Heavy congested lungs.
 - B. Injuries
 1. Multiple fresh cutaneous abrasions and occasional contusions, consistent with history of falling and/or being retrieved from the swimming pool.
 2. Fresh superficial sharp force injury of right thumb.
 3. Multiple healing superficial cutaneous injuries.
 4. Multiple old cutaneous scars on face, upper extremities, lower extremities, and torso.
 5. Multiple old shotgun pellets (birdshot) in head, torso, left and right upper extremities, and left lower extremity.
 - a) No evidence of complications from above.
 6. No fresh/recent internal trauma of head, neck, chest, abdomen or pelvis.
 - C. Drug and alcohol abuse.
 1. Past history of polysubstance abuse.
 2. Toxicological examination (subclavian blood, femoral blood, urine) positive for ethanol, cocaine metabolites, phencyclidine (PCP) and cannabinoids (see toxicology report).
 - D. Vitreous glucose, electrolytes, creatinine and VUN within normal limits.
 - E. Cardiomegaly with concentric left ventricular hypertrophy and multi-focal perivascular myocardial fibrosis.
 - F. Evidence of prior surgery:
 1. Surgical scar with old suture material, umbilical area.
 2. Apparent skin graft of left hand with graft donor site on left thigh.

CAUSE OF DEATH: Drowning, minutes.

Contributing Causes: 1) Combined ethanol and multiple drug toxicity. 2) Cardiomegaly with focal myocardial fibrosis.

Manner of Death: Accident

COMMENT: The police and coroner's division investigation, scene investigation, and autopsy findings indicate that the subject was in a state of drug and alcohol-induced delirium at the time of the terminal event and either fell or jumped into the swimming pool. The effects of the drugs and alcohol, combined with the subject's heart condition, probably precipitated a cardiac arrhythmia and the subject, thus incapacitated, was unable to save himself and drowned. The fresh cutaneous injuries found at autopsy are consistent with the history given by the subject's girlfriend relating to falling and also consistent with the subject drowning and/or being retrieved from the swimming pool. There is nothing in the history or autopsy examination to suggest suicide or homicide, and the manner of the death is therefore judged to be accident.

KING AUTOPSY CONTINUED
PAGE 12
A-0761-12

WITNESS PRESENT: Detective G. Marquez; Rialto Police Department.

Autopsy Completed 1345 hours, June 18, 2012.

Frank Sheridan MD
Frank Sheridan, M.D.
Pathologist

Date: 8/22/12

FS:pm

AUTOPSYFILES.ORG



County of San Diego

GLENN N. WAGNER, D.O.
CHIEF MEDICAL EXAMINER

JONATHAN R. LUCAS, M.D.
CHIEF DEPUTY MEDICAL EXAMINER

OFFICE OF THE MEDICAL EXAMINER
5570 OVERLAND AVE., Ste #101, SAN DIEGO, CALIFORNIA 92123-1206
TEL: (619) 694-2895 FAX: (619) 495-5956

SAN BERNARDINO COUNTY CORONER TOXICOLOGY REPORT

Name: **KING, Rodney Glenn**
SBCCO Number: **701204304**
Autopsy Number: **A0761-12 FS**
Date of Death: **06/17/2012**
Pathologist: **Frank Sheridan, M.D.**
Specimens Received: **Gastric, Liver, Right Femoral Blood, Right Subclavian Blood, Urine, Vitreous**
Date Specimens Received: **06/21/2012**

<u>Test Name (Method of Analysis)</u>	<u>Specimen Tested</u>	<u>Result</u>
<u>Alcohol Analysis (GC/FID-Headspace)</u>	Right Femoral Blood	
Alcohol (Ethanol)		0.06 % (w/v)
Acetone, Methanol, Isopropanol		Not Detected
<u>Alcohol Analysis (GC/FID-Headspace)</u>	Vitreous	
Alcohol (Ethanol)		0.08 % (w/v)
<u>Drugs of Abuse Screen (ELISA)</u>	Right Subclavian Blood	
Cocaine metabolites		Presumptive Positive
Amphetamines		Not Detected
Opiates		Not Detected
Benzodiazepines		Not Detected
Fentanyl		Not Detected
Cannabinoids		Presumptive Positive
<u>Base Screen (GC/MS)</u>	Right Femoral Blood	
Phencyclidine (PCP)		0.30 mg/L
Benzoyllecgonine		Detected
<u>Acid/Neutral Screen (HPLC/DAD)</u>	Right Femoral Blood	Not Detected
<u>Urine Screen (GC/MS)</u>	Urine	
Phencyclidine (PCP)		Detected
Cocaine		Detected
Benzoyllecgonine		Detected
Ecgonine methyl ester		Detected
Levamisole		Detected
Nicotine		Detected
Cotinine		Detected

Cocaine metabolites (GC/MS)

Cocaine
Benzoyllecgonine
Cocaethylene

Right Femoral Blood

Not Detected
0.12 mg/L
Not Detected

Cannabinoids (GC/MS)

Delta 9-THC
Delta 9-Carboxy THC

Right Femoral Blood

5.7 ng/mL
18 ng/mL

Vitreous Chem Panel (Cobas c111)

Glucose
Chloride
Creatinine
Potassium
Sodium
VUN

Vitreous

13 mg/dL
132 mmol/L
0.6 mg/dL
11.4 mmol/L
143 mmol/L
47 mg/dL


Synthetic Cannabinoids (Spice)

Right Femoral Blood


See attached report from NMS

End Results

Approved and Signed:
08/08/2012


Iain M. McIntyre, Ph.D.
Forensic Toxicology Laboratory Manager
(All Inquiries/Correspondence)

Reviewed:


Catherine E. Hamm
FTLS

**NMS Labs****CONFIDENTIAL**

3701 Welsh Road, PO Box 433A, Willow Grove, PA 19090-0437

Phone: (215) 657-4800 Fax: (215) 657-2972

e-mail: nms@nmslabs.com

Robert A. Middleberg, PhD, DABFT, DABCC-TC, Laboratory Director

Toxicology Report**Report Issued** 08/08/2012 15:02**To: 79C**

San Diego County Medical Examiner

Attn: Toxicology Laboratory

5570 Overland Ave - Ste 101

San Diego, CA 92123

Patient Name NP**Patient ID** B12-04304**Chain** 11423151**Age** Not Given**Gender** Not Given**Workorder** 12271368

Page 1 of 2

Positive Findings:

None Detected

See Detailed Findings section for additional information

Testing Requested:**Analysis Code****Description**

9560B

Synthetic Cannabinoids Screen, Blood (Forensic)

Specimens Received:

ID	Tube/Container	Volume/ Mass	Collection Date/Time	Matrix Source	Miscellaneous Information
001	Clear Vial	1.25 mL	Not Given	Femoral Blood	RT FEMORAL BLOOD

All sample volumes/weights are approximations.

Specimens received on 08/02/2012.



CONFIDENTIAL

Workorder 12271368
Chain 11423151
Patient ID B12-04304

Page 2 of 2

Detailed Findings:

Examination of the specimen(s) submitted did not reveal any positive findings of toxicological significance by procedures outlined in the accompanying Analysis Summary.

Unless alternate arrangements are made by you, the remainder of the submitted specimens will be discarded three (3) months from the date of this report; and generated data will be discarded five (5) years from the date the analyses were performed.

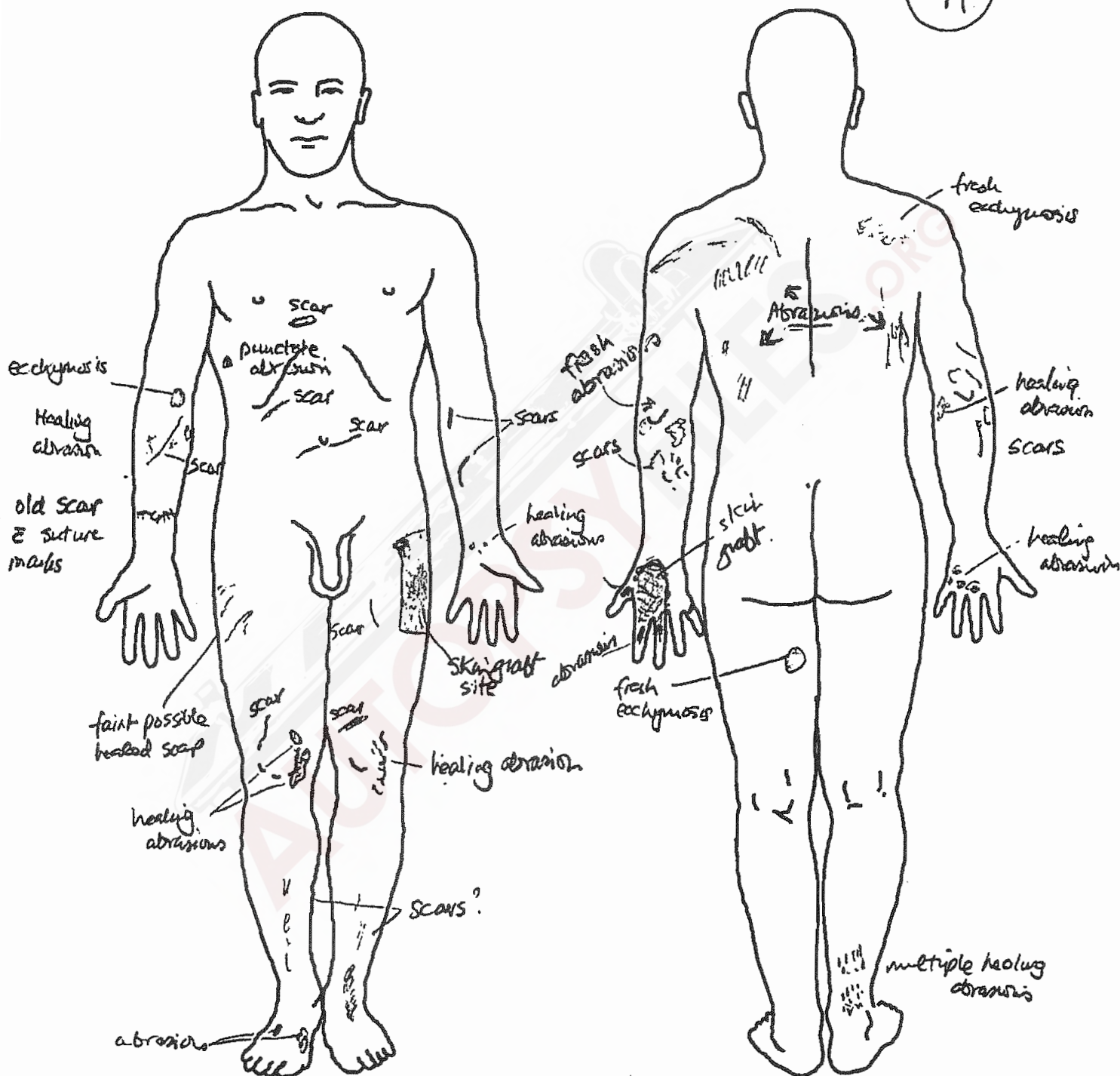
Analysis Summary and Reporting Limits:

Acode 9560B - Synthetic Cannabinoids Screen, Blood (Forensic) - Femoral Blood


-Analysis by High Performance Liquid Chromatography/Tandem Mass Spectrometry (LC-MS/MS) for:

<u>Compound</u>	<u>Rpt. Limit</u>	<u>Compound</u>	<u>Rpt. Limit</u>
AM-2201	0.10 ng/mL	JWH-122	0.10 ng/mL
AM-694	0.10 ng/mL	JWH-200	0.10 ng/mL
JWH-018	0.10 ng/mL	JWH-210	0.10 ng/mL
JWH-019	0.10 ng/mL	JWH-250	0.10 ng/mL
JWH-073	0.10 ng/mL	RCS-4	0.10 ng/mL
JWH-081	0.10 ng/mL	RCS-8	0.20 ng/mL

A



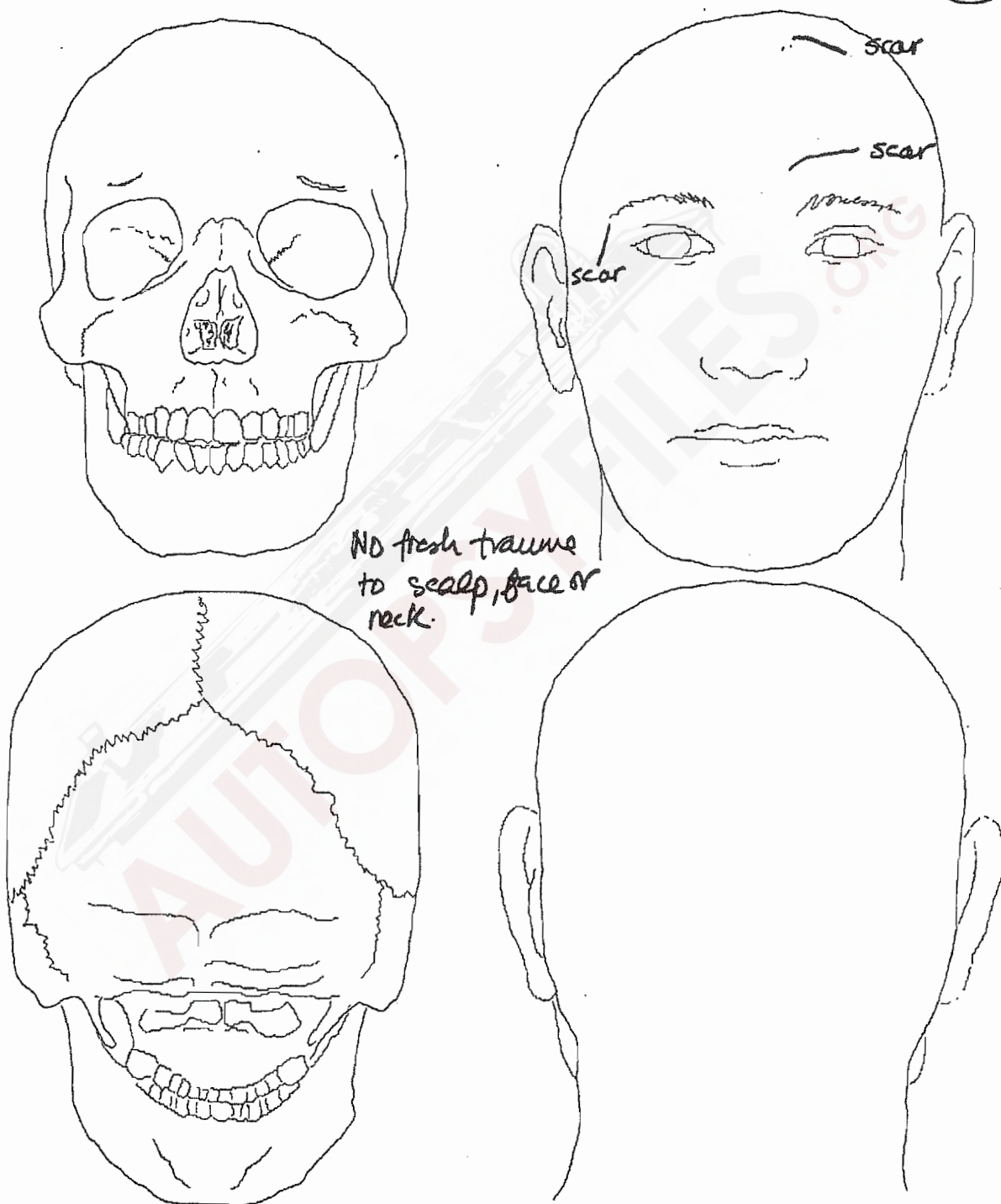
Name RODNEY KING Coroner's Case # 701204304 Autopsy No. A761-12A
Age 47 Race B Sex M Date 6/18/2012



San Bernardino County Coroner



(B)



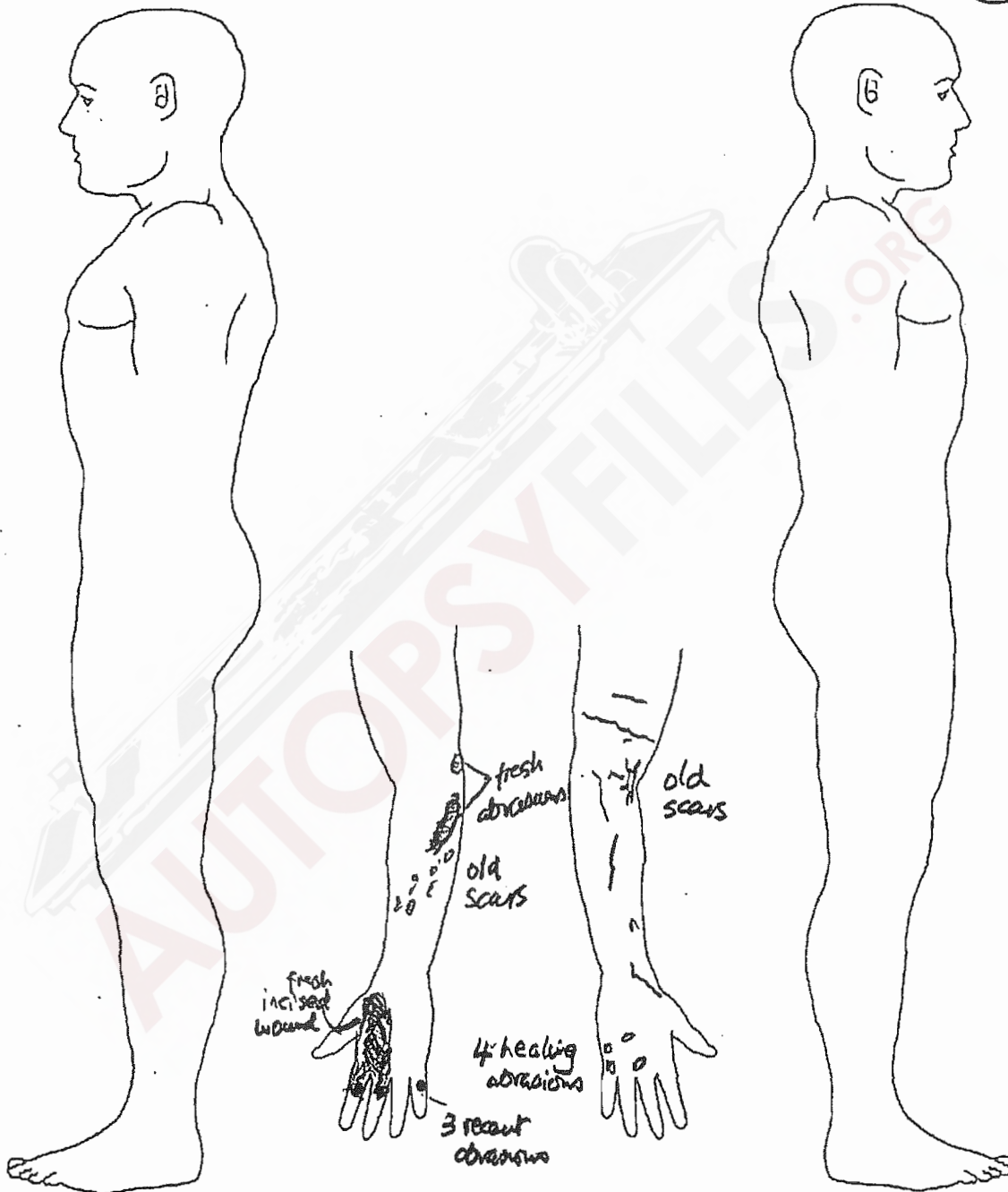
Head Surface & Skeletal Anatomy, Anterior & Posterior Views.

Name RODNEY KING Coroner's Case # 701204304 Autopsy No. AT61-12 PS
Age 47 Race B Sex M Date 6/18/2012 *[Signature]*

San Bernardino County Sheriff/Coroner



C



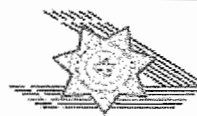
Full Body, Male, Lateral Views

Name RODNEY KING Coroner's Case # 701204304 Autopsy No. A761-12 PS
Age 47 Race B Sex M Date 6/18/2012

RS

San Bernardino County Sheriff - Coroner Division

Coroner Investigation

1	MODE Accident	CASE # 701204304	
	STATUS Post	DEPUTY Teri Lay	

CASE INFO

REPORTED BY RN Corina Lightner	AGENCY Arrowhead Regional Medical Center (ARMC)	DATE 06-17-12	TIME 0646
NEWS RELEASE NAME RELEASABLE ****	ROLL-OUT? Yes	# OF PHOTOS ****	MEDIUM ****
SPECIAL CIRCUMSTANCES			

DECEDENT INFO

1 NAME (FIRST) Rodney	2 (MIDDLE) Glenn	3 (LAST) King
AKA	DOE TYPE/NUMBER	PHONE ****
20 ADDRESS ****	21 CITY Rialto	25 STATE CA
23 ZIP 92376		
6 SEX Male	14 RACE Black	4 DOB 04-02-1965
5 AGE 47 yrs	RELATED CASE NUMBERS N/A	
BODY BAG # 4685500	TOE TAG 29617	10 SS# ****
HEIGHT 74.0 in	WEIGHT 235.0 lbs	HAIR Brown
EYES Brown		
DRIVER'S LIC. # ****	STATE CA	HOW IDENTIFIED Family present and Cal Id #360634752

LEGAL NEXT OF KIN

NAME Lora Dene King	RELATIONSHIP Daughter	MOTHER'S DOB/AGE	DATE/TIME NOTIFIED 06-17-12 0700	NOTIFIED BY Numerous family members by Ontres cia
ADDRESS ****	21 CITY Fontana	25 STATE CA	23 ZIP 92336	
PHONE ****	ALTERNATE PHONE # ****			

PLACE/DEATH OCCURRED

7 DATE 06-17-12	8 TIME 0611	DAY OF DEATH Sunday	PRONOUNCED BY Dr. Yuen
101 PLACE OF DEATH Arrowhead Regional Medical Center (ARMC)		102 IP-ER/OP-DOA ER/Outpatient	FAC OTHER THAN HOSPITAL
105 FACILITY ADDRESS OR LOCATION WHERE FOUND 400 N. Pepper Ave.			106 CITY Colton

INVESTIGATIVE SUMMARY

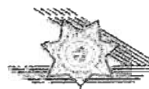
ADDITIONAL NARRATIVE ATTACHED ☒ YES ☐ NO

On 06/17/2012 at 0630 hours, I received notification from our Computer Aided Dispatch (CAD) and Deputy Coroner Investigator D. VanNorman that RN C. Lightner of the Arrowhead Regional Medical Center (ARMC) had called to report the emergency room death of Rodney King, a 47 year old resident of Rialto. Lightner said at 0526 hours, a caller from King's residence at 1051 E. Jackson St. in the city of Rialto had called 911. Moments prior to the 911 call, King had been screaming in his backyard and found floating naked face down at the bottom of the deep end of his pool. Officers from the Rialto Police Department arrived on scene at approximately 0529 hours. Officers immediately jumped into the deep end of the pool and pulled unresponsive King out of the pool. Officers initiated cardiopulmonary resuscitation and members of the Rialto Fire Department (RFD) ME202 with Medic Cathey P2398 initiated advanced cardiac life support measures at 0536 hours. RFD transported King and arrived at Arrowhead Regional Medical Center at approximately 0605 hours. Dr. Yuen pronounced death at 0611 hours. There was no admit blood taken.

NOTE TO PATHOLOGY

San Bernardino County Sheriff - Coroner Division

Coroner Investigation

**2**MODE **Accident**CASE # **701204304**STATUS **Post**DEPUTY **Teri Lay****MEDICAL**

TRANSPORTED FROM RFD from scene	ADMITTED TO? ARMC	DATE 06-17-12	TIME 0605	M/R ORDERED Yes 06-17-12	MED REC # 1989336	BLOOD ORDERED Not Available
------------------------------------	----------------------	------------------	--------------	-----------------------------	----------------------	--------------------------------

CAUSE OF DEATH

107 CAUSE (A) Drowning	TIME INTERVAL Minutes	109 BIOPSY PERFORMED? <input type="checkbox"/> YES <input checked="" type="checkbox"/> NO
DUE TO (B)		110 AUTOPSY PERFORMED? <input checked="" type="checkbox"/> YES <input type="checkbox"/> NO
(C)		AUTOPSY # A0761-12 FS EXAM #
(D)		INDIGENT #

112 OTHER SIGNIFICANT CONDITIONS CONTRIBUTING TO DEATH BUT NOT RELATED TO CAUSE GIVEN IN 107
 Combined ethanol and multiple drug toxicity, cardiomegaly with focal myocardial fibrosis

113 WAS OPERATION PERFORMED FOR ANY CONDITION IN ITEM 107 OR 112? IF "YES" LIST TYPE OF OPERATION & DATE.

☐ YES ☒ NO DESCRIBE

ATTENDING PHYSICIAN N/A	PHONE	DATE LAST ATTENDED	CAUSE GIVEN BY Frank Sheridan
115 PHYSICIAN TO SIGN D.C. Coroner	ADDRESS	PHONE	DATE 08-22-12 TIME 1015

INJURY

119 SPECIFY MODE Accident	123 PLACE OF INJURY Residence	120 AT WK? No	121 DATE 06/17/2012	122 HOUR Unknown
125 LOCATION (include Zip Code)				
124 DESCRIBE HOW INJURY OCCURRED Drowning				

PROPERTY

PROPERTY?	PROP RLS'D?
<input type="checkbox"/> YES <input checked="" type="checkbox"/> NO	<input type="checkbox"/> YES <input type="checkbox"/> NO

LAW ENFORCEMENT

AGENCY Rialto Police Dept. Rialto Police Dept Rialto Police Dept	AGENT Detective Carla McCullough Det. James Mills (Case Agnt) Det. Sgt. Tim Lane	REPORT NUMBER 93-1205123 909-677-7243
---	---	---

AUTOPSY

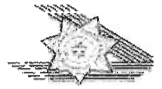
ORDERED BY TL	DATE 06-17-12	TOX ORDERED 06-18-12	TOX RECEIVED 08-16-12	AGENT(S) TO ATTEND ****
------------------	------------------	-------------------------	--------------------------	----------------------------

DISPO OF REMAINS

PRESENT LOCATION ****	MORGUE STATUS	VEHICLE TOWED			
TRANSPORTED BY ****	NOTIFIED BY ****	DATE ****	TIME ****	ARRIVED ****	
44 MORTUARY Forest Lawn Hollywood Hills		PHONE OF MORTUARY 800-204-3131			
<input checked="" type="checkbox"/> REVIEWED BY Campisi 08-22-12 1026					

San Bernardino County Sheriff - Coroner Division

Coroner Investigation

3MODE **Accident**CASE # **701204304**STATUS **Post**DEPUTY **Teri Lay****Coroner Investigation****06/17/2012**

Notification of Death to Coroner:

On 06/17/2012 at 0627 hours, I received notification from our Computer Aided Dispatch (CAD) and Deputy Coroner Investigator D. VanNorman that RN C. Lightner of the Arrowhead Regional Medical Center (ARMC) had called to report the emergency room death of Rodney King, a 47 year old resident of Rialto.

Lightner said at 0526 hours, a caller from King's residence at [REDACTED] in the city of Rialto had called 911. Moments prior to the 911 call, King had been screaming in his backyard and found floating naked face down at the bottom of the deep end of his pool.

Officers from the Rialto Police Department arrived on scene at approximately 0529 hours. Officers immediately jumped into the deep end of the pool and pulled unresponsive King out of the pool. Officers initiated cardiopulmonary resuscitation.

Members of the Rialto Fire Department (RFD) ME202 with Medic Cathey P2398 initiated advanced cardiac life support measures at 0536 hours. RFD transported King and arrived at Arrowhead Regional Medical Center at approximately 0605 hours. Dr. Yuen pronounced death at 0611 hours. There was no admit blood taken.

The original call was received at 0616 hours. I responded from the Coroner's Division (Central Station) at 0658 hours and arrived on-scene at 0710 hours.

Body Description:

At 0720 hours, I began the body examination. The body was that of an unshaven Black male adult identified as Rodney King, a 47 year-old resident of Rialto, by his brother, Zhan Paul King, and later confirmed by fingerprints through Cal Id. Deputy Coroner Supervisor T. Campisi, Deputy Coroner Investigator D. VanNorman, RPD Officer J. McClintock and Detective C. McCullough were present during the body examination.


The body was naked supine on a hospital gurney in the emergency room of Arrowhead Regional Medical Center. A back board and portable advanced cardiac life support back board were under the body. There was a white Arrowhead Regional Medical Center ankle band in the name of Ernest Enigma attached around the right ankle. The body was approximately 75 inches in height and 235 pounds in weight.

There were the following therapeutic devices attached to the body:

1. Endotracheal tube with a facial strap and neck collar.
2. Inserted left nasal tube.
3. Blood pressure cuff to left upper arm.
4. Intravenous line to the left antecubital fossa.

San Bernardino County Sheriff - Coroner Division

Coroner Investigation

4MODE **Accident**CASE # **701204304**STATUS **Post**DEPUTY **Teri Lay**

5. Pulse oximeter to the left index finger.

6. Electrocardiogram and defibrillation patches to the torso and right thigh.

There was a tattoo of unknown writing to the right upper arm. There was a large skin graft area to the left thigh and left hand. There was a large scar to the inner right lower arm and above the right wrist. There was a linear scar on the abdomen. There were multiple scars to the legs and arms.

Upon palpation, there were no obvious sign of fractures to the head, neck, face, torso, or extremities. There were no obvious signs of injuries to the oral area. There was no petechial hemorrhage to the ocular areas. There was bloody discharge from the right nare.

There were the following injuries:

1. There were old abrasions with possible contusions to the right calf.
2. There was an approximately 3 inch contusion to the right inner thigh.
3. There were abrasions to the right lateral torso area.
4. There were new and old abrasions to the anterior area of the feet but no abrasions to the heels.
5. There were abrasions to the knees with several scars.
6. There were new and old abrasions to the posterior area of the hands. There were no abrasions to the palm area of the hands. There was an approximately one inch laceration to the left thumb area.
7. There were large abrasions to the left elbow area.
8. There were old abrasions to the left shoulder.

The body was cool to the touch. When pressed firmly the lower abdomen was warm. Rigor mortis and lividity was not present. The ocular areas were quite red and congested. The hair on the head was damp. The fingertip and feet were not wrinkled from long exposure to water. There was vomit near and around the face and head.

I took 97 photos of the body and scene and VanNorman completed 2 sets of fingerprint cards. I affixed toe tag number 29617 to the great right toe. The body was placed in a yellow Coroner body pouch. The pouch was secured with lock number 4734789 and the examination was concluded at 0850 hours. After the examination, the body was transported to the San Bernardino County Morgue Facility by Southwest Mortuary Transport Services at my request.

Statement of RPD Detective C. McCullough:

McCullough advised the preliminary information revealed the following information:

San Bernardino County Sheriff - Coroner Division
Coroner Investigation

5MODE **Accident**CASE # **701204304**STATUS **Post**DEPUTY **Teri Lay**

On Sunday 06/17/2011 at approximately 0526 hours, King's girlfriend, Cynthia Kelley, woke to King screaming at the rear patio sliding glass door. Kelley found King in the bushes next to the sliding glass door with his underwear down to his knees. Kelley went inside the residence to find her cell phone to call 911.

Kelley went back outside to the backyard and found King naked face down at the deep end of the pool. Kelley called 911 and began to throw things inside the pool.

RPD officers arrived on scene and immediately stripped down their clothes and jumped into the deep end area of the pool. King was on the bottom floor of the pool. King was unresponsive and removed from the pool. Officers placed King on the concrete next to the pool and initiated cardiopulmonary resuscitation. RFD arrived on scene and began advanced cardiac life support measures.

McCullough said King had been partying with a male subject the night of 06/16/2012 at his residence. The male subject was not at the residence when officers arrived on scene.

Statement of Zhan Paul King (Brother):

I contacted Zhan along with cousin, Ontresicia Averette, and numerous family members and friends at Arrowhead Regional Medical Center. Zhan and Ontresicia live together and received a telephone call at 0544 hours from Kelley stating she had been asleep and woke to King screaming, "Baby come and help me!" from his backyard. Zhan and Ontresicia said Kelley was hysterical and not making any sense. Kelley said King was in the bushes and then in the pool and taken to Arrowhead Regional Medical Center. Zhan and Ontresicia immediately drove to Arrowhead Regional Medical Center.

Zhan said King had been doing very well and was happy. King had been on a book tour promoting his book for the 20th Anniversary of the Los Angeles Riots. King had been flying in and out of town frequently and seemed to have his life in order.

Zhan said King's routine was to stay up all night and then sleep during the day. King's daily routine had changed since the book tour.

Zhan and Ontresicia said King was no longer abusing hardcore street drugs or using phencyclidine (PCP). Zhan said King only smoked marijuana occasionally along with drinking alcohol. Zhan and Ontresicia said King was very put together and in control when he was drinking or smoking marijuana. They said he was not the type of person to be disoriented or unable to care for himself.

Zhan said King had no history of recent trauma, accidents, or falls. King had no history of myocardial infarctions, cerebral vascular accident, cancers, or seizures.

King had known Kelley for 20 years but they had been dating for a 1 ½ years. Kelley would spend the weekends with King but he lived alone. Zhan is not aware of any domestic violence incidents between King and Kelley.

I explained some of the injuries on King I had found to Zhan. Zhan said King was like a child and very active in how he played. King had a passion for skateboarding and Zhan felt the old abrasions could be from skateboarding.

San Bernardino County Sheriff - Coroner Division
Coroner Investigation**6**MODE **Accident**CASE # **701204304**STATUS **Post**DEPUTY **Teri Lay****Investigation:**

I permitted Zhan and Ontresicia to view the body at Arrowhead Regional Medical Center.

I cleared Arrowhead Regional Medical Center at 0851 hours. Campisi, McCullough, and I arrived at King's residence at 0900 hours.

Additional scene description:

The residence was located at [REDACTED] in the city of Rialto. The residence was single story family home located on the south side of Jackson Street and west of Beldon Avenue.

The front door faced north and the garage door faced east. The residence consisted of 4 bedrooms. The kitchen was located towards the south portion of the residence. The kitchen was dirty and cluttered. There were numerous cigarettes and empty Miller Lite beer bottles, a partially empty large extra dry Seagram's gin bottle and empty champagne bottle in the kitchen and den. The den was located east off of the kitchen. On a table inside the den I found court paperwork from Riverside County Department of Mental Health dated 06/04/2012 which had King enrolled on 06/15/2012 for (AB1353), driving under the influence alcohol program classes.

South and off of the kitchen was the patio sliding glass door which lead to a small covered patio. The covered patio had a concrete floor. There were small blood droplets on the patio floor. On the south side of the patio was a broken wooden rectangle table with blood on it.

On the east exterior area of the rear patio sliding glass door were numerous smear marks and a shovel propped against the door. East of that area was a flat planter with green plant covering. The plant covering had been smashed. South of the planter was a pair of light blue boxer style underwear.

There was a semi oval shaped pool near the southeast portion of the backyard east of the patio. The pool did not have a fence around it. There was no well lit lighting around the pool area. The pool was approximately 8 feet deep. The water was semi clear and the pool had not been well maintained.

There was a round drain cover attached to the bottom of the pool at the deep end. There was a pitch fork and hoe at the bottom of the deep end along with a vacuum sweeper. There were four floating pieces of tubing that connected to the sweeper in the deep end area of the pool.

King's master bedroom was located in the southwest portion of the residence along with an attached bathroom. The bedroom was untidy and the bed was unmade. I did not locate any drug paraphernalia or prescriptions medications inside the residence. On a night stand near the bed I found a pair of swimming goggles.

It did not appear any sign of a struggle had taken place inside the residence.

The weather had been warm, clear, and dry.

San Bernardino County Sheriff - Coroner Division
Coroner Investigation

7MODE **Accident**CASE # **701204304**STATUS **Post**DEPUTY **Teri Lay****Statement of Cynthia Kelley (Girlfriend):**

Kelley said she had known King for approximately 20 years. Kelley said she had been a jury member on King's civil lawsuit. Kelley said she was dating King but did not live with him full time.

Kelley arrived at King's residence at 1400 hours on 06/16/2012. King had been drinking beer, gin, and champagne. Kelley said they had never had any domestic violence incidents together and King had treated her well.

King had been drinking throughout the day and into the night. King wanted to buy some marijuana but the medical marijuana clinic he used would not sell to him over an auto repair disagreement.

King told Kelley at 2100 hours that he was going to pick up his friend Derek and buy \$20.00 worth of marijuana. King was intoxicated but drove off from his residence to pick up Derek. Kelley stayed at King's residence while she waited. King and Kelley spoke on the cell phone while he was gone. King was telling Derek how much he loved Kelley and was going to marry her. Kelley had never met Derek before 06/16/2012. At 2200 hours, Kelley said King and Derek arrived at the residence. The three of them continued drinking. King and Derek smoked several marijuana joints outside in the backyard. Kelley said she did not smoke any marijuana and only had champagne. Kelley said everyone was enjoying themselves and there were no issues.

At midnight, Kelley and King took Derek home to a residence in Rialto off of Waterman Ave. Kelley said King was heavily intoxicated so she drove. Kelley said everyone got along and had a good time. After taking Derek home Kelley stopped for cigarettes at King's request.

Kelley and King returned to the residence. Kelley did laundry and King continued drinking. At 0245 hours, Kelley went to bed in King's master bedroom while he stayed up.

At approximately 0526 hours, Kelley woke to King pounding on the closed rear patio sliding glass door. King was grunting and growling. King was not making any sense. King had his underwear down to his knees. King fell onto his back in the planter on the plant covering just east of the rear patio sliding glass door. Kelley said something was not right with King and she went back inside the residence to get her cell phone to call 911.

Kelley heard a splash from the pool and went to the backyard. Kelley said King was naked with his underwear near the planter. Kelley found King face down on the bottom of the pool at the deep end. Kelley called 911.

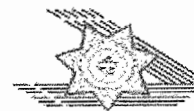
Kelley said she is not a strong swimmer. Kelley said she picked up a pitch fork and hoe from the backyard. Kelley tried jabbing King with the pitch fork and hoe to wake him up. Kelley said King was a strong swimmer.

Kelley said she is not aware of King currently abusing any drugs besides marijuana and alcohol or having any medical issues.

During my contact with Kelley, I did not observe any signs of injuries to her.

Continuing Investigation:

San Bernardino County Sheriff - Coroner Division
Coroner Investigation

8MODE **Accident**CASE # **701204304**STATUS **Post**DEPUTY **Teri Lay**

I cleared the scene from the residence at 1000 hours.

Fingerprints were delivered to Cal Id and the identity was confirmed. Medical Records from Arrowhead regional Medical Center were submitted to the morgue.

Family and Kelley were difficult to interview. Family appeared reluctant on providing detailed information on King. Kelley was emotional, distraught, and appeared intoxicated. I did not see any obvious injuries or a sign of a struggle on Kelley.

I spoke to King's daughter, Lora Dena King, at 1030 hours by telephone. Lora said King had no medical history except for joint pain to his knees. King did not have a primary medical physician and was not taking any prescription medications. Lora did not know the history of King's current drug use.

King had a long criminal history of narcotic/alcohol, domestic violence, death threats, robbery, thefts, and parole hold incidents. King has a past and recent history of drug/alcohol rehabilitation.

A fax for medical records from Pacifica Hospital as a result of the Los Angeles Police Department altercation on 03/02/1991 was submitted. The records are with a storage company and may take several weeks to locate per staff members.

I contacted Decedent Affairs Clerk Betty Menor at Arrowhead Regional Medical Center who advised she has medical records from a gunshot wound to the face and upper body from 2007 and a traffic collision in 2003. The records are in storage but she will attempt to locate and fax them to the Coroner's Division.

On 06/18/2012 at 1036 hours, I spoke to RPD Detective G. Marquez who was present during the autopsy. Marquez advised in 2007, King had been riding his bicycle in the dark and was struck by several bird shot projectiles. It was suspected that King had been involved in some type of narcotic incident at the time of the shooting. King was uncooperative and no weapon(s) or suspect(s) were located. The area of the shooting was possibly in the area of 5th Street and Meridian Ave. in the city of Rialto. King rode his bicycle home then called 911 and was transported to Arrowhead Regional Medical Center with minor injuries.

In 2003, King was involved in a traffic collision where he crashed into a house in the city of Rialto and fractured his pelvis and was transported to Arrowhead Regional Medical Center.

Disposition:

Submitted to Pathology for autopsy.

San Bernardino County Sheriff - Coroner Division

Coroner Investigation

9

MODE Accident

CASE # 701204304

STATUS Post

DEPUTY Teri Lay

**Coroner Supplement Report**

07/13/2012

Deputy Teri Lay:

On 07/13/2012 at 0800 hours, Deputy Coroner Supervisor R. Shaw, Medical Examiner Dr. F. Sheridan, Rialto Police Department (RPD) Officers J. Milles, C. Farmer, A. Qinoñez, and I had a meeting to discuss this investigation at the Coroner's Division. Mills said their investigation had revealed the following information: Primary officers that first arrived on scene described King as upright in the deep end area of the pool with his knees bent and head a few inches from the water surface.

A cousin had said King had been riding his bicycle approximately a week before his death. King called the cousin and appeared confused stating he had been riding his bicycle for 4 to 5 hours and was lost. King had no clue where he was. King said he had crashed on his bicycle. The cousin told King to look for a street sign which he found and said he was on Cherry Avenue in the city of Fontana. The cousin said King's behavior was not normal during the conservation.

King's girlfriend, Cynthia Kelley, said every morning she would call King at 0700 hours. The weekend before King's death, Kelley had called King at 0700 hours. King told Kelley he was drinking alcohol and told Kelley he had been drinking all night.

Kelley said the day before King's death, he appeared hot and clammy. During the mid day King took a shower for more than an hour to cool off.

Kelley admitted to cleaning up before the RPD officers arrived on scene on 06/17/2012. Kelley later said she had hidden a partially smoked marijuana joint in the backyard. The marijuana joint was later found under a leaf in the backyard. The marijuana joint had been smoked by King and his friend Derek per Kelley. The marijuana joint had a discoloration to it. A small amount of marijuana was later located in the kitchen. Mills advised the marijuana and marijuana joint were delivered to the San Bernardino Sheriff's Department Scientific Crime Lab for testing.

Mills said 6 days after death, a small empty freshly dug hole in the backyard was discovered.

Mills contacted Derek on 06/17/2012, and advised his behavior was calm and normal. Derek said he and King had been best friends for many years and he had never met Kelley until 06/16/2012.

Derek said while he was visiting King and Kelly on 06/16/2012, he had brought over a small amount of cheap street marijuana which was enough for 3 marijuana joints. Derek and King smoked the marijuana joint while King drank Gin and beer. Derek said King's mood and emotions were erratic. King would go from happy to mad very quickly. King was upset that people were using his names to make money off of him. King was also upset that his car needed to be repaired and the Mexicans were not treating him right.

Derek said Kelley wanted him to go home. King told Derek he could leave and ride his bicycle home but Derek had no bicycle with him. Derek said he left the rest of the marijuana in the kitchen. King and Kelley later took him home.

San Bernardino County Sheriff - Coroner Division
Coroner Investigation

10MODE **Accident**CASE # **701204304**STATUS **Post**DEPUTY **Teri Lay**

Derek said he had no negative effects from the marijuana joint he had smoked with King. King had spoken very fondly of Kelley to him.

Mills learned from family and friends that expressed concerns that Kelley was very controlling of King. King did not have a checking account. When King received payments from his book tour, Kelley would deposit the checks directly into her personal checking accounts. Kelley would then give King a spending allowance as needed.

Mills said there was no known history of domestic violence between Kelley and King. Mills did not noticed any injuries on Kelley.