

COUNTY OF LOS ANGELES

DEPARTMENT OF MEDICAL EXAMINER-CORONER

12**AUTOPSY REPORT**No. 2018-06929
MCCORMICK, MALCOLM
JAMES MEYERS

I performed an autopsy on the body of



at THE DEPARTMENT OF MEDICAL EXAMINER-CORONER

Los Angeles, California on September 8, 2018 0900
(Date) (Time)From the anatomic findings and pertinent history I ascribe the death to:

(A) Mixed drug toxicity (fentanyl, cocaine, ethanol)

(B)

(C)

(D)

OTHER CONDITIONS CONTRIBUTING BUT NOT RELATED TO THE IMMEDIATE CAUSE OF DEATH:

Anatomical Summary:

I. Pulmonary edema, moderate

II. Blunt trauma, head

A. Nasal bridge abrasion

CIRCUMSTANCES:

Please see Investigator's Report.

EXTERNAL EXAMINATION:

The body is identified by toe tags and is that of an unembalmed refrigerated adult male who appears the reported age of 26 years. The body measures 67 inches, weighs 159 pounds, and is normally developed. Hydration and nutritional status are grossly normal. Examination of the skin no evidence of jaundice. Scars: not identified. Tattoos: (numerous present with only a select few described) left lateral aspect of neck rose, mid upper chest 'No Woman No Cry', lateral aspect of right deltoid Einstein face with tongue out, mid chest bird like symbol, right axilla 'Most Dope' with tragedy/comedy masks, right axilla Pennsylvania with star on localization of Pittsburgh, left bicep Marilyn Monroe in red dress being pushed up, left axilla clock, mid abdomen 'We are confused', anterior aspect of left forearm 'Only so much time left in this crazy world', anterior aspect of right wrist 'Beats rhymes and left', right shin alien riding spaceship, right shin boxing kangaroo,

12**AUTOPSY REPORT**

No. 2018-06929
MCCORMICK, MALCOLM
JAMES MEYERS

Page 2

left shin flames with woman, left upper back persons face wearing glasses, posterior neck globe, right upper back balloon with person in canoe, posterior aspect of right forearm John Lennon face, posterior aspect of right hand 'P' in the style of the Pittsburgh Pirates. Rigor mortis is absent. Livor mortis is fixed and anterior of the upper face.

The head is normal in size and shape. The scalp hair is brown. There is no temporal or vertex balding. Mustache is present. Beard is present. Examination of the eyes reveals irides that appear to be hazel and sclerae that are white. The conjunctivae are not congested. The oronasal passages are unobstructed. There is no foam in the nares or oral cavity. There is patchy bright red blood of the right nares with no evidence of septal perforation. Upper and lower teeth are present. Frenulae and oral mucosa are intact.

There is no chest deformity. There is no increased anterior-posterior diameter. The abdomen is unremarkable. The genitalia are those of an adult male. The external genitalia are without trauma or lesions.

EVIDENCE OF THERAPEUTIC INTERVENTION:

There is no evidence of recent therapeutic intervention. Recent needle punctures are not identified. There has not been post mortem intervention for organ procurement.

POST MORTEM CHANGES:

None identified.

EVIDENCE OF TRAUMATIC INJURY:**Blunt trauma, head**

1. Nasal bridge red abrasion, 0.25 inch

12**AUTOPSY REPORT**

No. 2018-06929
MCCORMICK, MALCOLM
JAMES MEYERS

Page 3**INITIAL INCISION:**

The body cavities are entered through the standard coronal incision and the standard Y-shaped incision. No foreign material is present in the mouth, upper airway, and trachea.

NECK:

The neck organs are removed en bloc with the tongue. There is no edema of the larynx. There is froth with a pink tinge of the trachea and larynx. Both hyoid bone and larynx are intact and without fractures. No hemorrhage is present in the adjacent throat organs investing fascia, strap muscles, thyroid, or visceral fascia. There are no prevertebral fascial hemorrhages. The tongue when sectioned shows no trauma.

CHEST/ABDOMINAL CAVITY:

Pleural effusions are absent. Pleural fibrous adhesions are absent. The parietal pleurae are intact. Soft tissues of the thoracic and abdominal walls are well-preserved. The organs of the abdominal cavity have a normal arrangement and none are absent. Ascites is not present. The peritoneal cavity is without evidence of peritonitis. There are no adhesions.

SYSTEMIC AND ORGAN REVIEW:

Note: The following observations are limited to findings other than injuries, if described above.

MUSCULOSKELETAL SYSTEM:

No abnormalities of the uninjured bony framework or muscles are identified.

CARDIOVASCULAR SYSTEM:

The thoracic and abdominal aorta have no atherosclerosis. There is no tortuosity or widening of the thoracic segment. There is no dilation of the lower abdominal segment. No aneurysm is present. The major branches of the aorta show no abnormality.

12**AUTOPSY REPORT**

No. 2018-06929
MCCORMICK, MALCOLM
JAMES MEYERS

Page 4

Within the pericardial sac there is a minimal amount of serous fluid.

The heart weighs 300 grams. It has a normal configuration. The cardiac silhouette is not globular and the myocardium is not flabby. The right ventricle is 0.3 cm, the interventricular septum is 1 cm in thickness, and the left ventricle is 1 cm in thickness. The chambers are normally developed and are without mural thrombosis. The valves are thin, leafy, and competent. No cardiac valve vegetations are present. There is no endocardial discoloration. There is no abnormality of the apices of the papillary musculature. There are no defects of the septum. The great vessels enter and leave in a normal fashion. The ductus arteriosus cannot be probed. The coronary ostia are patent, located at or below the sinotubular junction and are relatively centrally located within their respective sinuses. The coronary artery distribution is right dominant. Serial sectioning of the coronary arteries show no atherosclerosis.

RESPIRATORY SYSTEM:

Scant secretions are found in the upper respiratory and lower bronchial passages. The mucosa is intact and pale. The right lung weighs 850 grams and the left lung weighs 700 grams. There is predominant anterior lung surfaces congestion. The pulmonary parenchyma is dark red-purple and the cut surfaces exude a moderate amount of blood and frothy fluid. The visceral pleurae are smooth and intact. The pulmonary vasculature is without thromboembolism. There is no evidence of pulmonary infarction.

GASTROINTESTINAL SYSTEM:

The esophagus is intact throughout. Esophageal varices are not present. The stomach contains no food or liquid. The mucosa is unremarkable. The small intestine and colon are unremarkable. The appendix is present. The pancreas occupies a normal position. There is no necrosis or trauma. There is no evidence of pancreatic fibrosis or of pancreatitis.

12**AUTOPSY REPORT**

No. 2018-06929
MCCORMICK, MALCOLM
JAMES MEYERS

Page 5**HEPATOBIILIARY SYSTEM:**

The liver weighs 1700 grams, and is red-brown. The capsule is intact and the consistency of the parenchyma is firm. The cut surface is smooth. There is no evidence of cirrhosis. There is a normal lobular arrangement. The gallbladder is present. The wall is thin and pliable. It contains a moderate amount of bile and no calculi.

URINARY SYSTEM:

The right kidney weighs 200 grams and the left kidney weighs 200 grams. The kidneys are normally situated and the capsules strip easily revealing a surface that is smooth and glistening. The corticomedullary demarcation is preserved. The pyramids are not remarkable. The peripelvic fat is not increased. The ureters are without dilation or obstruction and pursue their normal course. The urinary bladder is unremarkable. It contains approximately 370 cc of yellow urine. The urine is positive for cocaine.

GENITAL SYSTEM:

The prostate is not enlarged and is without nodularity. Both testes are in the scrotum and are unremarkable and without trauma.

HEMOLYMPHATIC SYSTEM:

The spleen weighs 300 grams. The capsule is intact. The parenchyma is dark red and soft. There is no increased follicular pattern. The bone is not remarkable. The bone marrow of the rib is unremarkable.

ENDOCRINE SYSTEM:

The thyroid, adrenal, and pituitary glands are unremarkable. The parathyroid glands are not identified. The thymus is the usual appearance for the age.

SPECIAL SENSES:

The eyes are not dissected. The middle and inner ear are not dissected.

12**AUTOPSY REPORT**

No. 2018-06929
MCCORMICK, MALCOLM
JAMES MEYERS

Page 6**HEAD AND CENTRAL NERVOUS SYSTEM:**

There is no subcutaneous, subgaleal, or subperiosteal hemorrhage in the scalp. The external periosteum and dura mater are stripped showing no fractures of the calvarium or base of the skull. There are no tears of the dura mater. There is no epidural, subdural or subarachnoid hemorrhage.

The brain weighs 1500 grams. The leptomeninges are thin and transparent. A normal convolutionary pattern is observed. Coronal sectioning demonstrates a uniformity of cortical gray thickness. The cerebral hemispheres are symmetrical. There is no softening, discoloration, or hemorrhage of the white matter. The basal ganglia are intact. Anatomic landmarks are preserved. Cerebral contusions are not present. The ventricular system has a normal appearance without dilation or distortion. Pons, medulla, and cerebellum are unremarkable. There is no evidence of uncal or cerebellar herniation. Vessels at the base of the brain have a normal pattern of distribution. There are no aneurysms. The cerebral arteries are without arteriosclerosis.

SPINAL CORD:

The cord is not dissected.

EVIDENCE COLLECTION:

No evidence collected.

HISTOLOGIC SECTIONS:

Representative sections from various organs are preserved in one storage jar.

HISTOLOGIC KEY:

None.

TOXICOLOGY:

12**AUTOPSY REPORT**

No. 2018-06929
MCCORMICK, MALCOLM
JAMES MEYERS

Page 7

Samples of heart blood, femoral blood, urine, bile, and vitreous are submitted to the laboratory. An EDTA tube is collected for blood typing.

SPECIAL PROCEDURES:

None.

PHOTOGRAPHY:

Photographs have been taken prior to and during the course of the autopsy.

RADIOLOGY:

No radiologic examination performed.

WITNESSES:

There were no witnesses.

DIAGRAMS USED:

Diagram forms #20, and 22 were used during the performance of the autopsy. Coroner diagrams are not intended to be facsimiles nor are they drawn to scale.

SUMMARY & OPINION:

This 26 year old man, Malcolm James Meyers McCormick, died of mixed drug toxicity (fentanyl, cocaine, and ethanol).

According to reports, Mr. McCormick was found face down and unresponsive in a residence. Paramedics arrived and pronounced him dead at the scene.

Autopsy revealed pulmonary edema (fluid buildup in lungs), and froth of the upper airways. There was an abrasion of the nose with blood of the right nostril.

Post mortem (after death) toxicology detected fentanyl, cocaine, and ethanol (see separate report).

12**AUTOPSY REPORT**

No. 2018-06929
MCCORMICK, MALCOLM
JAMES MEYERS


Page 8

Fentanyl is a central nervous system depressant with high potential for abuse. It can slow the breathing rate and cause sudden death.

Ethanol is a central nervous system depressant that also slows the breathing rate, and therefore also contributed to death.

Cocaine is a central nervous system stimulant with high potential for abuse. At any concentration it can cause an arrhythmia (lethal heart rhythm) and sudden death.

The manner of death is accident.


Odey C. Ukpo, M.D., M.S.
Senior Deputy Medical Examiner

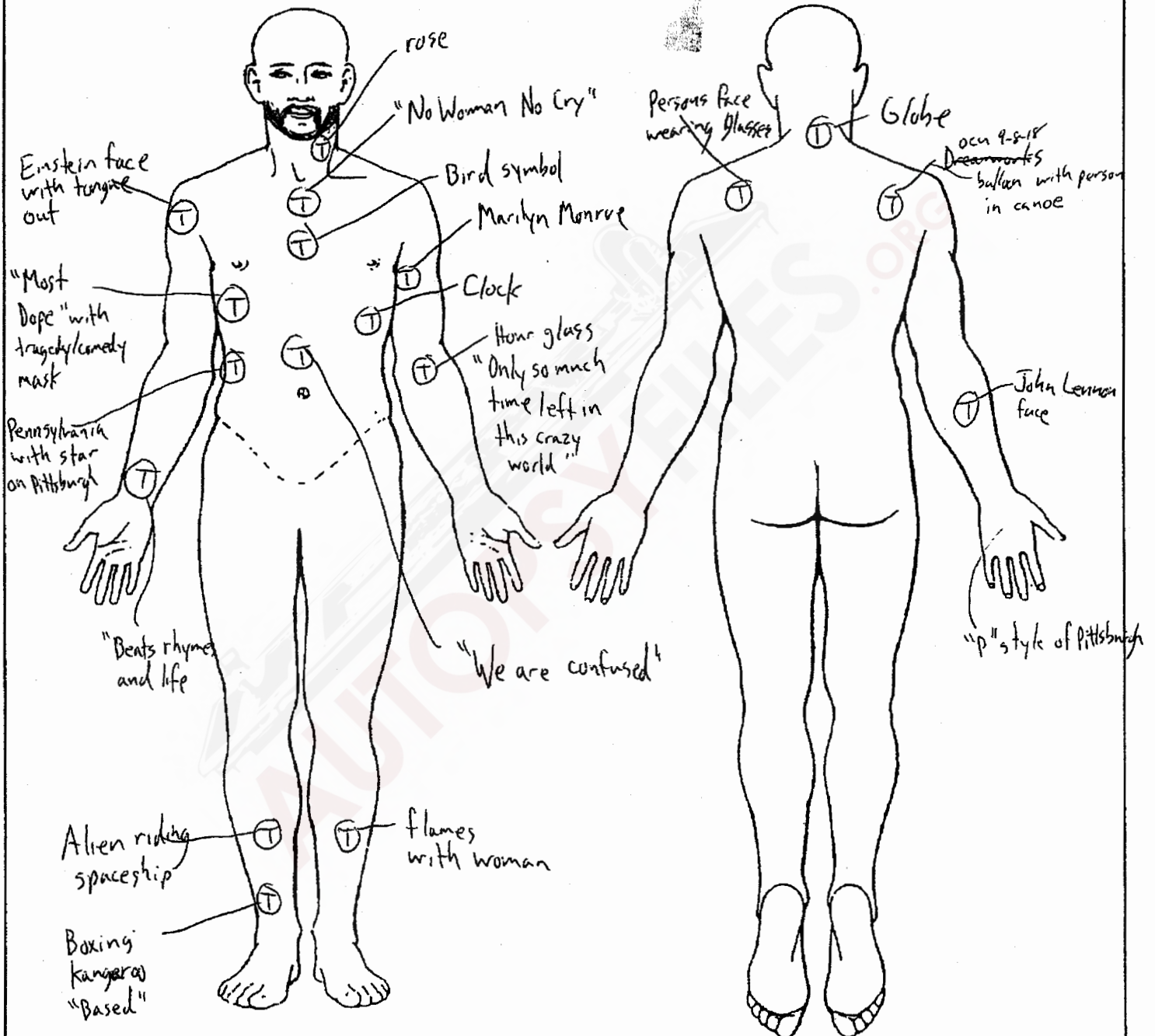
11-5-18
Date

COUNTY OF LOS ANGELES

DEPARTMENT OF MEDICAL EXAMINER-CORONER

20

2018-06929

MCCORMICK, MALCOLM JAMES MYER
ACC 82

Right Thumbprint

Date 9-8-18

Deputy Medical Examiner

M.D.

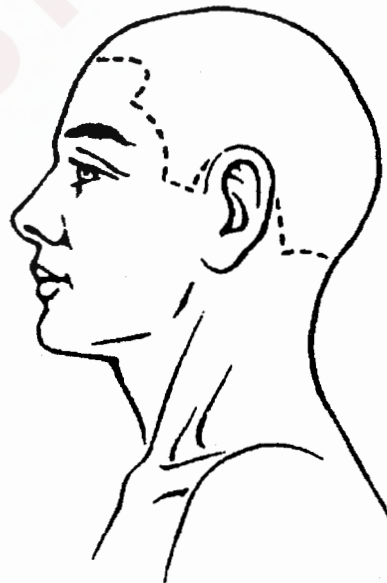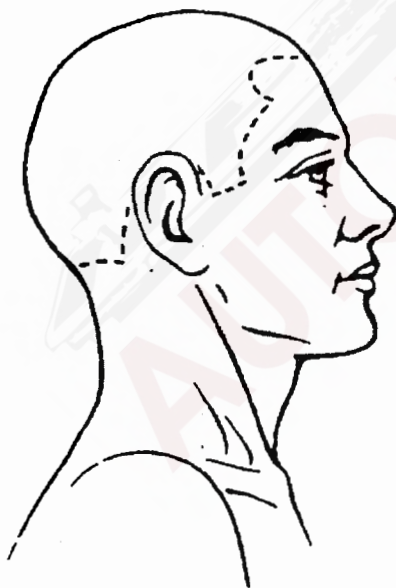
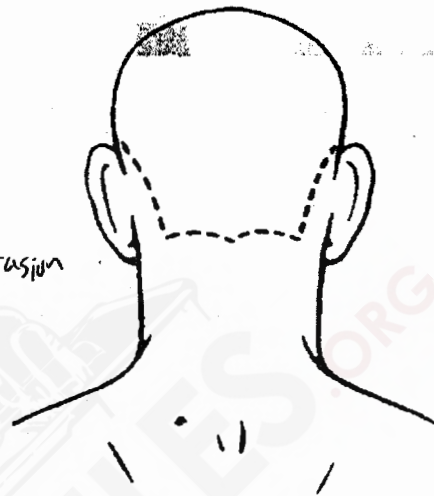
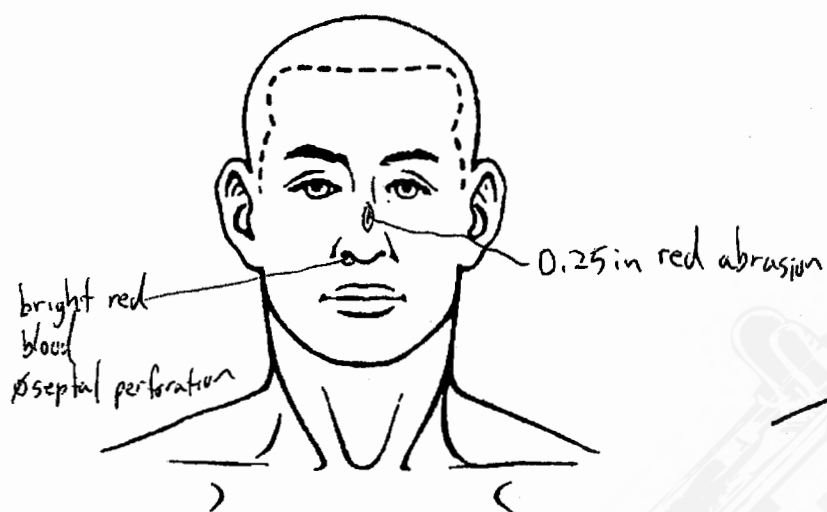
22

2018-06929

MCCORNICK, MALCOLM JAMES HYER

ACC

82



Date

9-8-18

A handwritten signature of the Deputy Medical Examiner.

Deputy Medical Examiner

M.D.

COUNTY OF LOS ANGELES

AUTOPSY CHECK SHEET

DEPARTMENT OF CORONER

16**2018-06929****MCCORMICK, MALCOLM JAMES MYERS**
ACC 82**EXTERNAL EXAM**Sex
Race
Age
Height
Weight
Hair
Eyes
Sclera
Teeth
Mouth
Tongue
Nose
Chest
Breasts
Abdomen
Scar
Genitals
Edema
Skin
Decubitus**HEART Wt. 300**Pericardium
Hypertrophy
Dilation
Muscle
Valves
Coronaries**AORTA****VESSELS****LUNGS Wt.**R **850**L **700**

Adhesions

Fluid

Atelectasis

Oedema (+)

Congestion

Consolidation

Bronchi

Nodes

PHARYNX**TRACHEA** (+) froth**THYROID****THYMUS****LARYNX****HYOID****ABDOMINAL WALL FAT****PERITONEUM**

Fluid

Adhesions

LIVER Wt. 1706

Capsule

Lobules

Fibros

G B (+)

Calculus

Bile ducts

SPLEEN Wt. 300

Color

Consistency

Capsule

Malpiment

PANCREAS**ADRENALS****KIDNEYS Wt.**R **200**L **200**

Capsule

Cortex

Vessels

Pelvis

Ureters

BLADDER 370 cc**GENITALIA**

Prostate

Testes

~~Uterus~~~~Tubes~~~~Ovaries~~**ESOPHAGUS****STOMACH**

Contents (+)

DUOD. & SM. INT.**APPENDIX (+)****LARGE INT.****ABDOM. NODES****SKELETON**

Spine

Marrow

Rib Cage

Long bones

Pelvis

SCALP**CALVARIUM****BRAIN Wt. 1500**

Dura

Fluid

Ventricles

Vessels

Middle ears

Other

PITUITARY**SPINAL CORD****TOXICOLOGY SPECIMENS****SECTIONS FOR
HISTOPATHOLOGY****MICROBIOLOGY****DIAGRAMS
X-RAYS****OTHER PROCEDURES****GROSS IMPRESSIONS**

Date

9-8-18

Time

0900

Deputy Medical Examiner

Steph G. W.

COUNTY OF LOS ANGELES

MEDICAL REPORT

DEPARTMENT OF MEDICAL EXAMINER-CORONER

15

AUTOPSY CLASS: ☐ A ☒ B ☐ C ☐ Examination Only D☐ FAMILY OBJECTION TO AUTOPSYDate: 9-8-18 Time: 0900 Dr. Oley Ukpo
(Print)FINAL ON: 11-5-18 By: Oley Ukpo
(Print)APPROXIMATE
INTERVAL
BETWEEN
ONSET
AND
DEATH

2018-06929

McCORMICK, MALCOLM JAMES MYER
82

DEATH WAS CAUSED BY: (Enter only one cause per line for A, B, C, and D)

IMMEDIATE CAUSE:

(A) Mixed drug toxicity (fentanyl, cocaine, ethanol)

DUE TO, OR AS A CONSEQUENCE OF

(B)

DUE TO, OR AS A CONSEQUENCE OF:

(C)

DUE TO, OR AS A CONSEQUENCE OF:

(D)

OTHER CONDITIONS CONTRIBUTING BUT NOT RELATED TO THE IMMEDIATE CAUSE OF DEATH:

Age: 26 Gender: Male / Female

PRIOR EXAMINATION REVIEW BY DME

☒ BODY TAG ☐ CLOTHING
☐ X-RAY (No. _____) ☐ FLUORO
☐ SPECIAL PROCESSING TAG ☐ MED. RECORDS
☐ AT SCENE PHOTOS (No. _____)

CASE CIRCUMSTANCES

☐ EMBALMED
☐ DECOMPOSED
☐ >24 HRS IN HOSPITAL
☒ OTHER: field (Reason)

TYPING SPECIMEN

TYPING SPECIMEN TAKEN BY Fernandez
SOURCE: heart blood

TOXICOLOGY SPECIMEN

 COLLECTED BY: Fernandez
☒ HEART BLOOD ☐ STOMACH CONTENTS
☒ FEMORAL BLOOD ☒ VITREOUS
 TECHNIQUE: ext
☐ BLOOD ☐ SPLEEN
☐ BLOOD ☐ KIDNEY
☒ BILE ☒ EDTA heart blood
☐ LIVER
☒ URINE
URINE GLUCOSE DIPSTICK RESULT: 4+ 3+ 2+ 1+ 0
TOX SPECIMEN RECONCILIATION BY: _____

HISTOLOGY

☒ Regular (No. 1) ☐ Oversize (No. _____)
 Histopath Cut: ☐ Autopsy ☐ Lab

TOXICOLOGY REQUESTS

 FORM 3A: ☐ YES ☐ NO
☐ NO TOXICOLOGY REQUESTED
 SCREEN ☒ C ☐ H ☐ T ☐ S ☐ D
☐ ALCOHOL ONLY
☐ CARBON MONOXIDE
☐ OTHER (Specify drug and tissue)
urine @ cocaine
bile testing only if indicated or requested

REQUESTED MATERIAL ON PENDING CASES

☐ POLICE REPORT ☐ MED HISTORY
☒ TOX FOR COD ☐ HISTOLOGY
☐ TOX FOR R/O ☐ INVESTIGATIONS
☐ MICROBIOLOGY ☐ EYE PATH. CONS.
☐ RADIOLOGY CONS.
☐ CONSULT ON:
☐ BRAIN SUBMITTED
☐ NEURO CONSULT ☐ DME TO CUT
☐ CRIMINALISTICS
☐ GSR ☐ SEXUAL ASSAULT ☐ OTHER

☐ NATURAL ☐ SUICIDE ☐ HOMICIDE
☐ ACCIDENT ☐ COULD NOT BE DETERMINED
If other than natural causes,
HOW DID INJURY OCCUR? Recreational usageWAS OPERATION PERFORMED FOR ANY CONDITION STATED ABOVE: ☐ YES ☐ NO

TYPE OF SURGERY: _____ DATE: _____

☐ ORGAN PROCUREMENT ☒ TECHNICIAN: M Fernandez
 PREGNANCY IN LAST YEAR ☐ YES ☐ NO ☐ UNK ☐ NOT APPLICABLE

☐ WITNESS TO AUTOPSY ☐ EVIDENCE RECOVERED AT AUTOPSY
 Item Description:

RESIDENT

DME



Department of Medical Examiner-Coroner, County of Los Angeles

FORENSIC SCIENCE LABORATORIES

1104 North Mission Road, Los Angeles, CA 90033

Laboratory Analysis Summary Report

Ukpo, Odey M.D.Deputy Medical Examiner
1104 North Mission Road
Los Angeles, CA 90033☒ PendingTox

Coroner Case Number: 2018-06929 Decedent: MCCORMICK, MALCOLM JAMES M

<u>SPECIMEN</u>	<u>SERVICE</u>	<u>DRUG</u>	<u>RESULT</u>	<u>ANALYST</u>
-----------------	----------------	-------------	---------------	----------------

Alcohol Quantitation/Confirmation

Blood, Femoral

Alcohol-GC/FID-HS	Ethanol	0.031 g%	A. Chavez
-------------------	---------	----------	-----------

Blood, Heart

Alcohol-GC/FID-HS	Ethanol	0.022 g%	A. Chavez
-------------------	---------	----------	-----------

Vitreous

Alcohol-GC/FID-HS	Ethanol	0.041 g%	A. Chavez
-------------------	---------	----------	-----------

Drug Screen

Blood, Heart

ELISA-Immunoassay	Barbiturates	ND	D. P. Cruz
ELISA-Immunoassay	Benzodiazepines	ND	D. P. Cruz
ELISA-Immunoassay	Cocaine and Metabolites	PP	D. P. Cruz
ELISA-Immunoassay	Fentanyl	PP	D. P. Cruz
ELISA-Immunoassay	Marijuana: 11-nor-Delta-9-Carboxy-THC	ND	D. P. Cruz
ELISA-Immunoassay	Methamphetamine & MDMA	ND	D. P. Cruz
ELISA-Immunoassay	Opiates: Codeine & Morphine	ND	D. P. Cruz
ELISA-Immunoassay	Opiates: Hydrocodone & Hydromorphone	ND	D. P. Cruz
ELISA-Immunoassay	Phencyclidine	ND	D. P. Cruz

Drug Screen/Confirmation

Blood, Femoral

Cocaine-GC/MS	Benzoyllecgonine	1.1 ug/mL	I. Lee
Cocaine-GC/MS	Cocaethylene	0.10 ug/mL	I. Lee
Cocaine-GC/MS	Cocaine	0.11 ug/mL	I. Lee
Fentanyl-GC/MS	Fentanyl	8.2 ng/mL	C. Castellino

Blood, Heart

Bases-GC/NPD &/or MS	Basic Drugs	ND	R. Cabrera
Cocaine-GC/MS	Benzoyllecgonine	1.2 ug/mL	I. Lee
Cocaine-GC/MS	Cocaethylene	0.04 ug/mL	I. Lee

Coroner Case Number: 2018-06929 **Decedent:** MCCORMICK, MALCOLM JAMES M

<u>SPECIMEN</u>	<u>SERVICE</u>	<u>DRUG</u>	<u>RESULT</u>	<u>ANALYST</u>
	Cocaine-GC/MS	Cocaine	0.03 ug/mL	I. Lee
	Fentanyl-GC/MS	Fentanyl	19 ng/mL	C. Castellino
	Opiates-GC/MS	Oxycodone, Total	ND	I. Lee
	Opiates-GC/MS	Oxymorphone, Total	ND	I. Lee
	Sympath. Amines-GC/MS	Amphetamine	ND	D. Van Cleve


Legend:	mg/dL	Milligram per Deciliter	PP	Presumptive Positive
g	Grams	mg/L	QNS	Quantity Not Sufficient
g%	Gram Percent	ND	ug	Micrograms
Inc.	Inconclusive	ng/g	ug/g	Micrograms per Gram
mg	Milligrams	ng/mL	ug/mL	Microgram per Milliliter

The alcohol analysis was performed in accordance to California Code of Regulations "Title 17" compliance by a qualified analyst in the Forensic Toxicology Laboratory, Forensic Laboratories Division, County of Los Angeles Department of Medical Examiner - Coroner.

Enzyme-linked immunosorbent assay (ELISA) provides only a preliminary analytical result that is contingent upon a confirmatory test. A "presumptive positive" (PP) signifies a detection of a drug class and must be confirmed by additional testing for true identification and/or quantitation of specific drug(s) present in the specimen.

In accordance with the Department's Evidence Retention Policy, the blood specimen(s) will be retained for one-year and all other specimens for six-months from Autopsy.

Final Review By:


Sarah Buxton de Quintana
 Supervising Criminalist I

Date:

10/17/18

The above results have been technically and administratively reviewed and are the opinions and conclusions of the analysts noted. The final review has been certified by the noted Toxicologist to ensure that all standard operating procedures were followed as set by the Forensic Toxicology Laboratory, Forensic Sciences Laboratory Division, County of Los Angeles Department of Medical Examiner-Coroner.

OCU 10-24-18

Bukpo

COUNTY OF LOS ANGELES

CASE REPORT

DEPARTMENT OF CORONER

1	APPARENT MODE	ACCIDENT	CASE NO	2018-06929
	SPECIAL CIRCUMSTANCES	Celebrity, Media Interest	CRYPT	82

LAST, FIRST MIDDLE	AKA	#
MCCORMICK, MALCOLM JAMES MEYERS		

ADDRESS	CITY	STATE	ZIP
11659 VALLEYCREST DR	STUDIO CITY	CA	91604

SEX	RACE APPEARS	DOB	AGE	HGT	WGT	EYES	HAIR	TEETH	FACIAL HAIR BEARD AND MUSTACHE	ID VIEW	CONDITION
MALE	CAUCASIAN	1/19/1992	26	67 in	159 lbs	HAZEL	BROWN	ALL NATURAL TEETH		Yes	FAIR

MARK TYPE	MARK LOCATION	MARK DESCRIPTION
TATTOO	NECK	UNKNOWN DESIGN
TATTOO	CHEST	BIRD
TATTOO	ABDOMEN	"WE ARE CONFUSED"
TATTOO	LEFT FLANK	"RAIN OR SHINE" ; CLOCK
TATTOO	RIGHT FLANK	"MOST DOPE" ; STATE OF PENNSYL
TATTOO	LEFT ARM	FLOWER ; CHARACTERS
TATTOO	RIGHT ARM	DRAGON ; CROWN
TATTOO	LEFT HAND	"DOPE"
TATTOO	RIGHT HAND	"MOST"
TATTOO	LEFT LEG	SKULL
TATTOO	RIGHT LEG	HOUSE ; UNKNOWN DESIGN

NOK	ADDRESS		CITY		STATE	ZIP
RELATIONSHIP	PHONE	NOTIFIED BY		DATE	TIME	
SSN	DL ID	STATE	PENDING BY	9/7/2018	12:00	
ID METHOD CALIFORNIA DRIVER'S LICENSE						
LA #	MAIN #	CII #	FBI #	MILITARY #	POB	
IDENTIFIED BY NAME (PRINT)			RELATIONSHIP	PHONE	DATE	TIME
CDL VIA CAL-PHOTO, DOJ, LACRIS					9/7/2018	15:00
PLACE OF DEATH / PLACE FOUND		ADDRESS OR LOCATION		CITY	ZIP	
RESIDENCE		11659 VALLEYCREST DR		STUDIO CITY	91604	
PLACE OF INJURY	AT WORK	DATE	TIME	LOCATION OR ADDRESS		ZIP
RESIDENCE	No			11659 VALLEYCREST DR, STUDIO CITY, CA		91604
DOD	TIME	FOUND OR PRONOUNCED BY				
9/7/2018	11:51	LAFD RA 97 GAREER #8744				
OTHER AGENCY INV OFFICER		PHONE	REPORT NO.	NOTIFIED BY		NO
LAPD NORTH HOLLYWOOD - OFC JUAREZ #4272		(818) 754-8300	180907002371			
TRANSPORTED BY		TO		DATE	TIME	
LAURENTIU BIGU		LOS ANGELES FSC		9/7/2018	16:41	
FINGERPRINTS?	Yes	CLOTHING	Yes	PARPT	No	
MED. EV.	Yes	INVEST. PHOTO #	119	SEAL TYPE	CORONER SEAL	
PHYS. EV.	No	EVIDENCE LOG	Yes	PROPERTY?	Yes	
SUICIDE NOTE	No	GSR NO		RCPT. NO.	305854	
MORTUARY						
HOSP RPT No						
HOSP CHART No						
PF NO.						
SYNOPSIS						
THE DECEDENT WAS A 26-YEAR-OLD MAN WHO ON 09/07/2018 AT APPROXIMATELY 1135 HOURS WAS DISCOVERED UNRESPONSIVE IN HIS BEDROOM BY HIS PERSONAL ASSISTANT. THE PERSONAL ASSISTANT DIALED 9-1-1 AND WAS INSTRUCTED BY EMERGENCY DISPATCHERS TO PERFORM CPR. HE PERFORMED CPR UNTIL FIREFIGHTERS/PARAMEDICS ARRIVED ON SCENE. FIREFIGHTERS/PARAMEDICS DETERMINED DEATH AT THE SCENE AT 1151 HOURS. ALCOHOL AND DRUG PARAPHERNALIA WAS LOCATED AT THE SCENE. THE DECEDENT HAD A HISTORY OF ALCOHOL, PRESCRIPTION DRUG, AND ILLICIT DRUG ABUSE. THE DECEDENT HAD NO PERTINENT MEDICAL HISTORY. NO SIGNS OF TRAUMA WERE NOTED. FOUL PLAY IS NOT SUSPECTED.						
LAUREN DIAZ		DATE	9/7/2018	REVIEWED BY	DATE	
642341		TIME	21:39		09/07/18	
INVESTIGATOR		FORM #3 NARRATIVE TO FOLLOW? <input checked="" type="checkbox"/>				



County of Los Angeles, Department of Coroner Investigator's Narrative



Case Number: 2018-06929

Decedent: MCCORMICK, MALCOLM JAMES MEYERS

Information Sources:

- 1) [REDACTED] Personal Assistant [REDACTED]
- 2) Officer Juarez #42721, Los Angeles Police Department North Hollywood Division, Incident #18-0907002371 (818) 754-8300
- 3) [REDACTED] Mother, [REDACTED]

Investigation:

On 09/07/2018 at 1232 hours Officer Simon from the Los Angeles Police Department North Hollywood Division called C. Tardie at the Los Angeles County Department of Medical Examiner-Coroner to report this apparent accidental versus natural death. It was reported that the decedent was discovered unresponsive on his bed by his personal assistant. The decedent was described to be in a "praying position" with fluid excreting from the mouth. The personal assistant performed cardiopulmonary resuscitation until Firefighters/Paramedics arrived on scene. Death was determined at the scene at 1151 hours. No signs of trauma or foul play were noted.

I was assigned this field call by M. Lee on 09/07/2018 at approximately 1300 hours. I arrived on scene at approximately 1402 hours and cleared from the scene at approximately 1605 hours.

During the course of my investigation, the mode of this case was changed from accident versus natural to accident. Foul play is not suspected.

The decedent's fingerprint return and a routine search of Los Angeles County Consolidated Criminal History Report System revealed an alcohol related offense in 2018.

Forensic Attendant L. Bigu transported the decedent from the scene to the Forensic Science Center on 09/07/2018 at approximately 1641 hours.

Location:

Injury: Residence, 11659 Valleycrest Dr, Studio City, CA 91604

Death: Residence, 11659 Valleycrest Dr, Studio City, CA 91604

Informant/Witness Statements:

I spoke with [REDACTED] the decedent's personal assistant, via telephone and he related the following information:

[REDACTED] said that he is the decedent's personal assistant. [REDACTED] comes to the decedent's house daily and wakes him up at approximately 1130 hours. On 09/07/2018 at approximately 1135 hours [REDACTED] arrived at the decedent's house and went into his bedroom to wake him. He discovered the decedent on top of the bed, kneeling with his lower legs on the bed and his face resting on his knees. The decedent was facing the south wall of the bedroom. [REDACTED] attempted to rouse the decedent but was unsuccessful. He said that the decedent appeared to be "blueish" in color. He immediately dialed 9-1-1, moved the decedent to the floor, and performed cardiopulmonary resuscitation at the instruction of emergency dispatchers. He performed cardiopulmonary resuscitation until Firefighters/Paramedics arrived on scene. Firefighters/Paramedics determined death at the scene at 1151 hours.

[REDACTED] stated that he was with the decedent at his residence on 09/06/2018 and last spoke with him at approximately 2230 hours. He said that the decedent had been conducting meetings and going about his usual business. The decedent had not complained of any recent illness or weakness. He was not aware of the decedent consuming any alcohol, prescription medication, or illicit drugs while he was at the residence. He said that the decedent had been in good spirits lately and had many positive, ongoing projects. He said that the decedent is known to abuse



County of Los Angeles, Department of Coroner Investigator's Narrative



Case Number: 2018-06929

Decedent: MCCORMICK, MALCOLM JAMES MEYERS

alcohol, non-prescribed medication (specifically Xanax and unspecified opiates), and cocaine. He said that the decedent struggles with sobriety and when he "slips" he consumes them in excess. He stated that the decedent had several recent "slips", the most recent being on 09/04/2018, when he reportedly consumed alcohol and non-prescribed opiates.

I spoke with Officer Juarez from the Los Angeles Police Department North Hollywood Division at the scene and he related the following information:

On 09/07/2018 at approximately 1159 hours Officers were dispatched to the previously mentioned location in regards to an unresponsive male. Officers arrived on scene and located Firefighters/Paramedics present and the decedent lying supine on the floor of the bedroom. Death had been determined at the scene by Los Angeles Fire Department Paramedic Greer #39744 at 1151 hours, prior to Officers' arrival. An empty bottle of alcohol was noted near the decedent. According to Officers, what appeared to be illicit drugs were located in the residence as well. There were no signs of forced entry into the home. The decedent's valuables were seemingly all present and undisturbed. Foul play is not suspected.

I spoke with [REDACTED] the decedent's mother, via telephone and she related the following:

[REDACTED] stated that she is the decedent's biological mother. She said that he is not currently married and does not have any children. She last spoke with the decedent on the night of 09/06/2018 and said that he appeared to be in good spirits. He seemed very excited about a new album and upcoming tour. She said that the decedent has no medical problems and has never been hospitalized. He was a "heavy smoker" and used tobacco products daily. The decedent had a known history of alcohol and illicit drug abuse. To her knowledge the decedent had never overdosed in the past. The decedent was not diagnosed with any mental health problems and had not displayed any sort of suicidal behavior.

Scene Description:

The scene was a well-furnished single story residence in a residential area. The front door of the residence faced east. Inside the residence was a kitchen to the north, living room to the west, and hallway to the south. A room used as an apparent recording studio was noted at the southernmost point of the hallway. The hallway continued to the west into a master bedroom and bathroom. The studio room contained various recording equipment. A small bag containing a white powdery substance was located on a small table along the north wall of the studio room. On a separate table along the north wall of the studio room an Ipad was noted with linear white powdery residue. An empty bottle of liquor was noted on the desk along the east wall of the studio room. Inside the master bathroom, a bottle of prescription medication prescribed to the decedent was noted. Inside the closet on the west wall of the bathroom, a bag containing a white powdery substance and multiple loose pills were noted inside the pocket of a coat. Inside the master bedroom was a dresser along the east wall, bed along the south wall, piano along the west wall, and television along the north wall. The decedent was noted lying supine on the floor to the east of the bed with his head to the north and his feet to the south. The decedent's lower right leg was noted to be underneath the bed. A rolled 20 dollar bill with a white powdery residue was noted in the right pocket of the decedent's shorts. An empty 750ml bottle of liquor was noted on a nightstand on the west side of the bed.

Evidence:

A white powdery substance, non-prescribed medication, prescription medication, and a rolled 20 dollar bill with white powder residue were collected from the scene and booked into evidence.

**County of Los Angeles, Department of Coroner
Investigator's Narrative**

Case Number: 2018-06929

Decedent: MCCORMICK, MALCOLM JAMES MEYERS

Body Examination:

The decedent was an adult, Caucasian man who appeared to be the reported 26 years of age with brown hair, hazel eyes, red beard and mustache, and apparent natural teeth. The decedent was observed lying supine on the floor of a bedroom. White froth and red tinged sputum were noted from the mouth. Tattoos of unknown design were noted to the bilateral sides of the neck. A tattoo of a bird was noted to the chest. A tattoo reading, "We Are Confused" was noted to the abdomen. A tattoo reading, "Rain Or Shine" was noted to the left flank. A tattoo of a clock was noted to the left flank. A tattoo reading, "Most Dope" was noted to the right flank. A tattoo of the state of Pennsylvania was noted to the right flank. Multiple tattoos were noted to the left arm including a flower and characters. A tattoo reading "DOPE" was noted to the left hand. Multiple tattoos were noted to the right arm including a dragon and crown. A tattoo reading "MOST" was noted to the right hand. A tattoo of a skull was noted to the left lower leg. A tattoo of a house was noted to the right upper leg. A tattoo of unknown design was noted to the right lower leg. A tattoo of globe was noted to the back of the neck. Tattoos of a balloon and man were noted to the back. No other scars, marks, or apparent signs of trauma were noted. Rigor was noted to be a two. Lividity was consistent with positioning upon my arrival and blanched with moderate pressure. Foul play is not suspected.

Identification:

The decedent was positively identified as Malcom James Myers McCormick, DOB 01/19/1992, by comparison to his California Driver's License via Cal-Photo.

Next of Kin Notification:


The decedent's mother, [REDACTED] was notified by other family members. I spoke with her via telephone and confirmed this information.


Tissue Donation:

Organ/tissue procurement was not discussed with the family.

Autopsy Notification:

No exam notification was requested.


LAUREN DIAZ


SUPERVISOR

09/07/2018

Date of Report

COUNTY OF LOS ANGELES

MEDICAL EVIDENCE

DEPARTMENT OF CORONER

3A

CASE # 2018-06929
DECEDENT'S NAME:
MCCORMICK, MALCOLM JAMES
DOD: 9/7/2018
INCOMING MODE:

Page 1 of 1

Drug Name	Rx Number	Date of Issue	Number Issued	Number Remaining	Form	Dosage	Rx Directions	Physician	Pharmacy Phone/ Comments
CEPHALEXIN	699941	5/1/2018	28	28	CAPSULE	500 MG	QID	ISAAC ADATTO	CVS 818-763-5562
Paraphernalia Description WHITE POWDERY SUBSTANCE, ROLLED 20 DOLLAR BILL WITH WHITE POWDERY RESIDUE, XANAX 2MG (QTY: 11.5 TABLETS); OXYCODONE HYDROCHLORIDE 30MG (QTY: 11); AMPHETAMINE/DEXTROAMPHETAMINE 20MG (QTY: 10); HYDROCODONE BITARTRATE 325MG (QTY: 5). ALPRAZOLAM 2MG (QTY: 2)									Investigator: LAUREN DIAZ (642341) Date: 9/7/2018