

**OFFICE OF THE MEDICAL EXAMINER
DISTRICT NINE
2350 E. Michigan Street
Orlando, Florida 32806-4939**

REPORT OF AUTOPSY

DECEDENT: ROBERT CHAMPION **CASE NUMBER:** ME 2011-001392

MANNER OF DEATH: Homicide **IDENTIFIED BY:** Dr. White

AGE: 26 years

SEX: Male

RACE: Black

DATE OF DEATH: November 19, 2011

DATE/TIME OF AUTOPSY: External examination: November 20, 2011@ 9:30 a.m.
Internal examination: November 21, 2011 @ 10:00 a.m.

Sara H. Irrgang MD
J. Garavaglia MD
PERFORMED BY: Sara H. Irrgang, MD, Associate Medical Examiner
with Jan C. Garavaglia, MD, Chief Medical Examiner
in attendance

CAUSE OF DEATH: Hemorrhagic shock, due to
Soft tissue hemorrhage, due to
Blunt force trauma sustained during a hazing incident

AUTOPSY FINDINGS

- I. Hemorrhagic shock from blunt force trauma:
- A. 26-year-old male, with witnessed collapse and arrest soon after being beaten during a hazing event
 - 1. Symptoms of fatigue, thirst, and weakness prior to collapse
 - 2. Stated having vision loss immediately prior to collapse
 - B. Extensive, widespread contusions over chest, right shoulder, arms, and back
 - 1. Extensive hemorrhage in the subcutaneous tissues with crushing of adipose tissue
 - 2. Extensive hemorrhage in fascial planes
 - 3. Extensive hemorrhage in deep muscles

continued...

CHAMPION, ROBERT
ME 2011-001392
PAGE 2

Findings continued ...

- C. Rapid drop of hemoglobin and hematocrit
 - 1. Hospital drawn blood approximately 45 minutes after collapse:
 - a. Hemoglobin 7.0 g/dL; hematocrit 22.8%;
 - 2. Known normal hemoglobin and hematocrit in 2008 (13.6 g/dL and 40.9%, respectively)
 - D. Documented rectal temperature of 102 degrees Fahrenheit during resuscitation
 - E. Liver, pale tan and slightly mottled
 - F. Slight cerebral edema with tonsillar coning
 - G. Extensive aspiration of the gastric contents into lungs
 - 1. Multiple intraparenchymal bronchi filled with aspirated material microscopically
 - H. Normal potassium and creatinine kinase in hospital drawn blood
 - 1. Markedly elevated creatinine kinase in postmortem blood
 - I. No significant fatty emboli microscopically
 - J. Negative toxicology for drugs and alcohol
- II. Postmortem, lower extremity bone and corneal tissue procurement for donation

CHAMPION, ROBERT
ME 2011-001392
PAGE 3

TOXICOLOGY ANALYSIS See laboratory report.

CONCLUSION: Mr. Robert Champion, a previously healthy 26-year-old member of the Florida Agricultural and Mechanical University marching band, collapsed and died within an hour of a hazing incident during which he suffered multiple blunt trauma blows to his body.

Immediately after the hazing incident, he complained of thirst and fatigue; minutes later, he noted loss of vision and soon after had a witnessed arrest. These symptoms are consistent with hypotension or shock. Cardiopulmonary resuscitation ensued with aspiration of stomach contents into his airway.

In the hospital, his hemoglobin and hematocrit were found to be extremely low (7.0 g/dL and 22%, respectively) with no external source of blood loss or intravascular hemolysis. During this time, his potassium was found to be at a normal level as was his creatinine kinase.

The autopsy revealed extensive contusions of his chest, arms, shoulder, and back with extensive hemorrhage within the subcutaneous fat, between fascial planes and within deep muscles. There was also evidence of crushing of areas of subcutaneous fat. He had no injuries to internal organs from the blunt trauma or any bone fractures. He had no evidence of natural disease except for a slightly enlarged heart with a normal left ventricular wall. Subsequent testing revealed no hemoglobinopathies (normal hemoglobin electrophoresis ruled out sickle disease and trait) and negative toxicology for drugs and alcohol. Microscopic examination revealed minimal fatty emboli. He was known to have had a normal hemoglobin and hematocrit (13.6 g/dL and 40.9%, respectively) back in 2008.

Based on the short period of time following the blunt trauma, premorbid symptoms, his collapse and dramatic drop in hemoglobin and hematocrit (indicating a significant rapid blood loss), and the extensive hemorrhage within his soft tissues, including deep muscles, it is our opinion that the death of Robert Champion, a 26-year-old male, is the result of hemorrhagic shock due to soft tissue hemorrhage, incurred by blunt force trauma sustained during a hazing incident.

Manner of death: Homicide.

CHAMPION, ROBERT
ME 2011-001392
PAGE 4

The autopsy of the body of Robert Champion is performed by Sara H. Irrgang, MD, Associate Medical Examiner, Florida District Nine, at the Orange County Medical Examiner facility, Orlando, Florida on November 20, 2011 at 9:30 a.m., pursuant to Florida Statutes.

IDENTIFICATION: The body of Robert Champion is positively identified by FAMU school administrator, Dr. White. The identification is made to Detective Phelan with the Orange County Sheriff's Office on November 20, 2011 @ 1:30 a.m., at Dr. Phillips Hospital.

CLOTHING AND VALUABLES: The body has arrived in the morgue with no clothing articles on, but with a plastic bag containing pants, shoes, socks, and underwear. These items are released as indicated on the Personal Effects Sheet.

SCARS, TATTOOS AND SPECIAL FEATURES: There are no tattoos except on the right upper lateral arm, where a tribal tattoo is present. No surgical scars are seen.

GENERAL STATEMENT: The body for autopsy is that of a 73 inch, 235 lb, normally developed, well nourished, young black male, appearing consistent with the given age of 26 years. No major physical abnormalities are present.

EXTERNAL EXAMINATION

The head is shaved. Facial features reveal brown eyes, congested, with drying artifact of the eyes with pupils equal at 4 mm, with no petechial hemorrhages present. There is a small mustache and beard present. The nose is unremarkable. The mouth shows natural teeth in good repair.

The neck is normally formed with no evidence of traumatic injury or other abnormality.

The abdomen shows the superficial abrasions in the right upper quadrant and just below the belt line (described in Injuries). There is extensive contusion over the chest bilaterally (described in Injuries). The upper back shows discoloration and a mottled appearance (see Evidence of Injury). There are small superficial skin abrasions in the area of the iliac crest which are related to bone harvest. An apparent defibrillator mark is present over the mid chest. No other identifying features are seen.

CHAMPION, ROBERT
ME 2011-001392
PAGE 5

The extremities are symmetric and normally formed, with the hands, fingernails, and feet normally formed. There is a 3 x 4 cm abrasion over the right knee.

SPECIAL PROCEDURES: Specimens taken for evaluation include blood, bile, urine, ocular fluid, brain tissue, a tube of frozen blood for possible genetic studies, and a viral culture. A DNA card is prepared. (The blood is all procurement).

EVIDENCE OF MEDICAL INTERVENTION: When initially seen, on November 20, 2011, prior to procurement, there is an ET tube in the oral cavity and a pacer defibrillator over the right upper breast and another on the left lateral chest, with 3 EKG electrodes over the right shoulder and upper arm, and 3 over the left shoulder and anterior chest. Two additional electrodes are beneath the left breast and one on the right lower quadrant of the abdomen. An IV is present in the right antecubital fossa and another in the dorsum of the right hand. A Foley catheter is in the bladder with a tiny amount of urine present in the tube. A toe tag is on the left great toe. There are Medical Examiner ID bands on each wrist and a hospital band on the right wrist.

EVIDENCE OF INJURY

In summary, on initial external examination, there are superficial abrasions on the right epigastric area and just below the waist on the right abdomen. There are extensive contusions and swelling over the upper chest and breast area with the right greater than the left. Extensive contusions of the back and left flank are also present.

The areas of abrasion on the right mid abdomen are linear and the longest of the three is 8 cm in length, with a 3 cm and a 2 cm abrasion above the longer one. There are pinpoint abrasions in the area above the left nipple, which may or may not be related to his resuscitation attempts, but are near the defibrillator mark. On the lateral left breast, in an area of diffuse contusion, are two parallel purple-gray deeper colored contusions which are almost 2 cm apart and are up to 6 cm in length. On the upper right breast, there is contusion which extends to the clavicle and into the area of the axilla.

On the back, there is a somewhat mottled variegated contusion over the upper back and extending down almost to the waist with shadings of purplish-gray. The area of the back which has the most prominent contusion is the left flank to

CHAMPION, ROBERT
ME 2011-001392
PAGE 6

the posterior axillary line. On the upper back, there are several deeper purple, slightly elevated, linear edematous contusions.

On the second-day examination, the outlines of the areas of bruising on the chest became more defined, but are in the same areas as described, with the large area of left lower back a darker purple-gray color.

Upon exposing the underlying tissue, there is extensive hemorrhage in the right shoulder area, extending over the shoulder, with hemorrhage into the fat. On the lateral left chest, there are areas of hemorrhage in the fat, beneath the parallel contusions noted on the overlying skin.

Extensive examination of the subcutaneous tissue reveals contusions over the right chest in the area that was swollen on external examination with heavy hemorrhage in the subcutaneous adipose tissue and even intramuscular area extending to the level of the nipple and to the right upper arm. There are fainter areas of contusion within the left chest wall over the ribs. The ribs are intact.

The tissue of the back is exposed, revealing extensive hemorrhage in the subcutaneous fat and musculature. The hemorrhage is worse on the upper aspect of the back, particularly in the areas of the midline and right side. There is also extensive hemorrhage extending from the right side of the back into the arm musculature down to the elbow. The hemorrhage in the back is in the subcutaneous tissues, musculature, and between the fascial layers. The adipose tissue appears somewhat macerated in areas. Deep muscle hemorrhage is most prominent over the lower thoracic back. Areas of hemorrhage into the adipose tissue extend to the waist area. Overall, the hemorrhage within the back subcutaneous adipose tissue and musculature and fascial planes is quite prominent.

The neck dissection shows no evidence of traumatic injury to the neck, and the spinal cord is intact.

CHAMPION, ROBERT
ME 2011-001392
PAGE 7

INTERNAL EXAMINATION

BODY CAVITIES: The body cavities are exposed with the usual Y-shaped incision, revealing no blood or extraneous fluid in the chest cavities or in the abdomen. The bony structures are intact and the organs are in their normal anatomic location.

HEART: The heart weighs 490 grams and has an abundant amount of epicardial adipose tissue with the coronary vessels following a normal distribution, with left coronary dominance and with all vessels patent. Sectioning through the wall reveals a left ventricle thickness of 1.4 cm, with the septum 1.2 cm, and the right ventricular wall 0.4 cm. The endocardial surfaces are smooth and glistening and the coronary ostia are widely patent.

The cardiac valves are normally formed and have the following circumferences: aortic valve 8.0 cm, pulmonary valve 9.0 cm, mitral valve 11.5 cm and tricuspid valve 12.5 cm.

PERIPHERAL VASCULAR SYSTEM: The aorta arises in a normal fashion and shows the usual branching with no stenosis or aneurysm formation. The endothelial surface is smooth and glistening.

NECK ORGANS: The larynx, trachea and main stem bronchi are not obstructed, though there is mucoid material with remnants of gastric material. The hyoid bone and thyroid cartilage are intact. The strap muscles of the neck are unremarkable as is the cervical spine. The thyroid gland is of normal size and texture. Remnants of thymus, in small amounts, are present in the anterior mediastinum in the pericardial tissue.

LUNGS: The 510 gram right lung and 490 gram left lung are pink and have essentially no anthracotic streaking and are well aerated, except for the dependent portions which are somewhat congested. The bronchi show mucoid material with remnants of gastric material extending into peripheral bronchi. The tissue on sectioning shows no mass lesions, and the pulmonary vessels are widely patent with no evidence of thromboemboli.

GASTROINTESTINAL SYSTEM: The esophagus is unremarkable. The stomach contains 250 ml of partially digested food material but no pill residue or foreign bodies. There are some very congested areas along the greater curvature adjacent to the pancreas. The mucosa, however, is intact throughout

CHAMPION, ROBERT
ME 2011-001392
PAGE 8

and the appendix is of normal size and appearance. The small and large intestines are normally formed.

PANCREAS: The pancreas weighs 200 grams and has a small amount of hemorrhagic change around the head of the pancreas adjacent to the stomach. Sectioning through the organ, however, reveals the usual pattern of glandular tissue with no internal hemorrhage, no calcification, and no fibrosis.

LIVER: The liver weighs 1960 grams and has a glistening pale brownish-tan capsular surface. Sectioning through the organ reveals a faintly mottled and slightly soft brownish tan parenchyma, with no discrete lesions. The biliary duct system is normally formed and the gallbladder contains 10 ml of dark green bile but no stones.

There are a few tiny white structures appearing to be granulomata, 1-2 mm, in the liver parenchyma.

SPLEEN/LYMPH NODES: The spleen weighs 200 grams and has an intact capsule and dark maroon-red pulp on sectioning, with an increase in white pulp with lymphoid islands easily apparent. A few tiny granulomata measuring 1-2 mm are also noted.

KIDNEYS/URINARY SYSTEM: The 150 gram right kidney and the 160 gram left kidney have smooth glistening cortical surfaces from which the capsule is easily stripped. Sectioning through the kidneys reveals a parenchyma of normal thickness, with a well-defined corticomedullary demarcation with no stones, hemorrhage, or other abnormality. The collecting systems and ureters are not remarkable. The bladder is empty and has a Foley catheter. Obtained from the catheter tubing is 10 ml of yellow urine.

ADRENAL GLANDS: The adrenal glands are normally formed with the usual thickness of yellow cortex and no abnormalities.

REPRODUCTIVE SYSTEM: The external genitalia are normal circumcised adult male. The testes show no mass lesions or other abnormality. The prostate is of normal size and texture for the age of the deceased.

MUSCULOSKELETAL SYSTEM: The extensive hemorrhage in the subcutaneous tissue and in the skeletal muscle over the back, upper chest

CHAMPION, ROBERT
ME 2011-001392
PAGE 9

anteriorly, and upper arm on the right, have been described under Injuries. The bony tissue is intact and is unremarkable.

BRAIN: The scalp is reflected revealing no galeal or subgaleal hemorrhage. The skull is intact. The brain is slightly edematous and weighs 1460 grams, with some flattening of the gyri. The base of the brain shows vessels following the usual pattern, with the vessels thin and delicate. The cerebellar tonsils show slight coning. Sectioning through the brain tissue reveals a sharp gray-white delineation with no mass lesions. The ventricles are minimally compressed, and the cerebrospinal fluid is clear. The leptomeninges and dura are unremarkable. The substantia nigra is normally pigmented.

Stripping the dura from the base of the skull reveals no abnormalities.

The spinal cord is exposed and shows no evidence of traumatic injury.

MICROSCOPIC EXAMINATION

HEART: Sections of myocardium show normal-appearing myocardial fibers, with no inflammation and no fibrosis.

LUNGS: Sections of lungs show extensive pulmonary edema with amorphous pink material filling most of the alveolar spaces. Marked congestion is present. There are large amounts of aspirated gastric material in bronchi, some bronchi involved heavily and others not at all, and an occasional old, small calcified granuloma is noted. No acute inflammation is seen and no evidence of thromboemboli is found.

LIVER: Sections of liver reveal marked congestion, especially centrilobular congestion, and there is focal chronic inflammation in the periportal areas, but not significantly increased. No increase in fibrous tissue is noted. Scattered fat replaced hepatocytes are noted. No bile stasis is seen.

SPLEEN: Sections of the spleen show marked congestion, and there are occasional small calcified granulomata, with the lymphoid tissue of the spleen showing unremarkable germinal centers.

CHAMPION, ROBERT
ME 2011-001392
PAGE 10

PANCREAS: Sections of pancreas show postmortem autolytic change throughout.

KIDNEYS: Sections of kidneys show glomeruli which are predominately normal in appearance, with an occasional sclerotic glomerulus, but the kidney tissue is very congested, and occasional aggregates of material in tubules suggest myoglobin.

BRAIN: Sections of brain show congestion, but normal cellular elements, with no inflammation or other abnormality.

SKIN AND SOFT TISSUE: Sections of tissue from the back show diffuse hemorrhage into the fatty layers, and between the layers along the fascial planes. Hemorrhage into skeletal muscle tissue is quite prominent. Some areas of the fat have an appearance consistent with crushing.

OTHER: Fat stains on brain and lung tissue show very rare blood vessels with a small amount of red-staining fatty material. The lung tissue shows the aspirated material in the bronchi which contains lipid material and is also stained.

SHI/st



Wuesthoff Reference Laboratory

6800 Spyglass Court
Melbourne, Florida 32940
Julie Bell, M.D., Laboratory Director

Patient: CHAMPION, ROBERT
DOB: Age: 26 Sex: M
Client: DIST 9 MEDICAL EXAMINER
Physician: GARAVAGLIA, JAN

Client Patient ID:
MRN: 0001464384 Acct No: 7103432

LABORATORY

Specimen Collected: 11/22/2011	Order No#: 12091187	Status: ROUTINE	Reg Date: 12/09/11			
Test Name	Low	Normal	High	ABN	Reference	Site Code

COMMENTS: Test performed on procurement blood. The validity of the test, clinical significance, and criteria for interpretation have not been established for this sample type. Normal ranges may not apply.

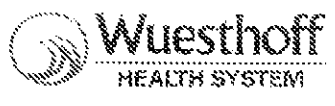
CHEMISTRY

Chemistry

CALCIUM	9.4	8.0-10.4	mg/dL
sample hemolyzed results may be affected Revised: Comment was added, at 17:36 on 12/09/11			
CPK	>6500	CH 24-260	U/L

Lab Key for Results: * - New Results L - Low H - High ABN - Abnormal C - Critical

CHAMPION, ROBERT



Wuesthoff Reference Laboratory

6800 Spyglass Court
Melbourne, Florida 32940
Julie Bell, M.D., Laboratory Director

Patient: CHAMPION, ROBERT
DOB: Age: 26 Sex: M
Client: DIST 9 MEDICAL EXAMINER
Physician: GARAVAGLIA, JAN

Client Patient ID:
MRN: 0001464384 Acct No: 7103432

LABORATORY

Specimen Collected: 11/22/2011	Order No#: 12091180	Status: ROUTINE	Reg Date: 12/09/11			
Test Name	Low	Normal	High	ABN	Reference	Site Code

COMMENTS: Test performed on antemortem blood. The validity of the test, clinical significance, and criteria for interpretation have not been established for this sample type. Normal ranges may not apply.

CHEMISTRY

Chemistry

CALCIUM	10.3	8.0-10.4	mg/dL
sample hemolyzed results may be affected Revised: Comment was added, at 17:36 on 12/09/11			
CPK	731	CH 24-260	U/L

Lab Key for Results: * - New Results L - Low H - High ABN - Abnormal C - Critical

CHAMPION, ROBERT



Wuesthoff Reference Laboratory

6800 Spyglass Court
 Melbourne, Florida 32940
 Julie Bell, M.D., Laboratory Director

Patient: CHAMPION, ROBERT
 DOB: Age: 26 Sex: M
 Client: DIST 9 MEDICAL EXAMINER
 Physician: GARAVAGLIA, JAN

Client Patient ID:
 MRN: 0001464384 Acct No: 7103432

LABORATORY

Specimen Collected: 11/22/2011	Order No#: 12091180	Status: ROUTINE	Reg Date: 12/09/11			
Test Name	Low	Normal	High	ABN	Reference	Site Code

-----**CHEMISTRY**-----

Chemistry

CALCIUM 10.3 8.0-10.4 mg/dL

Testing performed on antemortem plasma.

Sample severely hemolyzed results may be affected
 Revised: Comment was added, at 17:36 on 12/09/11

CPK 731 CH 24-260 U/L

Testing performed on antemortem plasma.

Sample severely hemolyzed results may be affected.
 Revised: Comment was added, at 17:36 on 12/09/11

Lab Key for Results: * - New Results L - Low H - High ABN - Abnormal C - Critical

CHAMPION, ROBERT



Wuesthoff Reference Laboratory

6800 Spyglass Court
Melbourne, Florida 32940
Julie Bell, M.D., Laboratory Director

Patient: CHAMPION, ROBERT
DOB: Age: 26 Sex: M
Client: DIST 9 MEDICAL EXAMINER
Physician: GARAVAGLIA, JAN

Client Patient ID:
MRN: 0001464384 Acct No: 7103432

LABORATORY

Specimen Collected: 11/22/2011	Order No#: 12091187	Status: ROUTINE	Reg Date: 12/09/11			
Test Name	Low	Normal	High	ABN	Reference	Site Code

COMMENTS: Test performed on postmortem blood. The validity of the test, clinical significance, and criteria for interpretation have not been established for this sample type. Normal ranges may not apply.

CHEMISTRY

Chemistry

CALCIUM 9.4 8.0-10.4 mg/dL

Test performed on procurement blood

Sample severely hemolyzed results may be affected.

Revised: Comment was added, at 17:36 on 12/09/11

CPK >6500 CH 24-260 U/L

Test performed on procurement blood.

Sample severely hemolyzed results may be affected.

Revised: Comment was added, at 17:35 on 12/09/11

Lab Key for Results: * - New Results L - Low H - High ABN - Abnormal C - Critical

CHAMPION, ROBERT

INSTANT REPORT

Form: MM Single E


Wuesthoff Reference Laboratory

 6800 Spyglass Court
 Melbourne, Florida 32940
 Julie Bell, M.D., Laboratory Director

 Patient: CHAMPION, ROBERT
 DOB: Age: 26 Sex: M
 Client: DIST 9 MEDICAL EXAMINER
 Physician: GARAVAGLIA, JAN

 Client Patient ID:
 MRN: 0001464384 Acct No: 7103432

LABORATORY

Specimen Collected:	Order No#:	Status:	Reg Date:			
11/22/2011	12091180	ROUTINE	12/09/11			
Test Name	Low	Normal	High	ABN	Reference	Site Code

-----CHEMISTRY-----

Chemistry

CALCIUM	10.3	8.0-10.4	mg/dL
---------	------	----------	-------

Testing performed on antemortem plasma.

 Sample severely hemolyzed results may be affected
 Revised: Comment was added, at 17:36 on 12/09/11

CPK	731	CH	24-260	U/L
-----	-----	----	--------	-----

Testing performed on antemortem plasma.

 Sample severely hemolyzed results may be affected.
 Revised: Comment was added, at 17:36 on 12/09/11

Lab Key for Results: * - New Results L - Low H - High ABN - Abnormal C - Critical

CHAMPION, ROBERT

INSTANT REPORT

Form: MM Single E

Page 1 of 1

Printed: 12/12/11 12:49

DEC 14 2011


Wuesthoff Reference Laboratory

 6800 Spyglass Court
 Melbourne, Florida 32940
 Julie Bell, M.D., Laboratory Director

 Patient: CHAMPION, ROBERT
 DOB: Age: 26 Sex: M
 Client: DIST 9 MEDICAL EXAMINER
 Physician: GARAVAGLIA, JAN

 Client Patient ID:
 MRN: 0001464384 Acct No: 7103432

LABORATORY

Specimen Collected:	Order No#:	Status:	Reg Date:			
11/22/2011	12091187	ROUTINE	12/09/11			
Test Name	Low	Normal	High	ABN	Reference	Site Code

COMMENTS: Test performed on postmortem blood. The validity of the test, clinical significance, and criteria for interpretation have not been established for this sample type. Normal ranges may not apply.

 -----**CHEMISTRY**-----

Chemistry

CALCIUM	9.4		8.0-10.4	mg/dL
---------	-----	--	----------	-------

Test performed on procurement blood

 Sample severely hemolyzed results may be affected.
 Revised: Comment was added, at 17:36 on 12/09/11

CPK	>6500	CH	24-260	U/L
-----	-------	----	--------	-----

Test performed on procurement blood.

 Sample severely hemolyzed results may be affected.
 Revised: Comment was added, at 17:36 on 12/09/11

Lab Key for Results: * - New Results L - Low H - High ABN - Abnormal C - Critical

CHAMPION, ROBERT

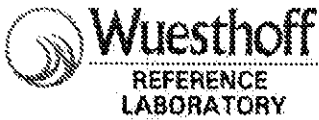INSTANT REPORT

Form: MM Single E

Page 1 of 1

Printed: 12/12/11 12:49

DEC 14 2011



Wuesthoff Reference Laboratory

6800 Spyglass Court
Melbourne, Florida 32940
Julie Bell, M.D., Laboratory Director

Patient: CHAMPION, ROBERT
Client Patient ID: 9-11-1392
Physician: IRRGANG, SARA

Age: 26 Sex: M
Account#: 7096810
Client: DIST 9 MEDICAL EXAMINER

TOXICOLOGY

Specimen Collected :11/21/2011

Lab Order No: 11221612

Reg Date: 11/22/11

Test Name	Result	Units	Cutoff/Reporting Limits
-----------	--------	-------	-------------------------

VOLATILE PANEL - VOLP 98245

SPECIMEN TYPE

PROCUREMENT BLOOD LABELED "ROBERT CHAMPION" "TD-11-128" DATED 11/20/11 @ 1410

ETHANOL	NONE DETECTED	g/dL	0.020
ACETONE	NONE DETECTED	mg/dL	7.5
METHANOL	NONE DETECTED	mg/dL	15.0
ISOPROPANOL	NONE DETECTED	mg/dL	15.0

Analysis by Gas Chromatography (GC) Headspace Injection

BLOOD DRUG SCREEN - BDSME 98216

SPECIMEN TYPE

PROCUREMENT BLOOD LABELED "ROBERT CHAMPION" "TD-11-128" DATED 11/20/11 @ 1410

GC/MS

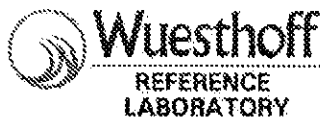CAFFEINE

LC/MS/MS

CAFFEINE, CAFFEINE METABOLITE

BLOOD IMMUNOASSAY SCREEN

AMPHETAMINES	NEGATIVE	mg/L	0.100
BARBITURATES	NEGATIVE	mg/L	0.100
BENZODIAZEPINES	NEGATIVE	mg/L	0.100
BUPRENORPHINE	NEGATIVE	mg/L	0.001
CANNABINOIDS	NEGATIVE	mg/L	0.050
COCAINE METABOLITE	NEGATIVE	mg/L	0.100
FENTANYL	NEGATIVE	mg/L	0.001
METHADONE	NEGATIVE	mg/L	0.050
OPIATES	NEGATIVE	mg/L	0.050
SALICYLATES	NEGATIVE	mg/L	50.0
TRICYCLICS	NEGATIVE	mg/L	0.100



Wuesthoff Reference Laboratory

 6800 Spyglass Court
 Melbourne, Florida 32940
 Julie Bell, M.D., Laboratory Director

 Patient: CHAMPION, ROBERT
 Client Patient ID: 9-11-1392
 Physician: IRRGANG, SARA

 Age: 26 Sex: M
 Account#: 7096810
 Client: DIST 9 MEDICAL EXAMINER

TOXICOLOGY

Specimen Collected :11/21/2011

Lab Order No: 11221612

Reg Date: 11/22/11

Test Name	Result	Units	Cutoff/Reporting Limits
-----------	--------	-------	-------------------------

ELECTROLYTE PANEL - ELEPB 98643

SPECIMEN TYPE

PROCUREMENT BLOOD LABELED "ROBERT CHAMPION" "TD-11-128" DATED 11/20/11 @ 1410

UREA NITROGEN 33.0 mg/dL

CREATININE 3.18 mg/dL

SODIUM 132 mEq/L

POTASSIUM >40.0 mEq/L

Test repeated - result confirmed.

CHLORIDE 89 mEq/L

GLUCOSE 54.9 mg/dL

Glucose results from patients with gammopathies, in particular Waldenstrom's Macroglobulinemia may result in an abnormal reaction profile. Although the incidence of this occurrence is rare, glucose results from these patients should be interpreted with caution.

TOXICOLOGY

Specimen Collected :11/21/2011

Lab Order No: 11221629

Reg Date: 11/22/11

Test Name	Result	Units	Cutoff/Reporting Limits
-----------	--------	-------	-------------------------

URINE DRUG SCREEN COMPREHENSIVE - UDSME 98229

SPECIMEN TYPE

URINE

URINE IMMUNOASSAY SCREEN

AMPHETAMINES NEGATIVE mg/L 0.500

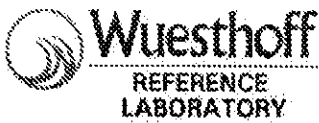BARBITURATES NEGATIVE mg/L 0.200

BENZODIAZEPINES NEGATIVE mg/L 0.200

COCAINE METABOLITE NEGATIVE mg/L 0.150

MDMA/MDA NEGATIVE mg/L 0.300

METHADONE NEGATIVE mg/L 0.300



Wuesthoff Reference Laboratory

6800 Spyglass Court
Melbourne, Florida 32940
Julie Bell, M.D., Laboratory Director

Patient: CHAMPION, ROBERT
Client Patient ID: 9-11-1392
Physician: IRRGANG, SARA

Age: 26 Sex: M
Account#: 7096810
Client: DIST 9 MEDICAL EXAMINER

TOXICOLOGY

Specimen Collected :11/21/2011

Lab Order No: 11221629

Reg Date: 11/22/11

Test Name	Result	Units	Cutoff/Reporting Limits
METHAQUALONE	NEGATIVE	mg/L	0.300
OPIATES	NEGATIVE	mg/L	0.300
OXYCODONE	NEGATIVE	mg/L	0.100
PHENCYCLIDINE	NEGATIVE	mg/L	0.025
PROPOXYPHENE	NEGATIVE	mg/L	0.300
CANNABINOIDS	NEGATIVE	mg/L	0.050
TRICYCLICS	NEGATIVE	mg/L	0.300

TOXICOLOGY

Specimen Collected :11/21/2011

Lab Order No: 11221630

Reg Date: 11/22/11

Test Name	Result	Units	Cutoff/Reporting Limits
VOLATILE PANEL, VITREOUS - VOLPV 98246			
SPECIMEN TYPE			
VITREOUS			
ETHANOL	NONE DETECTED	g/dL	0.020
ACETONE	NONE DETECTED	mg/dL	7.5
METHANOL	NONE DETECTED	mg/dL	15.0
ISOPROPANOL	NONE DETECTED	mg/dL	15.0

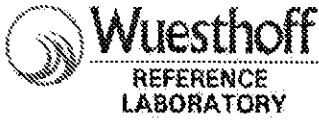Analysis by Gas Chromatography (GC) Headspace Injection

ELECTROLYTE PANEL - ELEPV 98644

SPECIMEN TYPE

VITREOUS

UREA NITROGEN	24.9	mg/dL
CREATININE	0.51	mg/dL
SODIUM	155	mEq/L
POTASSIUM	9.3	mEq/L
CHLORIDE	136	mEq/L



Wuesthoff Reference Laboratory

6800 Spyglass Court
Melbourne, Florida 32940
Julie Bell, M.D., Laboratory Director

Patient: CHAMPION, ROBERT
Client Patient ID: 9-11-1392
Physician: IRRGANG, SARA

Age: 26 **Sex:** M
Account#: 7096810
Client: DIST 9 MEDICAL EXAMINER

TOXICOLOGY

Specimen Collected :11/21/2011

Lab Order No: 11221630

Reg Date: 11/22/11

Test Name	Result	Units	Cutoff/Reporting Limits
-----------	--------	-------	-------------------------

GLUCOSE	17.7	mg/dL	
---------	------	-------	--

Glucose results from patients with gammopathies, in particular Waldenstrom's Macroglobulinemia may result in an abnormal reaction profile. Although the incidence of this occurrence is rare, glucose results from these patients should be interpreted with caution.

Specimens were intact upon receipt. Chain of custody, specimen security and integrity has been maintained. Testing has been performed as requested

Reviewed by: J. J. J. Date: 12/6/11

FINAL REPORT - THIS COMPLETES REPORTING ON THIS CASE

TOXICOLOGY_REPORT

CHAMPION, ROBERT


Wuesthoff Reference Laboratory

 6800 Spyglass Court
 Melbourne, Florida 32940
 Julie Bell, M.D., Laboratory Director

 Patient: CHAMPION, ROBERT
 DOB: Age: 26 Sex: M
 Client: DIST 9 MEDICAL EXAMINER
 Physician: IRRGANG, SARA

 Client Patient ID: 9-11-1392
 MRN: 0001462172 Acct No: 7096810

LABORATORY

 Specimen Collected: 11/21/2011 Order No#: 11221627 Status: ROUTINE Reg Date: 11/22/11
 Test Name Low Normal High ABN Reference Site Code

COMMENTS: Test performed on procurement blood. The validity of the test, clinical significance, and criteria for interpretation have not been established for this sample type. Normal ranges may not apply.

-----CHEMISTRY-----

Misc Chemistry

HEMOGLOBIN A1C	5.7	4.0-6.0	%
Interpretation Guidelines:			
Non-Diabetic:	4.0-6.0 %		
Good Diabetic Control:	6.0-8.0 %		
Diabetic Action Suggested:	>8.0 %		

-----REFERRED TESTING-----

HGB Solubility + Rflx Frac

Hgb A	98.0	94.0-98.0	%
Hgb S	0.0	0.0	%
Hgb C	0.0	0.0	%
Hgb A2	2.0	0.7-3.1	%
Hgb F	0.0	0.0-2.0	%

Interpretation Comment
 Normal adult hemoglobin present.

Performed at: TA, LabCorp Tampa
 5610 W LaSalle Street, Tampa, FL, 336071770
 Sean Farrier, MD, Phone: 8008775227

-----REFERRED TESTING-----

HGB Solubility + Rflx Frac

Hemoglobin Solubility	Negative	Negative
-----------------------	----------	----------

Lab Key for Results: * - New Results L - Low H - High ABN - Abnormal C - Critical

CHAMPION, ROBERT