



**MIAMI-DADE COUNTY
MEDICAL EXAMINER DEPARTMENT**
Number One on Bob Hope Road
Miami, FL 33136
Phone (305) 545-2400 Fax (305) 545-2439



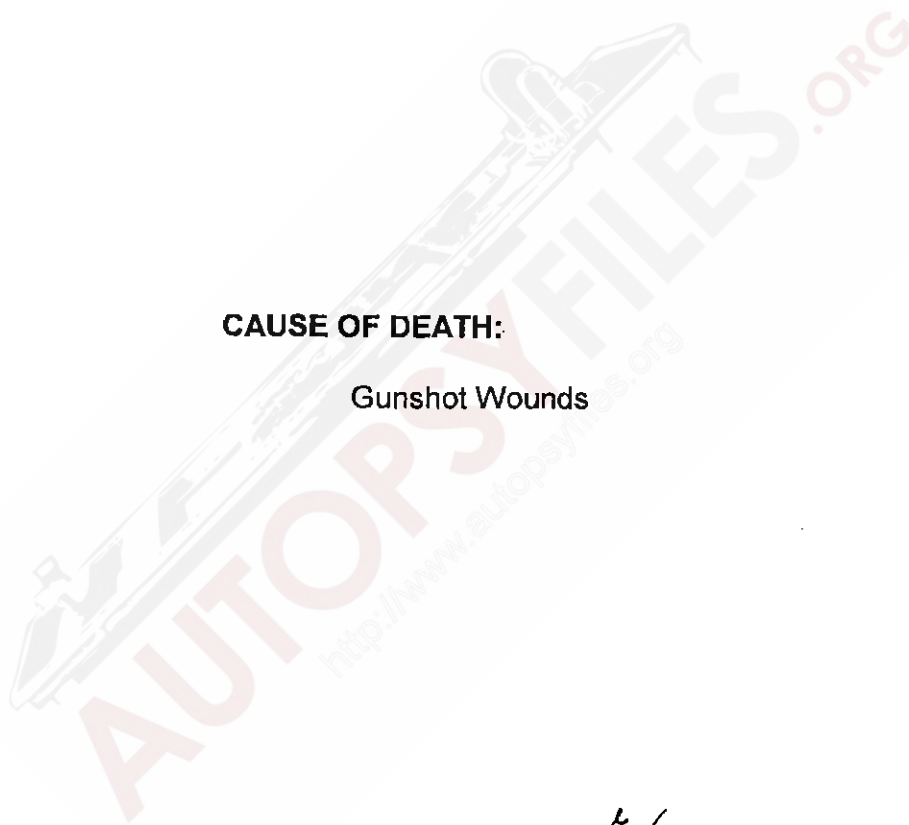
AUTOPSY PROTOCOL

EUGENE, Rudy
May 29, 2012...9:40 A.M.

Case No. 2012-01252

CAUSE OF DEATH:

Gunshot Wounds




Emma O. Lew

Emma O. Lew, M.D.
Deputy Chief Medical Examiner

Date: 6 / 7 / 2012

EOL



Miami-Dade County
Medical Examiner Department
 Number One on Bob Hope Road
 Miami, FL 33136
 Phone (305) 545-2400 Fax (305) 545-2418




TOXICOLOGY REPORT

June 25, 2012

ME Case #: **2012-01252**

Decedents Name: **EUGENE, Rudy**

SUBSTANCE	SPECIMEN	RESULTS	METHOD
VOLATILES	Blood - Iliac Vein	UNDETECTED	GC-Headspace
AMPHETAMINES	Urine	UNDETECTED	EMIT
AMPHETAMINES	Gastric	UNDETECTED	EMIT
SYMPATHOMIMETIC AMINES	Urine	UNDETECTED	Includes MDPV, methylone, mephedrone GCMS
SYMPATHOMIMETIC AMINES	Blood - Chest	UNDETECTED	Includes MDPV, methylone, mephedrone GCMS
METHYLENEDIOXY PYROVALERONE	Blood - Chest	UNDETECTED	Analysis performed by NMS Labs, Inc., Willow Grove, Pa Ref Lab
MEPHEDRONE	Blood - Chest	UNDETECTED	Analysis performed by NMS Labs, Inc., Willow Grove, Pa Ref Lab
METHYLONE	Blood - Chest	UNDETECTED	Analysis performed by NMS Labs, Inc., Willow Grove, Pa Ref Lab
BARBITURATES	Urine	UNDETECTED	EMIT
BARBITURATES	Gastric	UNDETECTED	EMIT
BENZODIAZEPINES	Urine	UNDETECTED	EMIT
BENZODIAZEPINES	Gastric	UNDETECTED	EMIT
BENZODIAZEPINES	Blood - Chest	UNDETECTED	GC-ECD
BENZOYLECGONINE	Urine	UNDETECTED	EMIT
BENZOYLECGONINE	Gastric	UNDETECTED	EMIT
OPIATES	Urine	UNDETECTED	EMIT
OPIATES	Gastric	UNDETECTED	EMIT
OXYCODONE	Urine	UNDETECTED	EMIT
OXYCODONE	Gastric	UNDETECTED	EMIT
PHENCYCLIDINE	Urine	UNDETECTED	EMIT
PHENCYCLIDINE	Gastric	UNDETECTED	EMIT
SALICYLATES	Urine	UNDETECTED	Spot Test
SYNTHETIC CANNABINOIDS	Blood - Chest	UNDETECTED	Analysis performed by NMS Labs, Inc., Willow Grove, Pa Ref Lab
CANNABINOIDS	Urine	DETECTED	EMIT
TETRAHYDROCANNABINOL	Blood - Chest	5 ng/mL	LCMSMS
9-CARBOXY-TETRAHYDROCANNABINOL	Blood - Chest	16 ng/mL	LCMSMS
11-HYDROXY TETRAHYDRO CANNABINOL	Blood - Chest	UNDETECTED	LCMSMS
LYSERGIC ACID DIETHYLAMIDE	Blood - Chest	UNDETECTED	Analysis performed by NMS Labs, Inc., Willow Grove, Pa Ref Lab
BASIC AND NEUTRAL DRUGS	Urine	UNDETECTED	GCMS
BASIC AND NEUTRAL DRUGS	Gastric	UNDETECTED	GCMS



Miami-Dade County
Medical Examiner Department
Number One on Bob Hope Road
Miami, FL 33136
Phone (305) 545-2400 Fax (305) 545-2418




TOXICOLOGY REPORT

ME Case #: **2012-01252**

Decedents Name: **EUGENE, Rudy**

June 25, 2012

SUBSTANCE	SPECIMEN	RESULTS	METHOD
BASIC DRUGS	Blood - Chest	UNDETECTED Includes MDPV, methylone, mephedrone	GC-TSD-FID-MS
ACIDIC & NEUTRAL DRUGS	Blood - Chest	UNDETECTED	GC-TSD-FID-MS



Em

 Lew, Emma O, MD
 6/27/2012

 DATE

RLA



Miami-Dade County
Medical Examiner Department
Number One on Bob Hope Road
Miami, FL 33136
Phone (305) 545-2400 Fax (305) 545-2418



TOXICOLOGY REPORT

February 10, 2015

ME Case #: **2012-01252**

Decedents Name: **EUGENE, Rudy**

SUBSTANCE	SPECIMEN	RESULTS	METHOD
DESIGNER STIMULANTS	Brain	UNDETECTED	LCMSMS



Handwritten signature

Lew, Emma O. MD
2 / 26 / 2015
DATE

DMR



Miami-Dade County
Medical Examiner Department
Number One on Bob Hope Road
Miami, FL 33136
Phone (305) 545-2400 Fax (305) 545-2418




TOXICOLOGY REPORT

October 09, 2014

ME Case #: **2012-01252**

Decedents Name: **EUGENE, Rudy**

SUBSTANCE	SPECIMEN	RESULTS	METHOD
DESIGNER STIMULANTS	Blood - Iliac Vein	UNDETECTED	LCMSMS



Handwritten signature

Lew, Emma O. MD
10 / 19 / 2014
DATE

Dmb

THE MIAMI-DADE COUNTY MEDICAL EXAMINER DEPARTMENT, MIAMI, FLORIDA

EUGENE, Rudy...May 29, 2012...9:40 A.M. ...Case No. 2012-01252

ATTENDEES:

FORENSIC TECHNICIAN: Evelyn Vargas
PHOTOGRAPHER: Belmarie Campos
Sergeant Altarr Williams, City of Miami Police Department

EXTERNAL EXAMINATION:

The body is that of a 5 foot 9 inch, 148 pound black male appearing consistent with the given age of 31 years. The Body Mass Index (BMI) is 21.9 kilograms per meter squared. A green strap encircling the left ankle has the inscription "250574." Focal areas of skin slippage on the body indicate the very early stages of putrefactive decomposition.

The black scalp hair is arranged in anteroposteriorly-oriented parallel braids with 7 centimeter free ends at the lower back of the head. Facial hair consists of a mustache and a beard with growth that continues down onto the neck. The brown eyes have cloudy corneas and transverse red to black stripes of postmortem tache noire. The nose has an intact bridge and septum. The ears have no deformities and are not pierced. The atraumatic mouth has natural upper and lower dentition with the two maxillary central incisors absent chronically. The neck has no masses, scars or evidence of recent injury. The symmetrical chest, flat abdomen and the back have no obvious surgical scars. The penis is not circumcised and the testes are intrascrotal. The anus has no abnormalities. The upper and lower extremities have no obvious bony deformities, digital clubbing or palpable fractures.

A transverse tattoo on the right side of the neck reads "In God I Trust." A tattoo on the lateral aspect of the right upper arm is associated with the phrase "Chains can't hold me." A tattoo on the anterior aspect of the right upper arm proximal to the antecubital fossa depicts a mask with steam coming out of the nostrils. Tattoos cover the extensor aspect of the right forearm. Tattoos on the flexor aspect of the right forearm include the letters "M.O.B." A creature reminiscent of the hulk is associated with the word "Aquarius" on the anterolateral deltoid area of the left upper arm. Tattoos on the anterior aspect of the left upper arm include a mask surrounded by question marks. A lion's head on the flexor aspect of the left forearm is associated with the phrase "Fear No Man." The word "COUNTY" is along the ulnar extensor surface of the left forearm. Two cannons facing away from each other on the left upper chest are associated with the number "1804."

MINOR INJURIES:

Abrasions cover a 5 centimeter area on the anterior aspect of the left shoulder. A small abrasion is on the dorsum of the right hand at the base of the thumb and small abrasions are on the right middle finger. The largest of abrasions around the right knee is 4.5 centimeters. The largest of abrasions on the left knee is 4.5 centimeters. A 2 centimeter abrasion is on the top of the right foot.

The scalp has a 4 centimeter left frontal subgaleal ecchymosis.

THE MIAMI-DADE COUNTY MEDICAL EXAMINER DEPARTMENT, MIAMI, FLORIDA**EUGENE, Rudy...May 29, 2012...9:40 A.M. ...Case No. 2012-01252****PENETRATING GUNSHOT WOUND "A" ON LEFT OCCIPITOPARIETAL SCALP:**

"A" is on the left occipitoparietal scalp, 2-1/2 inches superior and 3 inches posterior to the left external auditory meatus, 3-1/2 inches below the top of the head and 1-3/4 inches to the left of the midline. The 9 millimeter round wound has a 1 millimeter abrasion margin; subcutaneous beveling is along the superior edge. Searing, soot deposition, muzzle imprinting and gunpowder stippling are not seen.

The projectile perforates the left side of the calvarium along the left side of the lambdoid suture, lacerates the ventral aspect of the left occipital lobe, perforates the left cerebellar tentorium and dorsal aspect of the left cerebellar hemisphere and terminates in the anterior aspect of the right cerebellar hemisphere. The right side of the pons is lacerated. The deformed mushroomed nose of the medium caliber projectile is recovered from the anterior border of the right cerebellar hemisphere and a deformed medium caliber copper jacket with attached portion of lead core is recovered from the left occipital subgalea, subjacent to the entrance wound.

The projectile path is from back to front, left to right and downward.

The round left calvarial entrance wound is 1.9 x 1.7 centimeters on the outer table of the skull and bevels internally to 2.7 centimeters on the inner table of the skull. The comminuted entrance wound is associated with fractures that extend downwards into the left posterior cranial fossa and a calvarial fracture that extends anteriorly through the left parietal bone and left side of the frontal bone to terminate above the superior border of the right bony orbit. Fractures are in the right orbital plate and anterior aspect of the left orbital plate. The brain is covered by thin subdural ecchymoses and subarachnoid hemorrhage. Small red cortical contusions are on the ventral aspects of the frontal lobes and occipitotemporal regions. Ecchymoses are on the right side of the cervical spinal canal, just caudal to the foramen magnum. Ecchymoses are in the soft tissues between the posterior aspects of C1 and C2. The atlanto-occipital ligaments and cervical spine are intact. The cervical spinal cord is intact.

PENETRATING GUNSHOT WOUND "B" ON LEFT UPPER BACK:

"B" is on the left upper back, 9 inches below the top of the head and 2-3/4 inches to the left of the upper thoracic spine. The 9 millimeter round wound has a 1 millimeter abrasion margin. Searing, soot deposition, muzzle imprinting and gunpowder stippling are not seen.

The projectile perforates the paraspinous aspect of the left third rib and left side of the intervertebral disk between T3 and T4 before penetrating the left side of the esophagus. A deformed mushroomed copper-jacketed medium caliber projectile is recovered from the left posterolateral aspect of the esophagus. The descending thoracic aorta is intact.

The projectile path is from back to front, left to right and downward.

"B" is associated with an expanded, internally lacerated dark red contusion of the left pulmonary apex and a contusion of the superior left lower lobe. Spinal epidural, subdural and subarachnoid ecchymoses cover the softened, focally ecchymotic segment of thoracic spinal cord at the T3 to T4 level.

THE MIAMI-DADE COUNTY MEDICAL EXAMINER DEPARTMENT, MIAMI, FLORIDA

EUGENE, Rudy...May 29, 2012...9:40 A.M. ...Case No. 2012-01252

A left paraspinal parietal subpleural hematoma becomes confluent with the paraspinal hematoma from gunshot wound "D." "B" contributes to a 200 milliliter left hemothorax.

PENETRATING GUNSHOT WOUND "C" ON RIGHT UPPER BACK:

"C" is on the right upper back, 11 inches below the top of the head and 1-3/4 inches to the right of the upper thoracic spine. The 9 millimeter round wound has a 1 millimeter abrasion margin. Searing, soot deposition, muzzle imprinting and gunpowder stippling are not seen.

The projectile perforates the posterior aspect of the right fourth rib and the right upper lobe of lung (additionally lacerating the posterior inferior aspect of the right middle lobe of lung) before penetrating the inferior border of the right sixth rib anterolaterally. A deformed mushroomed copper-jacketed medium caliber projectile is recovered from the anterolateral aspect of the right sixth rib, 20-1/4 inches below the top of the head and 4-3/4 inches to the right of the midline. A centrally abraded purple ecchymosis overlies the projectile.

The projectile path is from back to front, left to right and downward.

"C" contributes to a 250 milliliter right hemothorax.

PENETRATING GUNSHOT WOUND "D" ON LEFT UPPER BACK:

"D" is on the left upper back, 13 inches below the top of the head and 1 inch to the left of the thoracic spine. The 9 millimeter round wound has a 1 millimeter abrasion margin. Searing, soot deposition, muzzle imprinting and gunpowder stippling are not seen.

The projectile tunnels through the soft tissues of the back and penetrates the left side of T8 vertebral body. A deformed copper-jacketed medium caliber projectile is recovered from the left side of T8 vertebra.

The projectile path is from back to front, downward and slightly left to right.

Gunshot wound "D" results in a left paraspinal parietal subpleural hematoma that becomes confluent with the paraspinal hematoma from gunshot wound "B." Spinal epidural, subdural and subarachnoid ecchymoses overlie the corresponding softened and ecchymotic segment of the thoracic spinal cord. "D" contributes to a 200 milliliter left hemothorax.

PENETRATING GUNSHOT WOUND "E" ON RIGHT MID BACK:

"E" is on the right mid back, 14 inches below the top of the head and 5/8 inch to the right of the thoracic spine. The 9 millimeter round wound has a 1 millimeter abrasion margin. Searing, soot deposition, muzzle imprinting and gunpowder stippling are not seen.

The projectile perforates the posterior aspects of the right eighth and ninth ribs, the right lower lobe of lung and right leaflet of the diaphragm, lacerates the diaphragmatic surface of the right lobe of liver, perforates the right leaflet of the diaphragm again and lacerates the anterior inferior aspect of the

THE MIAMI-DADE COUNTY MEDICAL EXAMINER DEPARTMENT, MIAMI, FLORIDA**EUGENE, Rudy...May 29, 2012...9:40 A.M. ...Case No. 2012-01252**

right lower lobe of lung before penetrating the right chest wall. A deformed mushroomed copper-jacketed medium caliber projectile is recovered from the anterior aspect of the right seventh intercostal space.

The projectile path is from back to front, downward and slightly left to right.

"E" contributes to a 250 milliliter right hemothorax. A fragment of copper jacketing recovered from the right pleural cavity may be associated with gunshot wound "E" or with gunshot wound "C." Small amounts of extravasated blood surround the lacerated right lobe of the liver.

PENETRATING GUNSHOT WOUND "F" ON ANTERIOR RIGHT THIGH:

"F" is on the proximal anterior aspect of the right thigh, 33 inches above the right heel. The 2 centimeter irregular wound has a tapered 1.5 centimeter abrasion at the 11 o'clock position. Searing, soot deposition, muzzle imprinting and gunpowder stippling are not seen.

The projectile tunnels through the soft tissues and muscles of the right thigh, passing from front to back, right to left and downward. A deformed mushroomed copper-jacketed medium caliber projectile is recovered from the muscles on the medial aspect of the right thigh, 28-1/2 inches above the right heel.

INTERNAL EXAMINATION:

The pachymeninges have no masses. The 1410 gram brain is covered by smooth translucent leptomeninges and the described subdural and subarachnoid hemorrhage. The cerebrum, cerebellum and brainstem have no intraparenchymal cysts, abscesses, masses or focal areas of discoloration apart from ecchymoses associated with gunshot wound "A." The mammillary bodies are not shrunken or discolored and the dorsal cerebellar vermis is not atrophic. The hippocampi are symmetrical apart from contusions associated with gunshot wound "A." The thin-walled arteries at the base of the brain have no inherent abnormalities.

The tongue has no bite marks, lacerations, intramuscular ecchymoses or masses. The hyoid bone and thyroid cartilage are intact. A film of blood coats the mucosa of the larynx, trachea and mainstem bronchi. The 320 gram right lung and 440 gram left lung have smooth pink-tan pleural surfaces with moderate black anthracotic pigmentation. The cut surfaces of both lungs have multiple small foci of dark gray interstitial anthracosis. Granulomata and masses are not visible or palpable in either lung. The pulmonary arteries are patent, with no thromboemboli. The small hilar lymph nodes are soft and black. The left lung is boggy, whereas the right lung is collapsed. The pleural cavities have no fibrous adhesions or pleural plaques.

The smooth intact pericardial sac contains 5 milliliters of pale red fluid. The 320 gram heart has smooth epicardial surfaces. The four cardiac chambers do not contain mural thrombi or thromboemboli. The fossa ovalis is fused. The four thin pliable cardiac valves have no deformities or vegetations. The mural endocardium is thin, smooth and translucent. The red-brown myocardium has no fibrosis, yellow necrosis, erythema or areas of accentuated softening or induration. The ostia of the left main and right coronary arteries are patent and positioned normally. The right coronary artery becomes the posterior descending artery. All coronary arteries are thin-walled and patent throughout. The thin elastic aorta has slight yellow fatty streaking of the intima.

THE MIAMI-DADE COUNTY MEDICAL EXAMINER DEPARTMENT, MIAMI, FLORIDA**EUGENE, Rudy...May 29, 2012...9:40 A.M. ...Case No. 2012-01252**

The esophagus, stomach and duodenum have no ulcers or masses. The stomach contains approximately 185 milliliters of watery turbid tan-red fluid that includes a fine, pale sediment. The small bowel, vermiform appendix, colon and rectum have no abnormalities externally. The subcutaneous fat of the anterior abdominal wall is 2.3 centimeters thick.

The 1000 gram liver has a thin smooth capsule with the described laceration associated with gunshot wound "E." The homogeneous brown-red hepatic parenchyma has no nodules or masses. The gallbladder contains 20 milliliters of brown-orange bile and no calculi. The portal tract structures have no abnormalities. The pale tan lobulated pancreas has no ecchymoses, pseudocysts, masses, calcification or chalky yellow deposits.

The 95 gram right kidney and 80 gram left kidney have smooth tan-purple cortical surfaces. The cut surfaces of the kidneys, and the renal calyces, pelves and ureters have no abnormalities. The renal vessels are intact and patent. The bladder contains 3 milliliters of pale yellow urine. The pale beige prostate is not enlarged and has no nodules. The tan testes have no ecchymoses or masses.

The 50 gram spleen has a thin smooth capsule. The purple-red splenic parenchyma has small follicles of white pulp. Lymphadenopathy is not evident in the body cavities.

The pituitary, tan thyroid and yellow adrenals have no abnormalities.

The thoracolumbar spine has no abnormal curvatures or osteophytic lipping. The left and right clavicles and ribs have no obvious calluses and no fractures apart from those associated with gunshot wounds "B", "C" and "E." The sternum is intact. The pelvis has no palpable fractures.

AUTOPSY FINDINGS:

1. Penetrating gunshot wound "A" on left occipitoparietal scalp:
 - a. Perforation of skull and brain.
 - b. Calvarial and basal skull fractures.
 - c. Subdural and subarachnoid hemorrhage and cerebral cortical contusions.
 - d. Recovery of portions of copper-jacketed medium caliber projectile from left occipital scalp and right cerebellar hemisphere.
2. Penetrating gunshot wound "B" on left upper back:
 - a. Perforation of left third rib, contusion of left upper lobe of lung, perforation of intervertebral disk between T3 and T4 and penetration of esophagus.
 - b. Recovery of copper-jacketed medium caliber projectile from esophageal wall.
 - c. Spinal epidural, subdural and subarachnoid ecchymoses and softening and ecchymoses of thoracic spinal cord.
 - d. Contribution to left paraspinal hematoma and left hemothorax.
3. Penetrating gunshot wound "C" on right upper back:
 - a. Perforation of right fourth rib and right upper lobe of lung.
 - b. Recovery of copper-jacketed medium caliber projectile from fractured right sixth rib.

THE MIAMI-DADE COUNTY MEDICAL EXAMINER DEPARTMENT, MIAMI, FLORIDA

EUGENE, Rudy...May 29, 2012...9:40 A.M. ...Case No. 2012-01252

- c. Contribution to right hemothorax.
4. Penetrating gunshot wound "D" on left upper back:
 - a. Recovery of copper-jacketed medium caliber projectile from left side of T8 vertebra.
 - b. Spinal epidural, subdural and subarachnoid ecchymoses and softening and ecchymoses of thoracic spinal cord.
 - c. Contribution to left paraspinal hematoma and left hemothorax.
5. Penetrating gunshot wound "E" on right mid back:
 - a. Perforation of right eighth and ninth ribs, right lower lobe of lung, right leaflet of diaphragm and diaphragmatic surface of right lobe of liver.
 - b. Recovery of copper-jacketed medium caliber projectile from right seventh intercostal space.
 - c. Contribution to right hemothorax.
6. Penetrating gunshot wound "F" on right thigh:
 - a. Recovery of copper-jacketed medium caliber projectile from medial aspect of right thigh.
7. Pulmonary anthracosis.


TISSUES SUBMITTED FOR HISTOLOGY:

Tissues submitted for histology include hippocampus, cerebellum, heart, lung, liver and kidney.



**Emma O. Lew, M.D.
Deputy Chief Medical Examiner**

EOL



**MIAMI-DADE COUNTY
MEDICAL EXAMINER DEPARTMENT**

Number One on Bob Hope Road
Miami, FL 33136
Phone (305) 545-2400 Fax (305) 545-2439



MICROSCOPIC REPORT

EUGENE, Rudy

Case No. 2012-01252

- HIPPOCAMPUS:** Some very faint-staining neurons
Suggestion of possible neuritic plaques on H & E section
No meningitis, cerebritis or neoplasia
- CEREBELLUM:** Subarachnoid hemorrhage and ecchymoses in white matter
Focal Purkinje cell dropout and early hyper eosinophilia of
some remaining Purkinje cells
- HEART:** Mild perivascular fibrosis
No inflammation or evidence of acute infarction
- LUNG:** No pneumonia, pneumonitis or refractile foreign material
- LIVER:** No pathological abnormalities
- KIDNEY:** Single sclerosed glomerulus
Autolytic changes

**Emma O. Lew, M.D.
Deputy Chief Medical Examiner**



Miami-Dade County
Medical Examiner Department
 Number One on Bob Hope Road
 Miami, FL 33136
 Phone (305) 545-2400 Fax (305) 545-2418

**TOXICOLOGY REPORT**

September 04, 2018

ME Case # 2012-01252

Decedents Name: EUGENE, Rudy

SUBSTANCE	SPECIMEN	RESULT	METHOD
5-FLUORC-ADB	Blood - Iliac Vein	UNDETECTED	Analysis performed by UM Toxicology Laboratory, Miami, FL Ref Lab
5-FLUORC-ADB METABOLITE #7	Blood - Iliac Vein	UNDETECTED	Analysis performed by UM Toxicology Laboratory, Miami, FL Ref Lab

Reviewed By:

Errima O Lew, M.D.
 Chief Medical Examiner
 September 4, 2018 11:02 am

Diane M. Boland Ph.D, F-ABFT
 Toxicology Division Director
 August 31, 2018 2:50 pm

QC by: LZ

Miami-Dade County**Medical Examiner Department**

Number One on Bob Hope Road

Miami, FL 33136

Phone (305) 545-2400 Fax (305) 545-2418

**INVESTIGATIONS REPORT****EUGENE, Rudy**

02/04/1981

31 Years

Black

Male

ME Case #: 2012-01252**Date: 05/26/2012**

710 NW 13th TER , Fort Lauderdale, FL,

Type: ME**Place of Death:** 1300 Block of N. Bayshore DR , Miami, FL 33132**Date/Time of Death:** 05/26/2012 1:56PM**Investigating Agency:** City of Miami Police Department**Agency Contact Person:** Sgt. A. Williams**Agency Case Number:** 120526151711**Incident Location:** 1300 Block of N. Bayshore DR , Miami, FL 33132**Incident Date/Time:** 05/26/2012 1:56PM**Scene Dr.:** Lew, Emma O. MD

TERMINAL EVENT: On May 26, 2012, the deceased was shot by a City of Miami police officer during a confrontation, while the decedent was fighting with another person. The incident occurred in the roadway of the 1300 block of North Bayshore Drive in Miami, Florida. The deceased expired at the terminal event scene and Dr. E. Lew responded.

MEDICAL HISTORY: Per family, the deceased was in good health with no known medical issues.

MEDICATIONS: None

SOCIAL HISTORY: The decedent was born in Miami, Florida, and was a lifetime South Florida resident. He was divorced, did not have children, and was living with his girlfriend at the time of the terminal event. The deceased was unemployed at this time, but when working, he was a car detailer. Per family, he was a non-smoker of cigarettes, a non-drinker of alcohol, but he may have used Marijuana.

IDENTIFICATION: Method: Fingerprints

By: Det. A. Williams

Relationship: Law Enforcement

Cause of Death: Gunshot Wounds

Due To:

Due To:

Due To:

Contributory Cause:**Manner:** Homicide

Autopsy

05/29/2012

Doctor: Lew, Emma O. MD**Mortuary:** Grace Funeral Home Inc**Investigator:** Eichel, Mark

THIS REPORT MAY CONTAIN NON-VERIFIED INFORMATION AND
IS SUBJECT TO CHANGE

01/03/2019

Page 1 of 1



**Miami-Dade County
Medical Examiner Department**

Number One on Bob Hope Road
Miami, FL 33136
Phone (305) 545-2400 Fax (305) 545-2418



CASE NOTES

ME Case #: **2012-01252**Decedent's Name: **EUGENE, Rudy**

Date	Case Note By	Note
5/28/2012 9:45:00AM	Eichel, Mark	Called: Det. A. Williams/MPD 305 603-6350 Message left re: Identification of the deceased.
5/28/2012 9:47:00AM	Eichel, Mark	Rec'd Call: Det. A. Williams/Miami PD 305 603-6350 Sgt. Williams advised the decedent has been identified via fingerprints as: Rudy EUGENE 2/14/1981 Sgt. Williams is attempting to locate NOK and will advise.
5/28/2012 9:47:00AM	Eichel, Mark	Called: Dr. E. Lew 305 545-2400 Dr. Lew was advised of the fingerprint identification of the decedent.
5/28/2012 2:31:00PM	Eichel, Mark	Called: Sgt. A. Williams/Miami PD 305 603-6350 Sgt. Williams was given the following information re: the deceased's NOK: Mother; Ruth Charles 786 281-8077 Cousin: HERN Eugene 954 773-1240 Girlfriend: Kia Cross 305 263-0325



**Miami-Dade County
Medical Examiner Department**

Number One on Bob Hope Road
Miami, FL 33136
Phone (305) 545-2400 Fax (305) 545-2418



CASE NOTES

ME Case #: **2012-01252**

Decedent's Name: **EUGENE, Rudy**

Date	Case Note By	Note
5/28/2012 2:57:00PM	Eichel, Mark	<p>Called: Kia Cross/Girlfriend 305 263-0325</p> <p>Ms. Cross is the decedent's girlfriend. They have had a 5 year on/off relationship. The deceased had been living with her for the previous month in her apartment at 710 Northwest 13th Terrace, Fort Lauderdale, Florida. She gave the following information pre-terminal event: The deceased and Ms. Cross spent most of the day of May 25, 2012, together. She never saw the decedent use any drugs or alcohol during that time. The decedent worked as a car detailer but was not working steadily. On May 26, 2012, at approximately 5:00 AM, the deceased received a phone call from a subject he only identified as his "Homeboy". He got dressed and told Ms. Cross he was leaving. At that time according to Ms. Cross, the decedent was acting strange and unusual. He wanted to borrow her car but she said no. He drove off in his vehicle, a purple 1995 Chevrolet Caprice. The deceased called Ms. Cross at approximately 6:30 AM, advising her that his car had broken down. That was the last conversation she had with the decedent.</p>



**Miami-Dade County
Medical Examiner Department**

Number One on Bob Hope Road
Miami, FL 33136
Phone (305) 545-2400 Fax (305) 545-2418




CASE NOTES

ME Case #: 2012-01252

Decedent's Name: **EUGENE, Rudy**

Date	Case Note By	Note
5/29/2012 10:20:00AM	Eichel, Mark	<p>Called: Marckenson Charles/Brother Ruth Charles/Mother 786 389-3033</p> <p>Deceased born in Miami, Florida Lifetime South Florida resident Divorced No children Living with girlfriend at the time of the terminal event Unemployed car detailer at the time of the terminal event Non-smoker Non-drinker of alcohol Possibly used Marijuana</p> <p>No known medical history</p> <p>This writer had a conference call with the decedent's mother and brother. They advised the terminal event incident was out of character for the deceased. He apparently did have a temper and anger issues at times, but they stressed the deceased had never committed an act of physical violence that they knew of. They both last spoke with him on May 23, 2012, and at that time, there did not appear to be anything out of the ordinary going on. However, the deceased's grandmother called the the decedent's mother that same day and advised her that she needed to speak with the deceased as something was wrong. However, there was no further elaboration on that point.</p>
5/30/2012 9:17:00AM	Tyler-Luke, Sharmaine	<p>05/30/12 09:17:00, Case Note Entered By: Tyler-Luke, Sharmaine</p> <p>I called Grace Funeral Home (305-688-6388): I spoke with Vanessa and advised there is a hold on the decedent's body, but Dr. Lew wanted to know when the services were scheduled. Vanessa advised the funeral was scheduled for Saturday, June 9, 2012.</p>
5/30/2012 4:23:00PM	Tyler-Luke, Sharmaine	<p>In office, Dr. Lew advised to call Dr. Silver and request an odontal work-up on the deceased.</p>
5/30/2012 4:25:00PM	Tyler-Luke, Sharmaine	<p>I called Dr. Silver and advised Dr. Lew requested an odontal work-up. I then placed them in a conference call together. Dr. Silver advised he will be in the office tomorrow, but will need to call back with a time frame.</p>
5/30/2012 5:14:00PM	Tyler-Luke, Sharmaine	<p>In office, Investigator Boyd advised Dr. Silver called and advised he will be at the ME Dept. about 10:00am on May 31, 2012.</p>



**Miami-Dade County
Medical Examiner Department**

Number One on Bob Hope Road
Miami, FL 33136
Phone (305) 545-2400 Fax (305) 545-2418



CASE NOTES

ME Case #: **2012-01252**Decedent's Name: **EUGENE, Rudy**

Date	Case Note By	Note
5/30/2012 5:15:00PM	Tyler-Luke, Sharmaine	In office, I advised Len Sumlar-Morgue Manager that Dr. Silver will be here about 10:00am, May 31, 2012 to perform the dental examination.
5/31/2012 2:02:00PM	Tyler-Luke, Sharmaine	In office, Dr. Lew wanted to confirm molds or casts of the decedent's teeth were done before she releases the hold on his remains. I advised I would call Dr. Silver and confirm.
5/31/2012 2:03:00PM	Tyler-Luke, Sharmaine	I called Dr. Silver and he advised he took impressions of the decedent's upper and lower teeth and the molds are being made.
5/31/2012 2:06:00PM	Tyler-Luke, Sharmaine	In office, I advised Dr. Lew, I spoke with Dr. Silver took impressions of the decedent's upper and lower teeth and the molds are being made.
6/27/2012 4:08:00PM	Eichel, Mark	Called: Marckenson Charles/Brother 786 389-3033 Mr. Charles is the decedent's brother. The NOK (mother) was at work and unreachable by phone. Mr. Charles was advised of the deceased's tox results (Marijuana) and he will notify his mother when she finishes work and returns home.



CASE Number:2012-01252

VERIFICATION OF DEATH

Deceased: EUGENE, Rudy **Age: 31 Years** **Race: Black** **Gender: Male**

710 NW 13th TER , Fort Lauderdale, FL,

PLACE OF DEATH: 1300 Block of N. Bayshore DR , Miami, FL 33132 **DATE:05/26/2012**

Date and Time of Death:26-May-2012 1:56 pm **TYPE:ME**

Found, Occured or Pronounced:

Incident Location: 1300 Block of N. Bayshore DR , Miami, FL 33132

Incident Date / Time: 5/26/2012 1:56:00PM

An: Autopsy **Was performed**05/29/2012 **By: Lew, Emma O. MD**
Medical Examiner

Cause of Death:Gunshot Wounds

Contributory Cause:

On the basis of investigation the probable manner of death: Homicide

I hereby certify this to be a true copy of verification of death as established by the medical examiner

FORENSICS RECORDS BUREAU