

12**AUTOPSY REPORT**No. 2020-05405
GUARDADO PINEDA,
ANDRES F

I performed an autopsy on the body of



at THE DEPARTMENT OF CORONER

Los Angeles, California

on June 22, 2020 1515

(Date)

(Time)

From the anatomic findings and pertinent history I ascribe the death to:

(A) Multiple gunshot wounds

DUE TO OR AS A CONSEQUENCE OF

(B)

DUE TO OR AS A CONSEQUENCE OF

(C)

MANNER OF DEATH

Homicide

HOW INJURY OCCURRED:

With handgun

Anatomical Summary:Summary:

- 5 total gunshot wounds, all entering the back.
- An additional 2 graze wounds are present on the forearms along with other secondary fragment wounds detailed below
- All 5 gunshot wounds are fatal
- 500 cc right and 600 cc left hemothorax.
- 250 cc clotted hemopericardium.
- 150 cc hemoperitoneum (around the liver).
- All bullets travel back to front and slightly upwards through the torso except gunshot wound #1 which is slightly downwards.
- 3 mushroomed jacketed medium caliber bullets are recovered and submitted to evidence. A bullet fragment was also recovered from the abdomen at the scene.
- Soot, stippling, searing, or muzzle stamp was not seen on any of the gunshot wounds.
- All the entrance wounds are ¼" round with abrasion collar.
- For purposes of identification and convenience, injuries are arbitrarily numbered and this is not an opinion as to the order in which these wounds were sustained.

Gunshot wound #1

- Enters the left upper back, 8" below top of shoulder, 2 ¼" left of midline.
- Bullet perforates the:
 - o Left 7th intercostal space at the costovertebral angle,
 - o Thoracic aorta,

12**AUTOPSY REPORT**No. 2020-05405
GUARDADO PINEDA,
ANDRES FPage 2

- o Left lower lung,
- o Distal esophagus,
- o Heart (left posterior atrium, interventricular septum, right atrium and tricuspid valve, right anterior ventricle),
- o and ricochets off the inner sternum.
- Bullet recovered from between the sternum and heart, at midline of the body, about 10" below top of shoulder.
- Direction is back to front and down.

Gunshot wound #2

- Enters the right upper back, 6" below top of shoulder, 4 ¼" right of midline.
- Bullet perforates the:
 - o Right posterior 3rd intercostal space
 - o Apex of right upper lung
 - o Lateral 1st intercostal space
- Bullet exits just under the right clavicle, 3 ½" below top of shoulder, 3 ¼" right of midline. ½" irregular round wound, no marginal abrasion.
- Direction is back to front, up

Gunshot wound #3

- Enters the right mid back, 14" below top of shoulder, 1 ½" right of midline.
- Bullet perforates the:
 - o Right posterior 11th rib, fracture
 - o Right lower and upper lung
 - o Right anterior 5th rib, fracture
- Gunshot wounds 3 and 4 end very close together at the right nipple. It is not possible to determine which bullet/exit belongs to which gunshot wound. Thus, gunshot wounds 3 or 4 either:
 - o Exit the right nipple, 9" below top of shoulder, 5" right of midline, or
 - o The bullet is recovered just above the right nipple (overlying ecchymosis present), 8 ½" below top of shoulder, 5 ½" right of midline.

12**AUTOPSY REPORT**No. 2020-05405
GUARDADO PINEDA,
ANDRES FPage 3

- Direction is back to front, up

Gunshot wound #4

- Enters the right mid back, 17 $\frac{3}{4}$ " below top of shoulder, 1" right of midline.
- Bullet perforates the:
 - o Right liver
 - o Diaphragm
 - o Right lower and upper lung
 - o Right anterior 5th rib, fracture
- See gunshot wound #3 for exit/bullet
- Direction is back to front, up

Gunshot wound #5

- Enter the lower mid back, 19 $\frac{1}{2}$ " below top of shoulder, midline.
- Bullet perforates the:
 - o Right L3 vertebral body
 - o Right psoas muscle
 - o Right kidney
 - o Right liver
- Bullet recovered from within the liver
- Direction is back to front, up, slightly left to right.

Graze wounds:

- 1" graze on right anteromedial forearm, centered 4 $\frac{1}{4}$ " proximal to wrist. Unknown direction.
- 1 $\frac{1}{2}$ " graze on left anterior forearm, centered 6" proximal to wrist. Unknown direction

Secondary fragment wounds:

- Left lateral lower chest: 2 x 1 $\frac{1}{4}$ " dried abrasion, 14" below top of shoulder, 5" left of midline.
- Left lateral upper abdomen: $\frac{1}{2}$ x $\frac{1}{4}$ " irregular wound, with wide $\frac{3}{8}$ " superior-lateral abrasion, 15" below top of shoulder, 5" left of midline. This is a superficial wound which penetrates only skin and fat.

12**AUTOPSY REPORT**No. 2020-05405
GUARDADO PINEDA,
ANDRES FPage 4

- o Coroner investigator Darabedyan noted a deformed bullet fragment hanging out of this abdominal wound. She transferred the bullet to Homicide criminalist at the scene.
- About 9 small satellite punctate wounds around the above 2 wounds.
- These are all superficial wounds which do not enter the abdominal cavity

Probable secondary fragment wounds:

- 3/8" superficial cut on the left tricep
- 1/2" partial thickness cut of the left posterior scalp, 2" left of midline, 5" below top of head. There is mild underlying subgaleal hemorrhage.
- There is no abrasion and no bridging tissue of the above 2 cuts.

Forehead abrasions:

- 1/2 x 3/8" abrasion, high left forehead
- 5/8" abrasion, just above the left lateral eyebrow
- 3/8" thin abrasion, on the left eyebrow

Please see separate toxicology report.

CIRCUMSTANCES:

Please see Investigator's Report.

EXTERNAL EXAMINATION:

The body is identified by toe tags and is that of an unembalmed refrigerated hispanic male who appears the reported age of 18 years. The body measures 70 inches, weighs 209 pounds, and is normally developed. Hydration and nutritional status are grossly normal. Examination of the skin reveals no evidence of jaundice. Scars: small light scar on left eyebrow. Tattoos: None. Rigor mortis is moderate. Livor mortis is fixed and posterior.

12

AUTOPSY REPORT

No. 2020-05405
GUARDADO PINEDA,
ANDRES F

Page 5

The head is normal in size and shape. The scalp hair is short and black in color. There is no temporal or vertex balding. Mustache is present. Beard is sparse. Examination of the eyes reveals irides that appear to be brown in color and sclerae that are white. The conjunctivae are not congested. There are no petechial hemorrhages of the conjunctivae of the lids or the sclerae. The oronasal passages are unobstructed. There is no foam in the nares or oral cavity. Upper and lower teeth are present and atraumatic. Frenulae and oral mucosa are intact. No nasal fractures are palpated. Examination of the neck shows no abnormal mobility, fingernail marks, contusions, or abrasions.

There is no chest deformity. There is no increased anterior-posterior diameter. The genitalia are those of an adult male. The external genitalia are without trauma or lesions. Except for gunshot wound-related injuries, the extremities show no abrasions, lacerations, contusions, immersion wrinkling, edema, joint deformity, abnormal mobility, or needle tracks. No long bone fractures are present.

EVIDENCE OF THERAPEUTIC INTERVENTION:

None. Recent needle punctures are absent. There has not been post mortem intervention for organ procurement.

INITIAL INCISION:

The body cavities are entered through the standard coronal incision and the standard Y-shaped incision. No foreign material is present in the mouth, upper airway, and trachea.

NECK:

The neck organs are removed en bloc with the tongue. No lesions are present nor is trauma of the gingiva, lips, or oral mucosa demonstrated. There is no edema of the larynx. Both hyoid bone and larynx are intact and without fractures. No hemorrhage is present in the adjacent throat organs investing fascia, strap muscles, thyroid, or visceral fascia. There are no prevertebral

12**AUTOPSY REPORT**No. 2020-05405
GUARDADO PINEDA,
ANDRES FPage 6

fascial hemorrhages. The tongue when sectioned shows no trauma. No fractures of the cervical vertebrae are present.

SYSTEMIC AND ORGAN REVIEW:

Note: The conditions appearing in the Anatomic Summary and Description of Injuries are not necessarily repeated in the Systemic Review. The systemic review is, in essence, a description of the decedent prior to sustaining injuries. All diagrams and descriptions are made using the standard anatomic position at all times.

MUSCULOSKELETAL SYSTEM:

No abnormalities of the uninjured bony framework or muscles are identified.

CARDIOVASCULAR SYSTEM:

The thoracic and abdominal aorta have no atherosclerosis. There is no tortuosity or widening of the thoracic segment. There is no dilation of the lower abdominal segment. No aneurysm is present. The major branches of the aorta show no abnormality.

The heart weighs 300 grams. It has a normal configuration. The cardiac silhouette is not globular and the myocardium is not flabby. The right ventricle is 0.3 cm, the interventricular septum is 1.2 cm in thickness, and the left ventricle is 1.3 cm in thickness. The chambers are normally developed and are without mural thrombosis. The valves are thin, leafy, and competent. No cardiac valve vegetations are present. Circumferences of the valve rings are within normal limits. There is no endocardial discoloration. There are no infarcts or lesions of the myocardium. There is no abnormality of the apices of the papillary musculature. There are no defects of the septum. The great vessels enter and leave in a normal fashion. The ductus arteriosus cannot be probed. The coronary ostia are patent, located at or below the sinotubular junction and are relatively centrally located within their respective sinuses. The coronary artery distribution is right dominant.

12**AUTOPSY REPORT**No. 2020-05405
GUARDADO PINEDA,
ANDRES FPage 7

Serial sectioning of the coronary arteries show no atherosclerosis.

RESPIRATORY SYSTEM:

Scant secretions are found in the upper respiratory and lower bronchial passages. No froth or soot is present in the upper or lower airway. The mucosa is intact and pale. The lungs are collapsed. The right lung weighs 275 grams and the left lung weighs 275 grams. The visceral pleurae are smooth. The pulmonary vasculature is without thromboembolism. There is no evidence of pulmonary infarction.

GASTROINTESTINAL SYSTEM:

The esophagus is unremarkable. Esophageal varices are not present. The stomach and mucosa are unremarkable. The small intestine and colon are unremarkable. The appendix is present and normal. The pancreas occupies a normal position. There is no necrosis or trauma. There is no evidence of pancreatic fibrosis or of pancreatitis.

HEPATOBIILIARY SYSTEM:

The liver weighs 1680 grams, is of average size, and is red-brown in color. The consistency of the parenchyma is firm. The cut surface is smooth. There is no evidence of cirrhosis. There is a normal lobular arrangement. The gallbladder is present. The wall is thin and pliable. It contains a small amount of bile and no calculi.

URINARY SYSTEM:

The right kidney weighs 130 grams and the left kidney weighs 125 grams. The kidneys are normally situated and the capsules strip easily revealing a surface that is smooth and glistening. The corticomedullary demarcation is preserved. The pyramids are not remarkable. The peripelvic fat is not increased. The ureters are without dilation or obstruction and pursue their normal course. The urinary bladder is unremarkable. It contains approximately 50 cc of clear, yellow urine.

12**AUTOPSY REPORT**No. 2020-05405
GUARDADO PINEDA,
ANDRES FPage 8**GENITAL SYSTEM:**

The prostate is without enlargement or nodularity. Both testes are in the scrotum and are unremarkable and without trauma.

HEMOLYMPHATIC SYSTEM:

The spleen weighs 90 grams and is of average size. The capsule is intact. The parenchyma is dark red and soft. There is no increased follicular pattern. Lymph nodes throughout the body are small and inconspicuous. The bone is not remarkable. The bone marrow of the rib is unremarkable.

ENDOCRINE SYSTEM:

The thyroid, adrenal, and pituitary glands are unremarkable. The parathyroid glands are not identified. The thymus is the usual appearance for the age.

SPECIAL SENSES:

The eyes are not dissected. The middle and inner ear are not dissected.

HEAD AND CENTRAL NERVOUS SYSTEM:

There is no subcutaneous, subgaleal, or subperiosteal hemorrhage in the scalp, except as described in injuries. The external periosteum and dura mater are stripped showing no fractures of the calvarium or base of the skull. There are no tears of the dura mater. There is no epidural, subdural or subarachnoid hemorrhage.

The brain weighs 1400 grams. The leptomeninges are thin and transparent. A normal convolutionary pattern is observed. Coronal sectioning demonstrates a uniformity of cortical gray thickness. The cerebral hemispheres are symmetrical. There is no softening, discoloration, or hemorrhage of the white matter. The basal ganglia are intact. Cerebral contusions are not present. The ventricular system has a normal appearance without dilation or distortion. Pons, medulla, and cerebellum are unremarkable. There is no evidence of uncal or cerebellar herniation. Vessels at the base of the brain have a normal

12**AUTOPSY REPORT**No. 2020-05405
GUARDADO PINEDA,
ANDRES FPage 9

pattern of distribution. There are no aneurysms. The cerebral arteries are without arteriosclerosis.

EVIDENCE COLLECTION:

3 bullets are recovered from the decedent, each placed separately in small labeled envelopes and sealed. The small envelopes are all placed in 1 large labeled envelope, sealed with evidence tape, signed and dated across the seal, and placed in evidence drop box.

HISTOLOGIC SECTIONS:

Representative sections from various organs are preserved in one storage jar.

TOXICOLOGY:

Samples of chest blood, liver, urine, and vitreous are submitted to the laboratory for comprehensive screen. An EDTA tube is collected for DNA.

SPECIAL PROCEDURES:

Metal rods are placed through the posterior back wounds after the autopsy to help visualize trajectories. Photos taken. These rods show only approximate trajectories/angles since the body has been opened, organs removed, the rods were only able to be placed through the posterior body wounds, and the body may not have been straight/flat during the event. There are no anterior anchor points for the rods since the body was opened for autopsy.

PHOTOGRAPHY:

At scene photos are available. Photographs have been taken prior to the course of the autopsy and also of the trajectory rods.

RADIOLOGY:

7 x-rays are taken and show the bullets described above.

12**AUTOPSY REPORT**No. 2020-05405
GUARDADO PINEDA,
ANDRES FPage 10**WITNESSES TO AUTOPSY:**

Detectives Davis and Valencia, LASD.
Inspector General Max Huntsman.

DIAGRAMS USED:

Diagram forms #20D, 20, 20, 22 were used during the performance of the autopsy. Coroner diagrams are not intended to be facsimiles nor are they drawn to scale.

OPINION:

The following injuries are present:

- 5 gunshot wounds entering the back, all fatal
- A graze wound on each forearm
- Secondary fragment wounds on the left chest/abdomen
- Probable secondary fragments wounds on the left arm and back of head
- Abrasions on the forehead

The cause of death is multiple gunshot wounds. The range of fire is unknown by autopsy. The manner of death is homicide.



Kevin Young, M.D.
Deputy Medical Examiner

Date

20_D

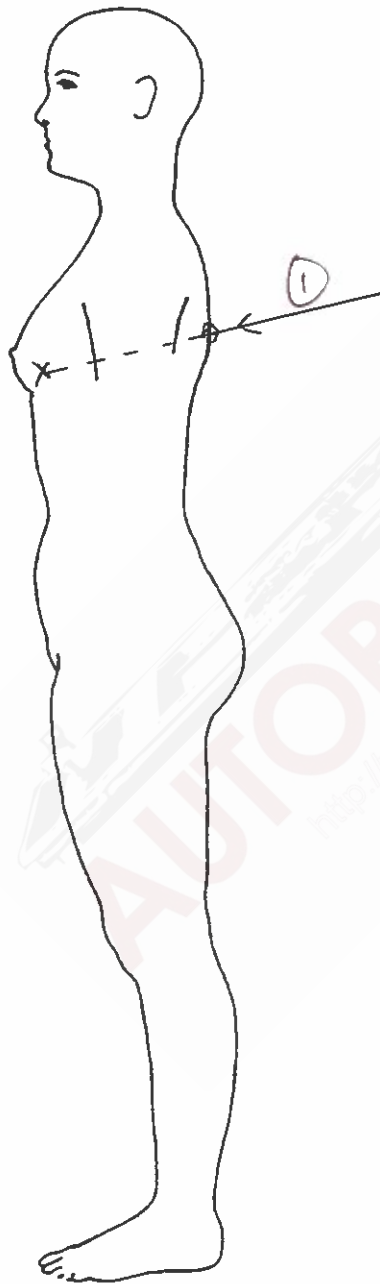
1/4

GSWs 1-5
X = Bullet

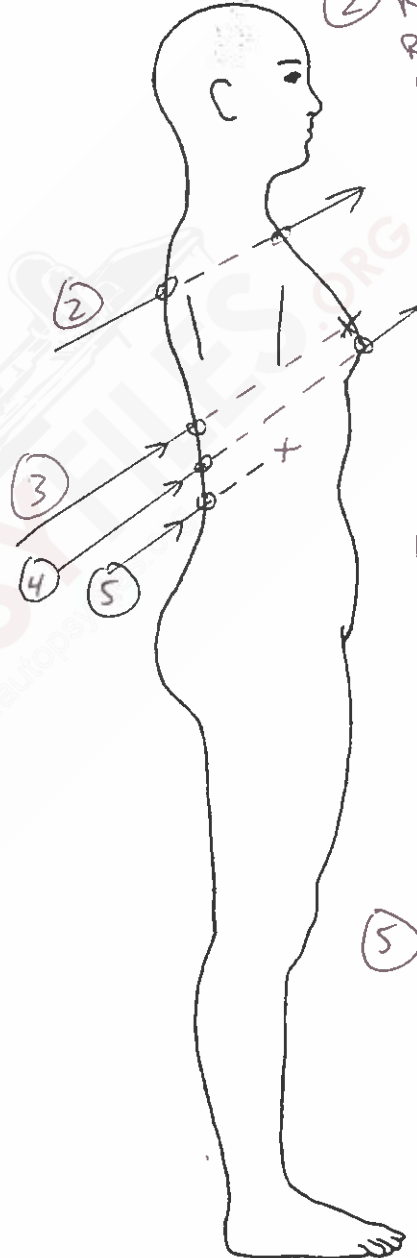
2020-05405

GUARDADO PINEDA, ANDRES P
HOMI 195

- ① L 7th ICS
Aorta
LLL
Esophagus
Heart
X = Bullet
BF, Down



- ② R 3rd ICS
RUL
1st ICS
BF, UP
- ③ 11th rib
RLL
RUL
5th rib
Bullet/exits
BF, UP
- ④ R Liver
Diaphragm
RLL
RUL
5th rib
BF, UP
Bullet/exits
- ⑤ R L3 vert body
Psoas
R Kidney
R Liver
X = Bullet
BF, UP, LR



Date JUN 22 2020 JUN 22 2020

Kevin Young, MD

Deputy Medical Examiner.

M.D.

20

2/4

GSW, 1-5

2020-05405

GUARDADO PINEDA, ANDRES

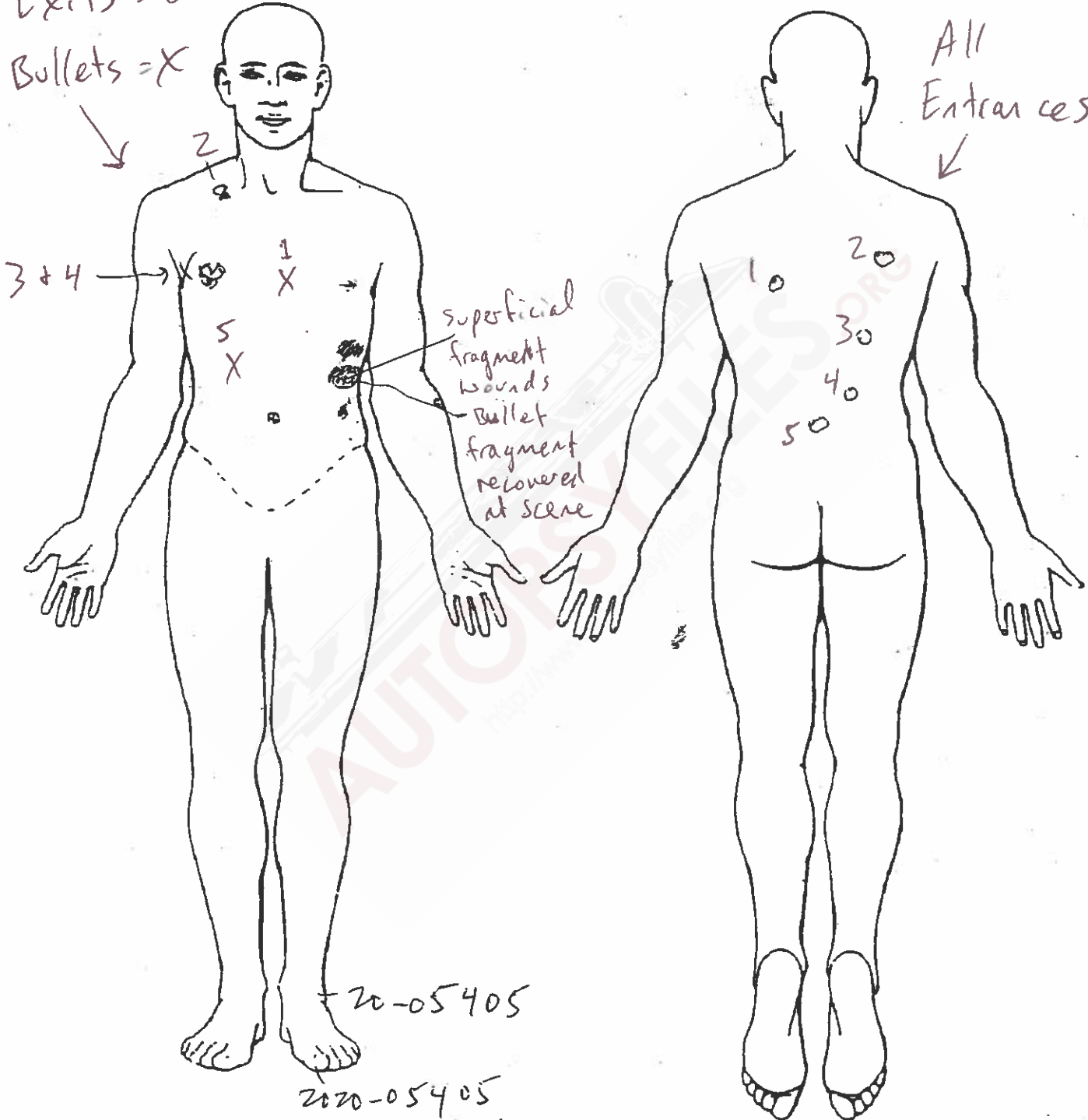
HOMI

195

Exits = 0

Bullets = X

All
Entrances



20-05405
2020-05405
Guardado-pineda,
Andres E

Date JUN 22 2020

Kevin Young, M.D.

M.D.

Deputy Medical Examiner

COUNTY OF LOS ANGELES

DEPARTMENT OF MEDICAL EXAMINER-CORONER

20

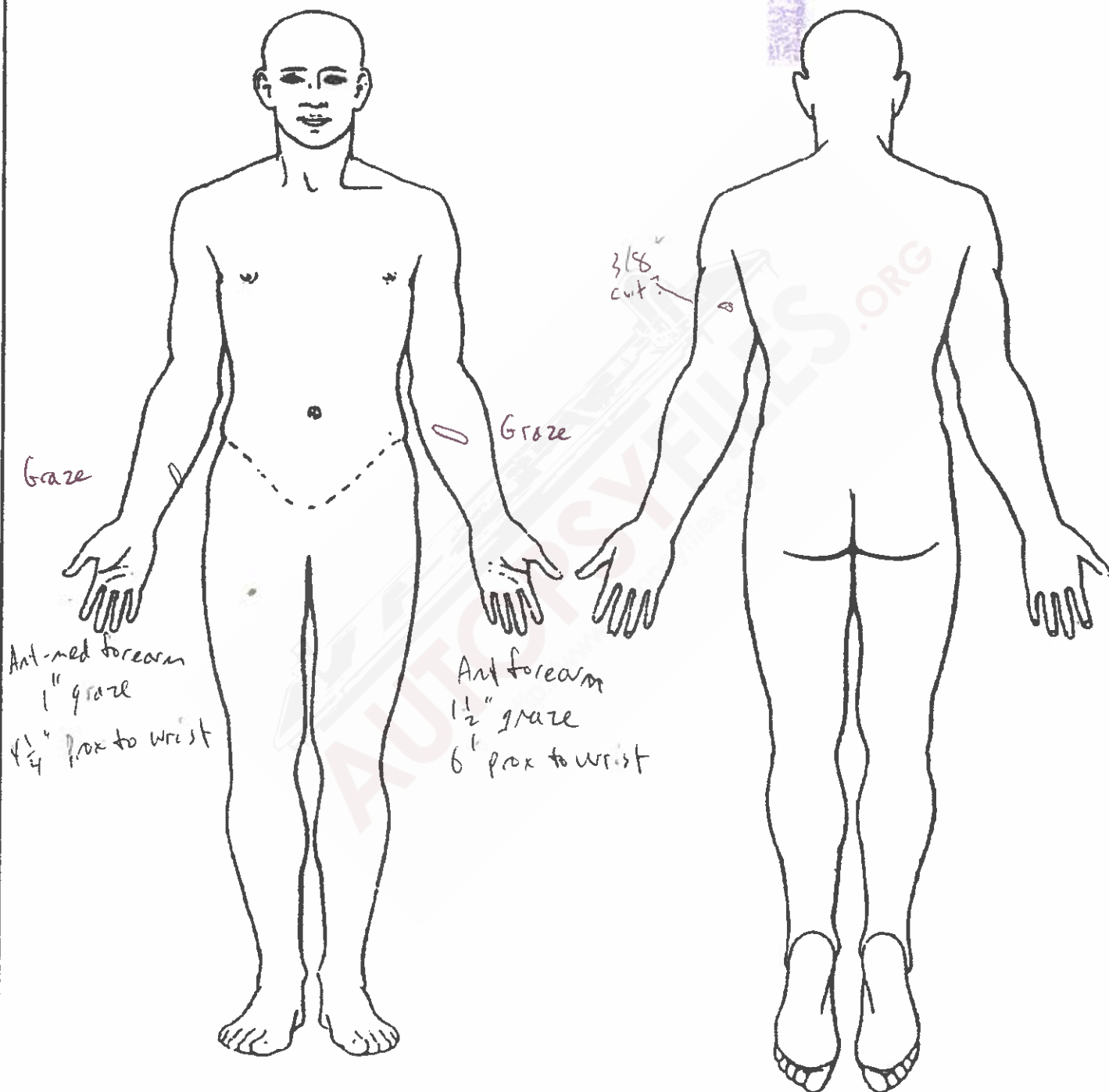
3/4

2020-05405

GUARDADO PINEDA, ANDRES F

HOMI

195



Right Thumbprint

Date JUN 22 2020

Kevin Young, MD

M.D.

Deputy Medical Examiner

22

4/4

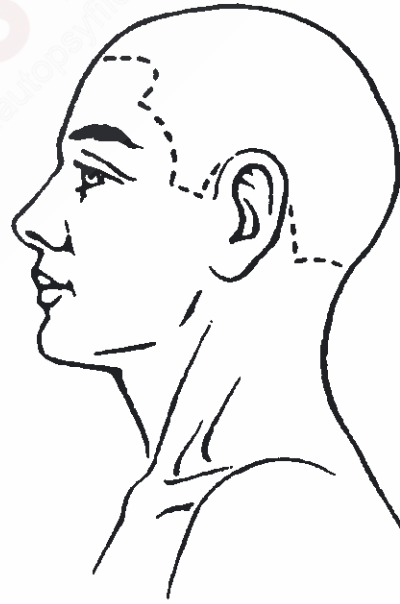
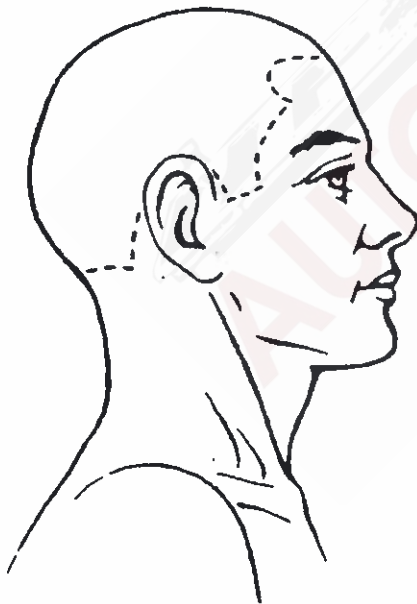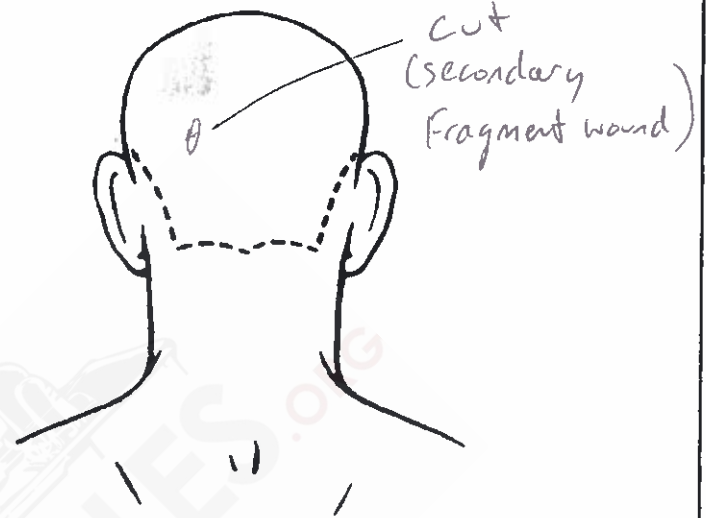
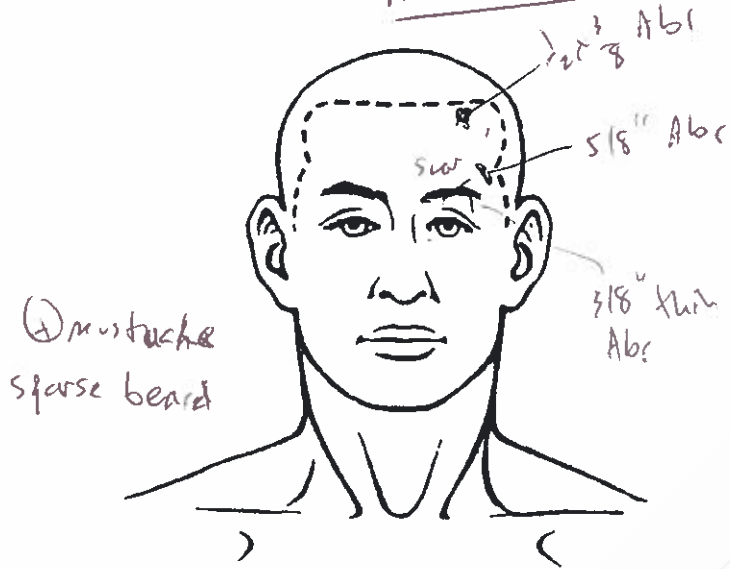
2020-05405

GUARDADO PINEDA, ANDRES F

HOMI

195

Abrasions



Date JUN 22 2020

Kevin Young, MD

Deputy Medical Examiner

M.D.

MEDICAL REPORT

15

AUTOPSY CLASS: ☒ A ☐ B ☐ C ☐ Examination Only D☐ FAMILY OBJECTION TO AUTOPSYDate: 6/22/20 Time: 1515 Dr. Young
(Print)FINAL ON: 6/22/20 By: Young
(Print)APPROXIMATE
INTERVAL
BETWEEN
ONSET
AND
DEATH

2020-05405

GUARDADO PINEDA, ANDRES F

HOMI

195

DEATH WAS CAUSED BY: (Enter only one cause per line for A, B, C, and D)

IMMEDIATE CAUSE:

(A) Multiple gunshot wounds

DUE TO, OR AS A CONSEQUENCE OF:

(B)

DUE TO, OR AS A CONSEQUENCE OF:

(C)

DUE TO, OR AS A CONSEQUENCE OF:

(D)

OTHER CONDITIONS CONTRIBUTING BUT NOT RELATED TO THE IMMEDIATE CAUSE OF DEATH:

☐ NATURAL ☐ SUICIDE ☒ HOMICIDE
☐ ACCIDENT ☐ COULD NOT BE DETERMINEDIf other than natural causes,
HOW DID INJURY OCCUR?

with handgun

WAS OPERATION PERFORMED FOR ANY CONDITION STATED ABOVE: ☐ YES ☒ NO

TYPE OF SURGERY: _____ DATE: _____

☐ ORGAN PROCUREMENT ☐ TECHNICIAN: ted
PREGNANCY IN LAST YEAR ☐ YES ☐ NO ☐ UNK ☐ NOT APPLICABLE☒ WITNESS TO AUTOPSY ☒ EVIDENCE RECOVERED AT AUTOPSY
Item Description: 3 bullets

3

RESIDENT

DME

Age: 18 Gender: Male / Female

PRIOR EXAMINATION REVIEW BY DME

☒ BODY TAG ☐ CLOTHING
☒ X-RAY (No. 7) ☐ FLUORO
☐ SPECIAL PROCESSING TAG ☐ MED. RECORDS
☐ AT SCENE PHOTOS (No. _____)

CASE CIRCUMSTANCES

☐ EMBALMED
☐ DECOMPOSED
☐ >24 HRS IN HOSPITAL
☐ OTHER: _____ (Reason)

TYPING SPECIMEN

TYPING SPECIMEN TAKEN BY: ky
SOURCE: Heart

TOXICOLOGY SPECIMEN

COLLECTED BY: AY
☐ HEART BLOOD ☐ STOMACH CONTENTS
☐ FEMORAL BLOOD ☒ VITREOUSTECHNIQUE
☒ Urine ☐ BLOOD ☐ SPLEEN
☐ BILE ☐ BLOOD ☐ KIDNEY
☒ LIVER ☐
☒ URINE ☐

URINE GLUCOSE DIPSTICK RESULT: 4+ 3+ 2+ 1+ 0

TOX SPECIMEN RECONCILIATION BY: _____

HISTOLOGY

☒ Regular (No. 1) ☐ Oversize (No. _____)
Histopath Cut: ☐ Autopsy ☐ Lab

TOXICOLOGY REQUESTS

FORM 3A: ☐ YES ☐ NO
☐ NO TOXICOLOGY REQUESTED
SCREEN ☒ C ☐ H ☐ T ☐ S ☐ D
☐ ALCOHOL ONLY
☐ CARBON MONOXIDE
☐ OTHER (Specify drug and tissue)

REQUESTED MATERIAL ON PENDING CASES

☐ POLICE REPORT ☐ MED HISTORY
☐ TOX FOR COD ☐ HISTOLOGY
☐ TOX FOR R/O ☐ INVESTIGATIONS
☐ MICROBIOLOGY ☐ EYE PATH. CONS.
☐ RADIOLOGY CONS.
☐ CONSULT ON: _____
☐ BRAIN SUBMITTED
☐ NEURO CONSULT ☐ DME TO CUT
☐ CRIMINALISTICS
☐ GSR ☐ SEXUAL ASSAULT ☐ OTHER



Department of Medical Examiner-Coroner, County of Los Angeles

FORENSIC SCIENCE LABORATORIES

1104 North Mission Road, Los Angeles, CA 90033

Laboratory Analysis Summary Report

Young, Kevin M.D.Deputy Medical Examiner
1104 North Mission Road
Los Angeles, CA 90033☐ PendingTox**Coroner Case Number:** 2020-05405 **Decedent:** GUARDADO PINEDA, ANDRES F.

<u>SPECIMEN</u>	<u>SERVICE</u>	<u>DRUG</u>	<u>RESULT</u>	<u>ANALYST</u>
-----------------	----------------	-------------	---------------	----------------

Alcohol Quantitation/Confirmation

Blood, Chest

Alcohol-GC/FID-HS	Ethanol	Negative	C Castellino
-------------------	---------	----------	--------------

Drug Screen

Blood, Chest

ELISA-Immunoassay	Benzodiazepines	ND	P. Pfy/Cruz
ELISA-Immunoassay	Cocaine and Metabolites	ND	P. Pfy/Cruz
ELISA-Immunoassay	Fentanyl	ND	P. Pfy/Cruz
ELISA-Immunoassay	Marijuana: 11-nor-Delta-9-Carboxy-THC	ND	P. Pfy/Cruz
ELISA-Immunoassay	Methamphetamine & MDMA	ND	P. Pfy/Cruz
ELISA-Immunoassay	Opiates: Codeine & Morphine	ND	P. Pfy/Cruz
ELISA-Immunoassay	Opiates: Hydrocodone & Hydromorphone	ND	P. Pfy/Cruz
ELISA-Immunoassay	Phencyclidine	ND	P. Pfy/Cruz

Drug Screen/Confirmation

Blood, Chest

Bases-GC/NPD &/or MS	Basic Drugs	ND	R Cabrera
----------------------	-------------	----	-----------

Legend:

g	Grams	ND	Not Detected	SNS	Specimen Not Suitable
g%	Gram Percent	ng/g	Nanograms per Gram	TNP	Test Not Performed
Inc.	Inconclusive	ng/mL	Nanograms per Milliliter	ug	Micrograms
mg	Milligrams	PP	Presumptive Positive	ug/g	Micrograms per Gram
		QNS	Quantity Not Sufficient	ug/mL	Micrograms per Milliliter

The alcohol analysis was performed in accordance to California Code of Regulations "Title 17" compliance by a qualified analyst in the Forensic Toxicology Laboratory, Forensic Laboratories Division, County of Los Angeles Department of Medical Examiner - Coroner.

Enzyme-linked immunosorbent assay (ELISA) provides only a preliminary analytical result that is contingent upon a confirmatory test. A "presumptive positive" (PP) signifies a detection of a drug class and must be confirmed by additional testing for true identification and/or quantitation of specific drug(s) present in the specimen.

Per the Department's Evidence Retention Policy, the blood specimen(s) will be retained for one year (minimum) and all other specimens six months (minimum) from Postmortem Exam.

Final Review By:

[Signature]
Sarah Buxton de Quintana
Supervising Criminalist I

Date:

7/7/20

The above results relate only to the items sampled and tested and have been technically and administratively reviewed and are the opinions and conclusions of the analysts noted. The final review has been certified by the noted Toxicologist to ensure that all standard operating procedures were followed as set by the Forensic Toxicology Laboratory, Forensic Sciences Laboratory Division, County of Los Angeles Department of Medical Examiner-Coroner.

ky 7/9/20

A Young

COUNTY OF LOS ANGELES

CASE REPORT

DEPARTMENT OF CORONER

1	APPARENT MODE	HOMICIDE	CASE NO	2020-05405
	SPECIAL CIRCUMSTANCES		CRYPT	195
	Gunshot Wound, Law Enforcement Related, Media Interest, Victim of Crime, Officer Involved			

LAST, FIRST MIDDLE		AKA		#	
GUARDADO PINEDA, ANDRES F					
ADDRESS		CITY		STATE	ZIP
207 N MARIPOSA AVE APT 103		LOS ANGELES		CA	90004
SEX	RACE	DOB	AGE	HGT	WGT
MALE	HISPANIC/LATINO	11/3/2001	18	70 in.	209 lbs.
EYES	HAIR	TEETH	FACIAL HAIR	ID VIEW	CONDITION
BROWN	BROWN	ALL NATURAL TEETH	MUSTACHE	Yes	FAIR

MARK TYPE	MARK LOCATION	MARK DESCRIPTION
		NONE SEEN



ID METHOD	CALIFORNIA ID CARD				
LA #	MAIN #	CII #	FBI #	MILITARY #	POB

IDENTIFIED BY NAME (PRINT)	RELATIONSHIP	PHONE	DATE	TIME
CA ID IMAGE			6/19/2020	05:38

PLACE OF DEATH / PLACE FOUND	ADDRESS OR LOCATION	CITY	ZIP
DRIVEWAY	420 W. REDONDO BEACH BLVD.	GARDENA	90248

PLACE OF INJURY	AT WORK	DATE	TIME	LOCATION OR ADDRESS	ZIP
DRIVEWAY	No	6/18/2020	17:52	420 W. REDONDO BEACH BLVD., GARDENA, CA	90248

DOD	TIME	FOUND OR PRONOUNCED BY
6/18/2020	18:01	LACOFD ENG.95 CLEMENS

OTHER AGENCY INV. OFFICER	PHONE	REPORT NO.	NOTIFIED BY	NO
LASD HOMICIDE - DET. MIKE DAVIS	(323) 890-5500	020-07557-2871-013		

TRANSPORTED BY	TO	DATE	TIME
JAMES ESTEL	LOS ANGELES FSC	6/19/2020	04:30

FINGERPRINTS?	Yes	CLOTHING	Yes	PAR RPT	No	MORTUARY
MED. EV.	No	INVEST. PHOTO #	0	SEAL TYPE	NOT SEALED	HOSP RPT
PHYS. EV.	Yes	EVIDENCE LOG	Yes	PROPERTY?	Yes	HOSP CHART
SUICIDE NOTE	No	GSR NO		RCPT. NO.	319782	PF NO.

SYNOPSIS
 ACCORDING TO THE REPORTED INFORMATION, ON 06/18/2020 AT 1753 HOURS THE DECEDENT WAS STANDING OUTSIDE ON THE SIDEWALK WHEN A POLICE UNIT DOING PATROL IN THE AREA NOTED THE DECEDENT TO HAVE A WEAPON IN HIS WAISTBAND. THE POLICE TRIED TO MAKE A STOP AND THE DECEDENT TOOK OFF RUNNING SOUTHBOUND DOWN THE DRIVEWAY OF A BUSINESS SHOP. OFFICERS TOLD DECEDENT TO GET DOWN AND TO NOT REACH FOR HIS WEAPON. THE DECEDENT REACHED TO HIS WAISTBAND AND OFFICERS SHOT AT THE DECEDENT. PARAMEDICS FROM LOS ANGELES COUNTY FIRE DEPARTMENT ENG. 95 ARRIVED ON SCENE. PARAMEDICS CLEMENS DETERMINED DEATH ON 06/18/2020 AT 1801 HOURS. THERE WERE 5 APPARENT GUNSHOT WOUNDS NOTED TO HIS BACKSIDE. 3 APPARENT GUNSHOT WOUNDS NOTED TO HIS FRONT TORSO, AND GRAZE WOUNDS NOTED TO HIS FOREARMS AND TORSO. THE POLICE INVESTIGATION IS ONGOING. DETECTIVE MIKE DAVIS FROM LASD HOMICIDE IS REQUESTING A TWO-HOUR NOTIFICATION PRIOR TO THE EXAMINATION. PLEASE SEE CASE NOTES FOR HIS PRIVATE CONTACT INFORMATION.

LIANNA DARABEDYAN	DATE	6/19/2020	REVIEWED BY	DATE
646370	TIME	23:44	6/20/2020	TIME

FORM #3 NARRATIVE TO FOLLOW? ☒



County of Los Angeles, Department of Coroner Investigator's Narrative



Case Number: 2020-05405

Decedent: GUARDADO PINEDA, ANDRES F.

Information Sources:

LASD Homicide, Detective Davis, Report #020-07557-2871-013 (323) 890-5500

Investigation:

On 06/18/200 at 1857 hours, Detective Rodriguez from LASD Homicide made a first call to our office to report an apparent homicidal death of an unknown Hispanic male that was involved in an officer-involved-shooting and had sustained multiple gunshot wounds to his torso.

On 06/19/2020 at 0210 hours, Acting Watch Commander Trini Godoy assigned this case to me. I arrived on scene at 0238 hours and cleared the scene at 0405 hours. Forensic Attendant Estel transported the decedent from the scene to the Forensic Science Center.

The decedent's fingerprint returns yielded no results. Prior to my arrival, Paramedics moved the decedent from a prone position to a supine position. The decedent's California Identification card was removed from this wallet and handed to me by the Detectives at the scene. The Deputy's weapon (an unknown make and model with a 9mm caliber and an unknown serial number) was collected as evidence by the Criminalist on scene. Another weapon was found at the scene (a Smith and Wesson handgun with an unknown caliber and an unknown serial number) that was also collected as evidence by the Criminalist at the scene. The police investigation is ongoing.

Location:

Injury and Death: Driveway, 420 W. Redondo Beach Blvd, Gardena CA 90248.

Informant/Witness Statements:

I spoke with Detective Davis at the scene and he told me the following preliminary information:

The incident occurred on 06/18/2020 at 1752 hours. A police unit was doing patrol in the area and noted the decedent standing outside with another female on the sidewalk. They noted a weapon in the decedent's waistband area. They made a stop, but the decedent took off running southbound between two business shops. The Deputies approached the decedent and instructed the decedent to not touch his weapon. The decedent then reached for his waistband, which then led the Deputies to shoot at the decedent. Afterwards, Paramedics from Los Angeles County Fire Department Eng. 95 arrived on scene. Paramedics Clemens determined death on 06/18/2020 at 1801 hours. A total of 6 casings of 9mm caliber were found at the scene. The police investigation is ongoing.

Scene Description:

The incident took place on a driveway path located at 420 West Redondo Beach Boulevard in Gardena. The decedent was seen lying supine on the ground. Located north and east of the decedent is the back area of an auto body shop with parked vehicles and mechanic supplies. Located west of the decedent is the wall of another business building. Located south of the decedent is the continuous driveway out to the sidewalk and then West Redondo Beach Boulevard. Located a few feet east of the decedent is a casing. Located a few feet southeast of the decedent are three more casings. Located by the decedent's head is a wallet, a set of keys, and a cellphone. Located a few inches north of the decedent's head and torso is a large pool of blood, a cut shirt, a face mask, and another casing. Located a few feet west of the decedent is a weapon (a Smith and Wesson handgun with an unknown caliber and an unknown serial number) that was lying on its left side. The front of the weapon was facing north and the end was facing south. Located a few feet northwest of the decedent is a hat. Located a few feet north of the hat is another casing.

**County of Los Angeles, Department of Coroner
Investigator's Narrative**

Case Number: 2020-05405

Decedent: GUARDADO PINEDA, ANDRES F.

Evidence:

Physical evidence was collected. On 06/19/2020 at 0255 hours, I utilized a GSR kit on the decedent's face and both his hands at the scene. Then at 0415 hours, I removed and collected latex gloves off both the decedent's hands at the Decedent Services Unit. Then at 0420 hours, I utilized a fingernail kit to swab underneath all of the decedent's fingernails at the Decedent Services Unit. Then at 0444 hours, I utilized a hair kit to collect hair strands from the decedent's head at the Decedent Services Unit. I later booked the GSR kit, the gloves, the hair kit, and the fingernail kit as evidence at the Forensic Science Center.

Body Examination:

The decedent is an 18-year-old Hispanic male with brown eyes, brown hair, natural teeth, and a mustache. No scars or tattoos were noted. The decedent was wearing black latex gloves, black sunglasses on the back of his head, black pants, gray underwear, black socks, and white shoes. His pants had been cut by Paramedics and his shirt was collected as evidence by the Police Criminalist on scene. He was seen lying supine on the ground. The top of his head was facing west with both of his arms resting by his sides. Both of his legs were straight, with both of his feet pointing east.

His left eye appeared to be congested and bloodshot. There was dry blood residue noted to his head. There was a small abrasion noted to his left upper forehead. There was an apparent gunshot wound to his right clavicle area. There was an apparent gunshot wound to his upper right chest. There was an apparent gunshot wound to the left side of his middle abdomen. There was an apparent graze wound to his left inner forearm, his right inner forearm, and his left middle abdomen. There were a total of 5 apparent gunshot wounds noted to his upper, middle, and lower backside. Rigor mortis was absent. Lividity was light in color, seen to his backside, and blanched with pressure.

Identification:

I positively identified the decedent as GUARDADO PINEDA, ANDRES F. with a DOB of 11/03/2001 by a facial photograph from a California Identification Card present at the scene.

Next of Kin Notification:

The decedent's father, [REDACTED] was notified of the death as he was present at the scene. The decedent does not have a will, is not married, and has no children.

Tissue Donation:

Not addressed.

Autopsy Notification:

Detective Mike Davis from LASD Homicide is requesting a two-hour notification prior to the examination. Please see case notes for his private contact information.


LIANNA DARABEDYAN #646370
ACTING SUPERVISOR06/19/2020

Date of Report

FORM 82**GSR DATA SHEET****CORONER CASE #**

2020-05405

DECEDENT'S NAME

GUARDADO PINEDA, ANDRES F.

Incoming Mode
☒ HOMICIDE
 ☐ SUICIDE
 ☐ ACCIDENT
 ☐ UNDETERMINED
 ☒ OIS

INVESTIGATOR: LIANNA DARABEDYAN #646370

COLLECTED AT: ☐ FORENSIC SCIENCE CENTER ☒ SCENE ☐ HOSPITAL

COLLECTOR: LIANNA DARABEDYAN #646370 DATE: 06/19/2020 TIME: 0255

WEAPON WAS IN DECEDENT'S: ☐ LEFT HAND ☐ RIGHT HAND ☐ UNKNOWN☒ NEITHER, THE WEAPON WAS LOCATED: collected by Detectives

FIREARM – MAKE/MODEL:

unknown

AMMUNITION – BRAND/CALIBER:

9mm unknown

DATE OF SHOOTING: 06/18/2020 AT 1752 HOURS

LOCATION OF DECEDENT: ☐ INDOORS ☒ OUTDOORS ☐ AUTOMOBILE

LOCATION SHOOTING OCCURRED:

Driveway, 420 W. Redondo Beach Blvd., Gardena CA 90248

NUMBER OF SHOTS FIRED: 1+

DECEDENT'S ACTIVITY PRIOR TO SHOOTING: altercation with officers

DECEDENT'S OCCUPATION: UNKNOWN

DECEDENT'S HANDS WERE TOUCHED PRIOR TO GSR COLLECTION BY: ☒ POLICE☐ FAMILY ☒ PARAMEDICS ☐ HANDCUFFED ☐ BAGGED☐ BAGS COLLECTED ☒ OTHER: UNKNOWN

NOTES/COMMENTS :

Officer-Involved Shooting