

12**AUTOPSY REPORT**

No. 2008-09019

PARDO, BRUCE J.

Page 2**DATE OF INJURY:**

December 25, 2008

CIRCUMSTANCES:

Please see the Investigators Report for details related to the Examiner at the time of the autopsy.

DESCRIPTION OF GUNSHOT WOUND**GUNSHOT WOUND #1, a gunshot wound to the head.**

Entrance wound: The entrance wound is located inside the mouth, roughly along the midline, at the soft palate. This wound measures roughly 2-inches. There is a tear along the midline of the hard palate with separation of the palatine and maxilla bones with the fracture line extending to an area 1/2-inch above the space between the left first and second upper incisors. Sooting is present along the edges of the wound. There is no evidence of trauma to the tongue; however, some drying artifact may obscure any markings. There is no evidence of trauma to the buccal mucosa, oral mucosa, or the lips. No stippling is present. There is a 1/4-inch tear to the gingival mucosa on both sides of the left lower incisor, and this incisor is loose.

Exit wound: The exit wound is located at the top of the head, along the midline, and 1/2-inch in front of a vertical plane that passes through both ear canals. This wound is an irregular 1-1/2-inch "X" shaped, stellate like wound that reapproximates well.

Projectile recovered: A projectile is not recovered. Tiny fragments are discerned on x-rays; however, these fragments are not recovered as they are not of evidentiary value.

12**AUTOPSY REPORT**

No. 2008-09019

PARDO, BRUCE J.

Page 3

Direction: The direction of the wound is upward.

Path: This gunshot wound traverses a path with adjacent hemorrhage and loss of substance through the oral mucosa and soft palate, upward through the skull creating a 1-1/2-inch defect in front of the sella turcica involving the upper and middle cranial fossae with multiple adjacent fracture lines. The dura is perforated. The brain is perforated with a path upward, in front of the brainstem and midbrain, through the basal ganglia and frontal and parietal lobes of the cerebral cortex. The projectile perforates the dura and creates an externally beveled defect at the top of the skull with multiple radiating fracture lines. The internal table measures 3/4 x 3/4 inch. The external table measures 1-1/2 x 1 inch. Multiple areas of subgaleal hemorrhage are present. The projectile exits through the galea and scalp.

Opinion: This gunshot wound is a fatal wound inflicted during life. The gunshot wound entrance is a contact wound. The wound is self-inflicted.

EVIDENCE OF OTHER PERIMORTEM AND POSTMORTEM LESIONS:

There are two yellow/orange perimortem lesions below the left eye, measuring 1/8-inch and 1/4-inch.

There is a 2-1/2-inch burn on the posterior right neck with multiple other adjacent areas of denuded skin over a 1-inch area.

There are multiple areas of burns, punctate lesions, and skin slippage over about 40 percent of the left forearm, hand, and fingers. The majority of the lesions appear to be second to third degree thermal burns. There smaller similar lesions, up to 1-inch long, to the back and front of the right hand as well as the thumb and 2nd thru 4th fingers.

12**AUTOPSY REPORT**

No. 2008-09019

PARDO, BRUCE J.

Page 4

There is a 1-inch faint bruise to the right forearm near the antecubital fossa. There is a 1/4-inch perimortem lesion to the right upper thigh. There is a 1-inch abrasion with drying artifact on the upper right lower leg. There is a 1/4 x 1/8-inch punctate abrasion to the right lower leg. There is a 1-1/2 x 1 inch abrasion with a large amount of dried blood and with several small adjacent punctate lesions on the lower left thigh.

DESCRIPTION OF OTHER EXTERNAL MARKINGS:

No tattoos are present.

There is a 1/8-inch skin tag on the lateral right chest. There are multiple small faint hyperpigmented lesions on both shoulders, the upper chest, and both lower legs near the ankles. There are multiple tiny hypopigmented scars on the face.

EVIDENCE OF THERAPEUTIC INTERVENTION:

There is no evidence of therapeutic interventions.

There is evidence of older surgery: there is a 12-inch, well healed scar on the left lower leg, and surgical hardware is present on x-rays of the left lower leg.

ORGAN PROCUREMENT:

There is no evidence of postmortem intervention for organ or tissue procurement.

12**AUTOPSY REPORT**

No. 2008-09019

PARDO, BRUCE J.

Page 5**CLOTHING:**

The body is examined unclothed. At the time of the autopsy, no clothing was available for examination.

EXTERNAL EXAMINATION:

The above findings of injuries and interventions will not necessarily be repeated in the remainder of this report, and for clarity descriptions such as normal, intact, and unremarkable, when used, will refer to normal except for the above findings.

The body is identified by toe tags and an ankle bracelet and is that of an unembalmed, refrigerated adult Caucasian male who appears about the reported age of 45 years. The body reportedly weighs 258 pounds, measures 73 inches, and is mildly obese. Rigor mortis is moderately present with some alteration of the rigor of the muscles of the upper extremities. Livor mortis is mildly present, posterior, dependent, and fixed.

The head is normocephalic. The head is partially covered by short, brown/gray straight hair, about 1/2-inch long. Some frontal male pattern balding is present. A mustache is absent. A beard is absent. The remainder of the body hair is distributed normally in a male adult pattern. Examination of the eyes reveals irides that appear to be blue in color and sclerae that are clear. Some tache noir artifact is present. There are no petechial hemorrhages of the conjunctivae of the eyelids or the sclerae. The oronasal passages are unobstructed. Upper and lower teeth are present, in fair condition. Dentures are not present. The neck is unremarkable. There is no chest deformity. There is no increased anterior-posterior diameter. The abdomen is slightly round and is otherwise unremarkable. The genitalia are those of an adult male. The external genitalia are without trauma or lesions. The penis is uncircumcised. The testes are descended. The extremities show no edema, joint deformity, abnormal mobility, or needle tracks.

12**AUTOPSY REPORT**

No. 2008-09019

PARDO, BRUCE J.

Page 6**INITIAL INCISION:**

The body cavities are entered through the standard coronal incision and the standard Y-shaped incision. No foreign material is present in the mouth, upper airway, and trachea. The body tissues are normally hydrated.

NECK:

The neck organs are removed en bloc with the tongue. No other lesions are present, nor is trauma of the gingiva, lips or oral mucosa demonstrated. There is no edema of the larynx. The larynx is intact and without fractures. No hemorrhage is present in the adjacent throat organs, investing fascia, thyroid or visceral fascia. There are no prevertebral fascia hemorrhages. The tongue when sectioned reveals no evidence of trauma.

CHEST AND ABDOMINAL CAVITIES:

Both pleural cavities are free of adhesions and fluid. No tension pneumothorax is demonstrated. The lungs are well expanded. Soft tissues of the thoracic and abdominal walls are well preserved. The subcutaneous fat of the abdominal wall is 4.0 cm. The breasts are examined in the usual manner, and are unremarkable. The organs of the abdominal cavity have a normal arrangement, and none are absent. The peritoneal cavity has no evidence of peritonitis. There are no adhesions. There is no ascites.

12**AUTOPSY REPORT**

No. 2008-09019

PARDO, BRUCE J.

Page 7**SYSTEMIC AND ORGAN REVIEW****MUSCULOSKELETAL SYSTEM:**

In the areas of dissection, no abnormalities of the bony framework or muscles are present. The muscles are well developed.

CARDIOVASCULAR SYSTEM:

The aorta is elastic and of even caliber throughout, with vessels distributed normally from it. The aorta is free of atherosclerosis. There is no tortuosity or widening of the thoracic segment. There is no dilation of the lower abdominal segment. The major branches of the aorta show no abnormality.

The pericardial sac is smooth. The sac contains a sparse amount of clear fluid. The heart weighs 470 grams. It has an enlarged configuration. The right ventricle is 0.3 cm thick. The left ventricle is 1.2 cm thick. The septal wall is 1.2 cm thick. The chambers are normally developed and are without mural thrombosis. The valves are thin, leafy and competent. The valve circumferences in cm are mitral 11.0, aortic 7.0, tricuspid 14.5, and pulmonic 7.5. There is no endocardial discoloration. There are no lesions of the myocardium. There is no abnormality of the apices of the papillary musculature. The great vessels enter and leave in a normal fashion. The ductus arteriosus is obliterated. The coronary ostia are widely patent. The left coronary artery is the dominant vessel. There is a balanced and normal pattern of coronary artery distribution. There are no coronary atherosclerotic markings of the major coronary arteries. No focal endocardial, valvular or myocardial lesions are seen. The heart and large blood vessels contain fluid blood.

12**AUTOPSY REPORT**

No. 2008-09019

PARDO, BRUCE J.

Page 8**RESPIRATORY SYSTEM:**

Scant secretions are found in the upper respiratory airway and in the lower bronchial passages. The mucosa is intact and pale. Both lungs are mildly congested with a moderate amount of increased dependent congestion, and a moderate amount of anthracotic markings. The left lung weighs 680 grams. The right lung weighs 640 grams. The visceral pleurae are smooth and intact. Cross-sections of the parenchyma are unremarkable. No blood aspiration pattern is noted. The pulmonary vasculature is without thromboembolism.

GASTROINTESTINAL SYSTEM:

The esophagus is intact throughout. The stomach is not distended. It contains about 120 grams of partially digested food. The mucosa is unremarkable. Portions of tablets and capsules cannot be discerned in the stomach. The external and in-situ appearances of the small intestine and colon are unremarkable. The small intestine and colon are opened along the anti-mesenteric border. An unremarkable mucosal surface and contents are noted. The appendix is unremarkable. The pancreas occupies a normal position. There is a marked amount of early autolysis, some fatty infiltration present, and no necrosis present. The parenchyma is lobular and firm. The pancreatic ducts are not ectatic, and there is no parenchymal calcification.

HEPATOBIILIARY SYSTEM:

The liver weighs 2080 grams, is of average size, and is red-yellow. The capsule is intact and thin. The consistency of the parenchyma is greasy. The cut surface shows marked fatty change. There is a normal lobular arrangement. The gallbladder is not identified. There is no obstruction or dilation of the

12**AUTOPSY REPORT**

No. 2008-09019

PARDO, BRUCE J.

Page 9

extra-hepatic ducts except for a small area of dilatation near the liver that contains a small 1/8-inch irregular green stone. The periportal lymph nodes are not enlarged.

URINARY SYSTEM:

The left kidney weighs 160 grams. The right kidney weighs 150 grams. They are normally situated, and the capsule strip easily revealing a surface that is smooth and mildly congested. The corticomedullary demarcation is not obscured. Mild congestion is present. The bivalved surfaces are unremarkable. The pyramids are not remarkable. The peripelvic fat is not increased. The ureters are without dilation or obstruction and pursue their normal course. The urinary bladder is unremarkable. It contains about 200 ml of yellow/clear urine.

GENITAL SYSTEM:

The prostate is mildly enlarged, not nodular, and unremarkable. Both testes are in the scrotum, string well, are unremarkable, and are without trauma.

HEMOLYMPHATIC SYSTEM:

The spleen weighs 250 grams and is of average size. The capsule is thin, wrinkled, and intact. The parenchyma is brick red and soft. There is no increased follicular pattern. Lymph nodes throughout the body are small and inconspicuous. The bone is not remarkable. The bone marrow of the ribs is red, moist and unremarkable.

12**AUTOPSY REPORT**

No. 2008-09019

PARDO, BRUCE J.

Page 10**ENDOCRINE SYSTEM:**

The thyroid is unremarkable. The parathyroid glands are not identified. The adrenals are unremarkable. The thymus consists of unremarkable firm pale tissue with some fatty tissue. The pituitary gland is of normal size and is unremarkable.

SPECIAL SENSES:

The eyes are not dissected. The middle and inner ear are not dissected.

HEAD AND CENTRAL NERVOUS SYSTEM:

The brain weighs 1480 grams. The galea, skull, dura, cerebral cortices, leptomeninges, ventricles, basal ganglia, diencephalon, midbrain, pons, cerebellum, brainstem, cranial nerves, and cranial vasculature are anatomic and unremarkable except for the areas of injury noted above.

SPINAL CORD:

The spinal cord is not dissected or examined except for that portion visible at the base of the skull which is unremarkable.

NEUROPATHOLOGY:

A neuropathology consultation is not requested.

12**AUTOPSY REPORT**

No. 2008-09019

PARDO, BRUCE J.

Page 12**WITNESSES:**

Detectives Regan and Robinson, Covina Police Department, attended the autopsy.

DIAGRAMS USED:

Diagrams and worksheet, Forms 16, 20, 20-G, 21, 22, 28, and 34 are used during the course of the autopsy. These diagrams are not intended to be facsimiles.

OPINION:


The decedent died of a gunshot wound to the head. The manner of death is suicide.



DAVID B. WHITEMAN, M.D.
DEPUTY MEDICAL EXAMINER

03/26/2009

DATE

DBW:dbw:pc
T-12/29/2008 @ 1753


15

AUTOPSY CLASS: ☒ A ☐ B ☐ C ☐ Examination Only DDate 12/29/2008 Time 1730 Dr. WilliamFINAL ON 12/29/2008 By William printAPPROXIMATE
INTERVAL
BETWEEN
ONSET
AND
DEATH

DEATH WAS CAUSED BY: (Enter only one cause per line for A, B, C, and D)

IMMEDIATE CAUSE

(A) Gunshot Wound to the Head

DUE TO, OR AS A CONSEQUENCE OF

(B) DUE TO, OR AS A CONSEQUENCE OF

(C) DUE TO, OR AS A CONSEQUENCE OF

(D) Other conditions contributing but not related to the immediate cause of death:

☐ NATURAL ☒ SUICIDE ☐ HOMICIDE☐ ACCIDENT ☐ COULD NOT BE DETERMINEDIf other than natural causes
HOW DID INJURY OCCUR?WAS OPERATION PERFORMED FOR ANY CONDITION STATED ABOVE: ☐ YES ☒ NO

TYPE SURGERY _____ DATE _____

☐ ORGAN PROCUREMENT☐ TECHNICIAN Alman☒ WITNESSES TO AUTOPSY☐ EVIDENCE RECOVERED AT AUTOPSY
Item Description: _____

PRIOR EXAMINATION REVIEW BY DME

☒ BODY TAG ☐ CLOTHING
☒ X-RAY (No 3) ☐ FLUORO
☐ SPECIAL ☐ MED. RECORDS

PROCESSING TAG

☐ AT SCENE PHOTOS (No _____)TYPING BLOOD TAKEN BY RL
SOURCE Heart

TOXICOLOGY

☐ NO BLOOD
☐ Embalmed
☐ >24 hr in hospital
☐ Decomposed
☐ Other _____ Reason

SPECIMENS

Collected by Delo
☒ HEART BLOOD ☒ STOMACH CONT.
☒ FEMORAL BLOOD ☒ BRAIN
☐ _____ BLOOD ☐ SPLEEN
☐ _____ BLOOD ☐ KIDNEY
☐ BILE ☒ VITREOUS
☒ LIVER ☐ _____
☒ URINE ☐ _____

STORAGE JARS

☒ Regular (No three) ☐ Oversize (No _____)Histopath Cut: ☐ Autopsy ☐ Lab☐ NO TOXICOLOGY REQUESTED

TOXICOLOGICAL ANALYSES ORDERED

SCREEN: ☒ C ☐ H ☐ T ☐ S☐ ALCOHOL ONLY
☐ CARBON MONOXIDE
☐ NEOGEN SCREEN
☐ OTHER (specify drug and tissue)

REQUESTED MATERIAL ON PENDING CASES

☐ Police Report ☐ Med History
☐ Tox ☐ Histo
☐ Microbiology ☐ Investigations
☐ Radiology Cons. ☐ Eye Path. Cons
☐ Consult on _____
☐ Brain Submitted
☐ Neuro Consult ☐ DME to Cut
☐ Criminalistics
☐ GSR ☐ Sexual Assault ☐ Other

Resident

DME

AUTOPSY CHECK SHEET

16

EXTERNAL EXAM

Sex *Male*
 Race *Caucasian*
 Age *45*
 Height *73*
 Weight *250*
 Hair *1/2 grey & straightened frontal hair*
 Eyes *blue* *slight blue*
 Sclera *blue*
 Teeth *intact*
 Mouth *—*
 Tongue *—*
 Nose *—*
 Chest *—*
 Breasts *—*
 Abdomen *slightly prot*
 Scar *on arm*
 Genitals *uncirc*
 Edema *—*
 Skin *—*
 Decubitus *—*
 HEART Wt. *470*
 Pericardium *spare* RV *0.3*
 Hypertrophy Septum *1.2*
 Dilation LV *1.2*
 Muscle Septum *—*
 Valves *—*
 Coronaries *clear* *M 1.0 T 1.5*
 AORTA *clear*
 VESSELS *A 2.0 P 7.5*
 LUNGS Wt. *—*
 R *650*
 L *650*
 Adhesions *—*
 Fluid *—*
 Atelectasis *—*
 Oedema *—*
 Congestion *—*
 Consolidation *—*
 Bronchi *—*
 Nodes *—*
 PHARYNX *—*
 TRACHEA *—*
 THYROID *—*
 THYMUS *—*
 LARYNX *—*
 HYOID *—*
 ABDOMINAL WALL FAT *400*

PERITONEUM

Fluid *small*
 Adhesions *—*
 LIVER Wt. *2030*
 Capsule *cut*
 Lobules *—*
 Fibros *—*
 G B *small*
 Calculus *—*
 Bile ducts *—*
 SPLEEN Wt. *250*
 Color *—*
 Consistency *—*
 Capsule *—*
 Malpiment *—*

PANCREAS
 ADRENALS
 KIDNEYS Wt.

R *150*
 L *160*
 Capsule *small*
 Cortex *—*
 Vessels *—*
 Pelvis *—*
 Ureters *—*

BLADDER
 GENITALIA

Prostate *mid enlargement*
 Testes *—*
 Uterus *—*
 Tubes *—*
 Ovaries *—*

OESOPHAGUS
 STOMACH

Contents *1200g partially digested*
 DUOD. & SM. INT. *—*
 APPENDIX *—*
 LARGE INT. *—*
 ABDOM. NODES *—*
 SKELETON *—*

Spine *—*
 Marrow *—*
 Rib Cage *—*
 Long bones *—*
 Pelvis *—*

SCALP

CALVARIUM *—*
 BRAIN Wt. *1250*
 Dura *—*
 Fluid *—*
 Ventricles *—*
 Vessels *—*
 Middle ears *—*
 Other *—*
 PITUITARY *—*

SPINAL CORD

TOXICOLOGY SPECIMENS

H-Blood *—* F-Blood *—*
 S.O.T.A. *—* Urine *—* V. Tr. *Steady*

SECTIONS FOR
 HISTOPATHOLOGY

MICROBIOLOGY

DIAGRAMS *20 200, 21*
 X-RAYS *3 22, 28, 34*

OTHER PROCEDURES

GROSS IMPRESSIONS

—

Date

Time

Deputy Medical Examiner



Autopsyfiles.org - Bruce Pardo Autopsy Report
Department of Coroner, County of Los Angeles
FORENSIC SCIENCE LABORATORIES
Laboratory Analysis Summary Report



Wednesday, January 21, 2009

To: Dr. Whiteman
Deputy Medical Examiner

☐ PendingTox

Subject: Coroner Case Number 2008-09019 PARDO, BRUCE JEFFREY

The following results have been technically and administratively reviewed and are the opinions and interpretations of the Analyst:

<u>SPECIMEN</u>	<u>SERVICE</u>	<u>DRUG</u>	<u>LEVEL</u>	<u>UNITS</u>	<u>ANALYST</u>
Blood, Heart					
	Alcohol	Ethanol		Negative	M. Schuchardt
	Barbiturate	Barbiturates		ND	O. Pleitez
	Bases	Basic Drugs		ND	S. DeQuintana
	Cocaine	Benzoyllecgonine	0.07	ug/ml	R. Budd
	Cocaine	Cocaethylene		ND	R. Budd
	Cocaine	Cocaine	< 0.03	ug/ml	R. Budd
	Fentanyl	Fentanyl		ND	O. Pleitez
	Marijuana	Carboxy-THC		ND	O. Pleitez
	Methamphetamine	Methamphetamine		ND	O. Pleitez
	Opiates	Codeine		ND	O. Pleitez
	Opiates	Morphine		ND	O. Pleitez
	Phencyclidine	Phencyclidine		ND	O. Pleitez
Urine					
	Cocaine	Benzoyllecgonine	0.99	ug/ml	R. Budd
	Cocaine	Cocaethylene		ND	R. Budd
	Cocaine	Cocaine	0.66	ug/ml	R. Budd

Legend:

% Saturation

*

Done

g

g%

Inc.

mEq/l

mg

mg/dl

mg/l

mmol/l

ND

Negative

ng/gm

Grams

Gram Percent

Inconclusive

Milli equivalents

Milligrams

Milligram per Deciliter

Milligram per Liter

Millimoles per Liter

Not Detected

Nanograms per Gram

QNS

TNP

Trace

ug

ug/g

ug/l

ug/ml

Quantity Not Sufficient

Test Not Performed

Micrograms

Micrograms per Gram

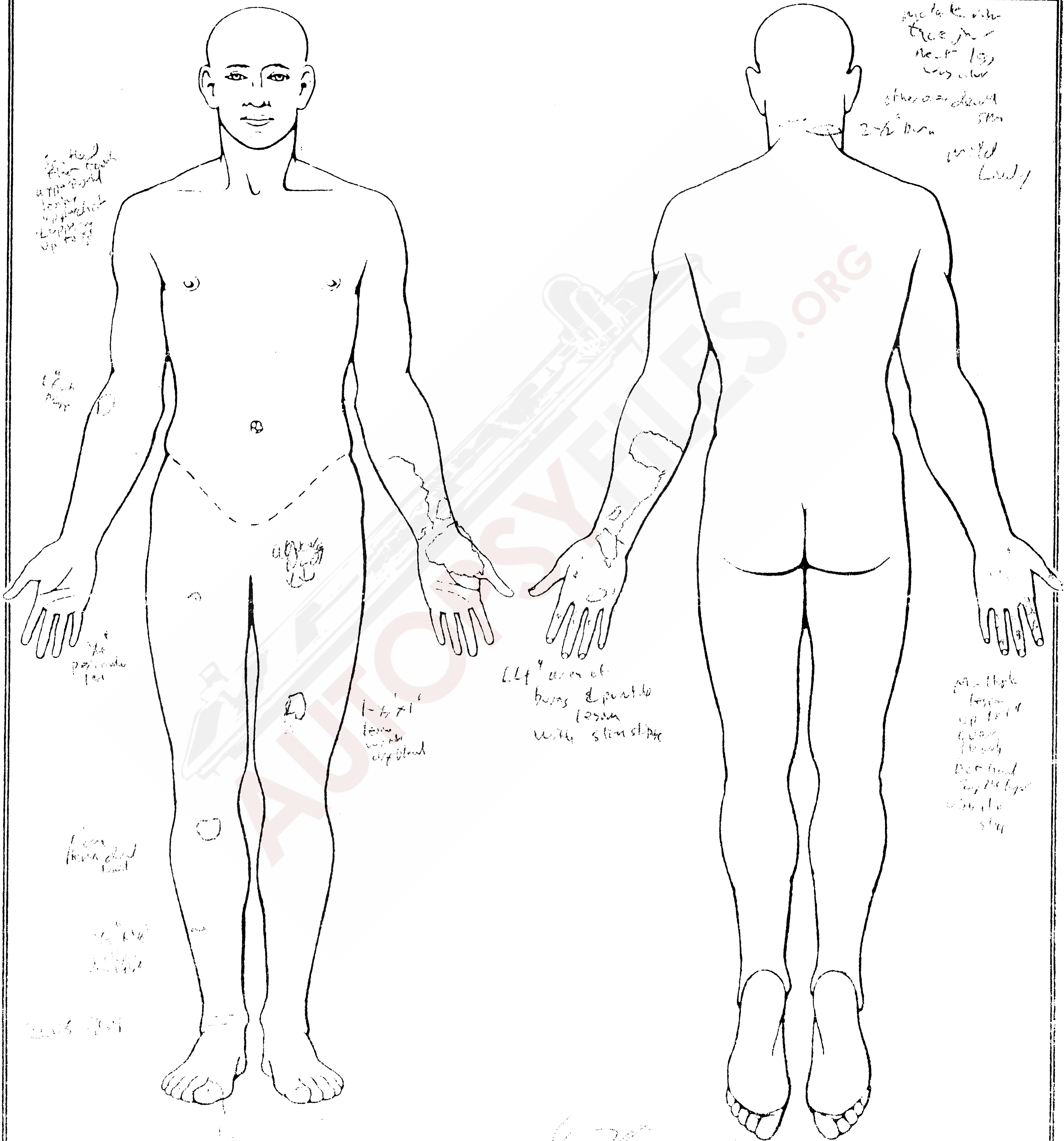
Microgram per Milliliter

Administratively reviewed by: Daniel T. Anderson
Supervising Criminalist II
FORENSIC LABORATORIES

20

15/16 Caucasian male
73" 258 lb

15/16 Caucasian male
73" 258 lb
12/11/11

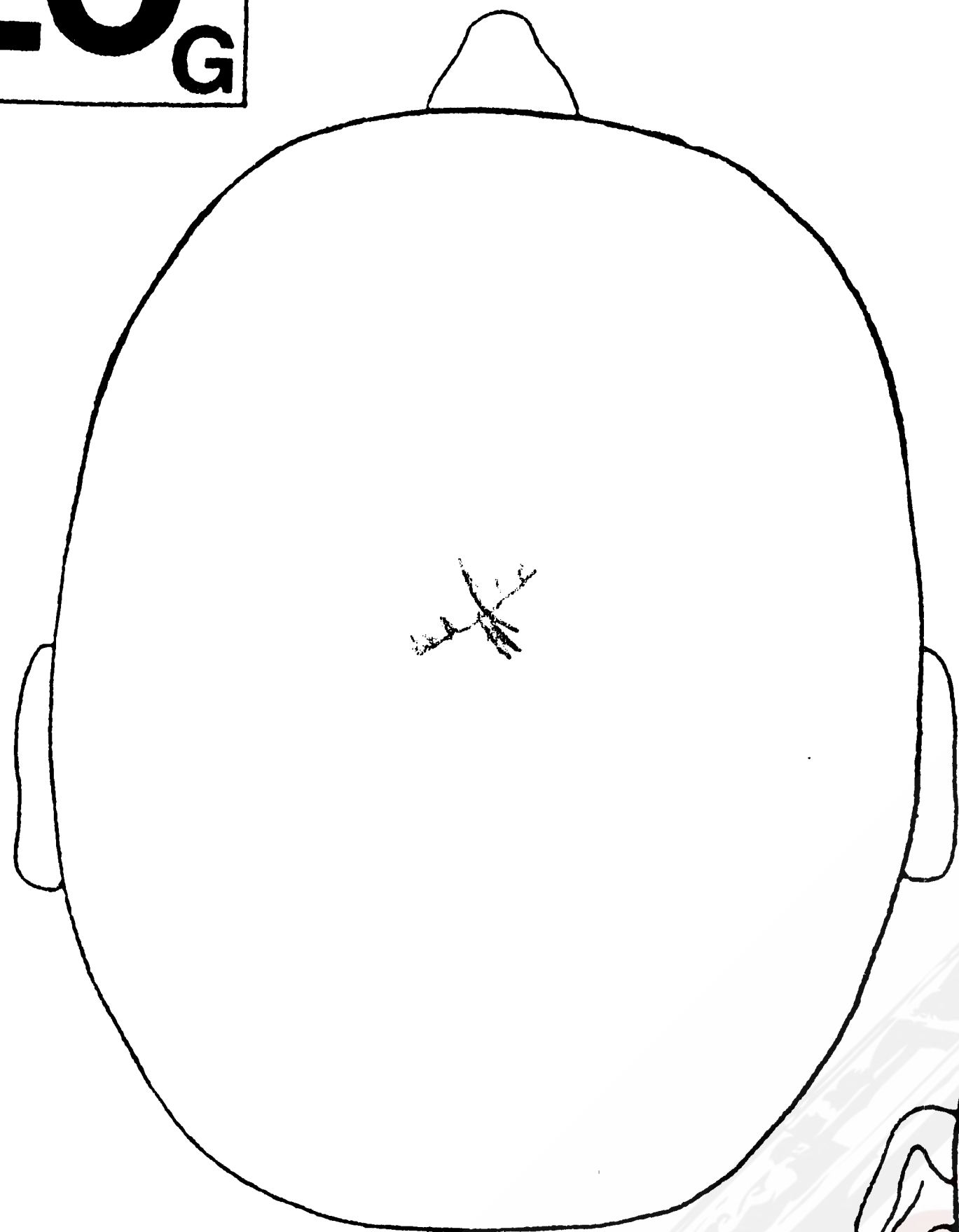


[Signature]

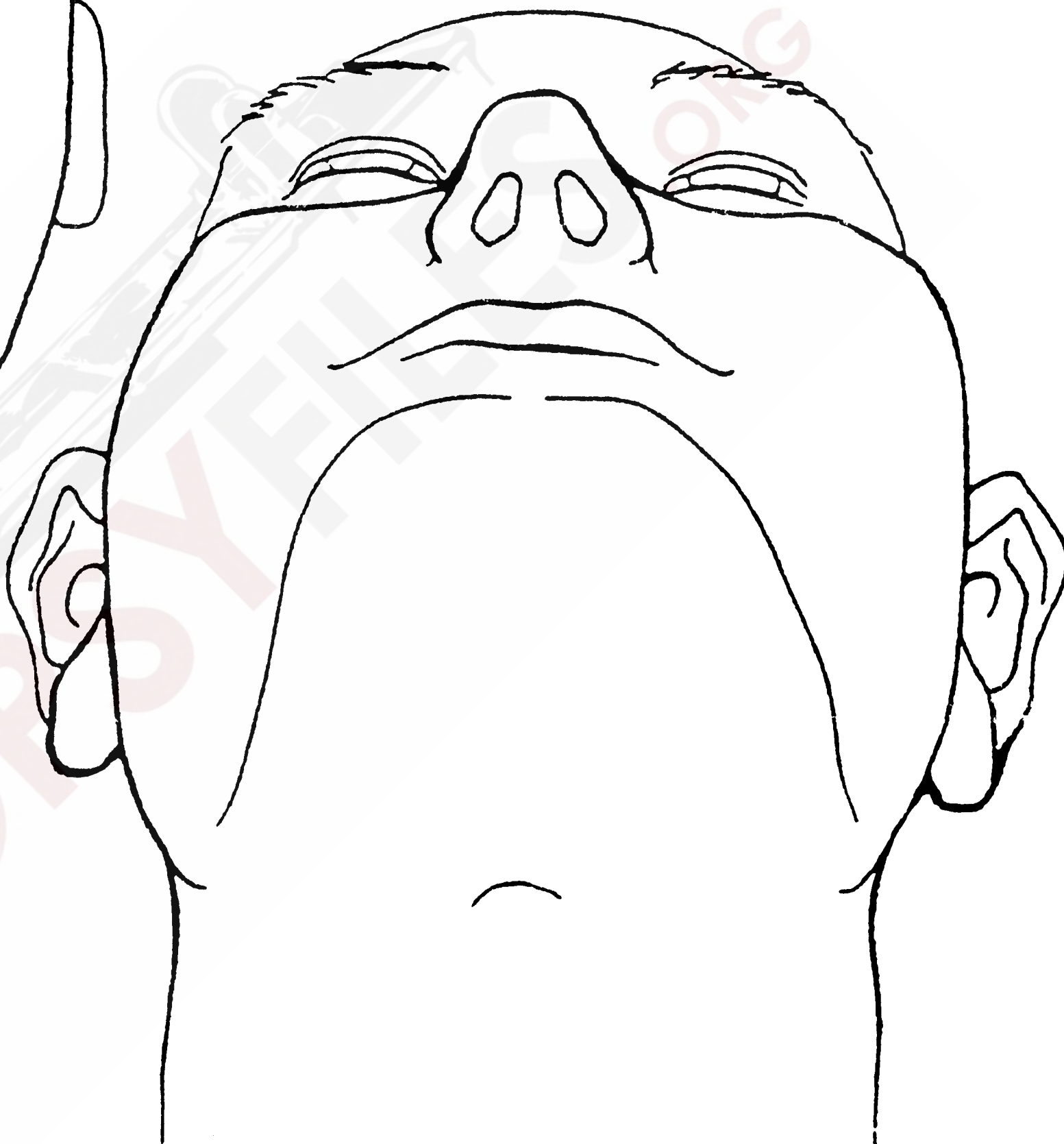
Deputy Medical Examiner

M.D.

20_G



1-2 "X" marks
stellate wound
@ Top of Head
X Bone fracture



Date 12/12/01

[Signature]


M.D.

Deputy Medical Examiner.


21

2000-0010
10-0000-00000

1/8" study



Rt



12" study
500
1000000
00000

Lt

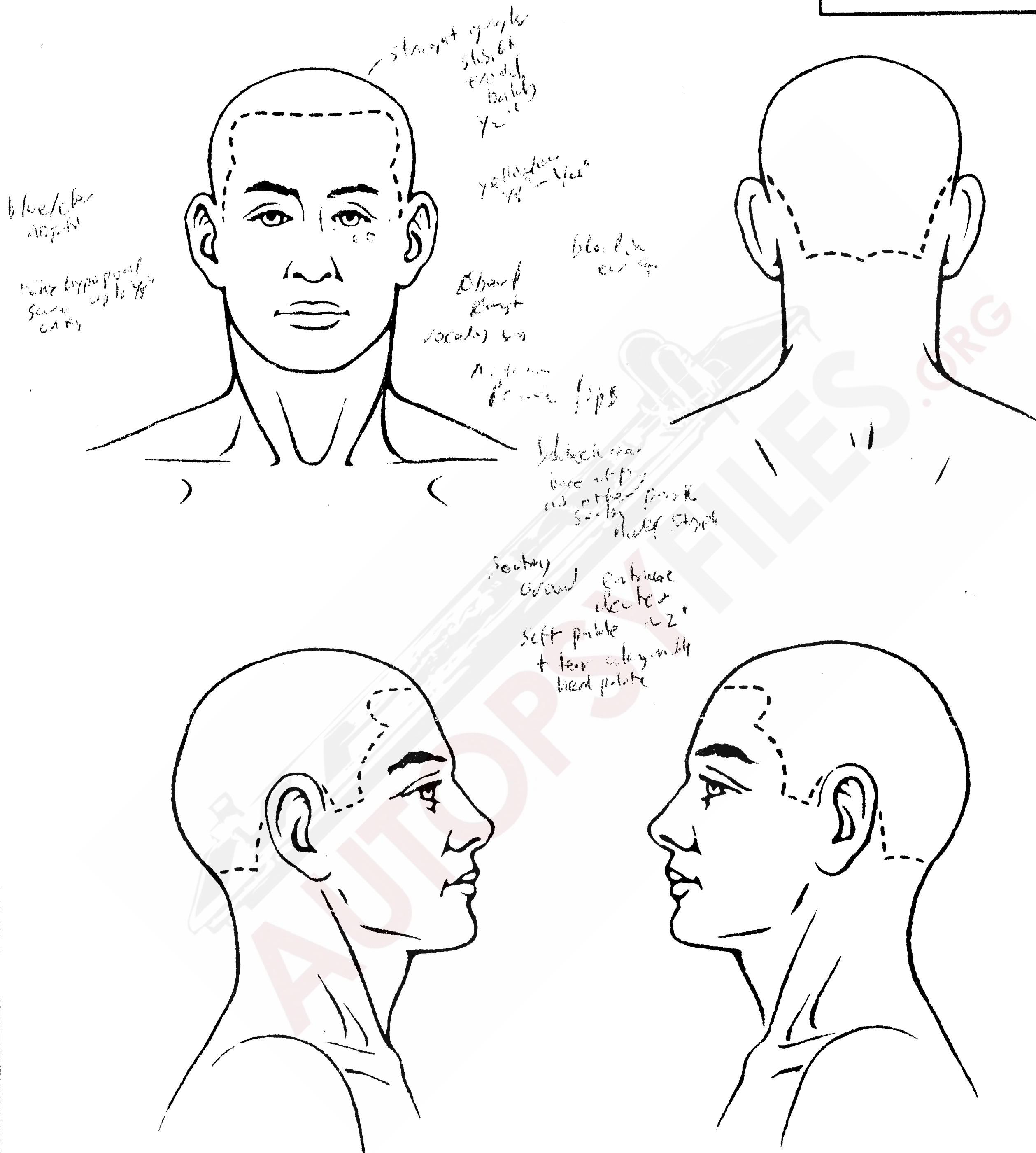
[Signature]

M.D.

Deputy Medical Examiner

22

2000-09018
PAIDOL, BRUCE JEFFREY
C-11




15th *10/10/1944*

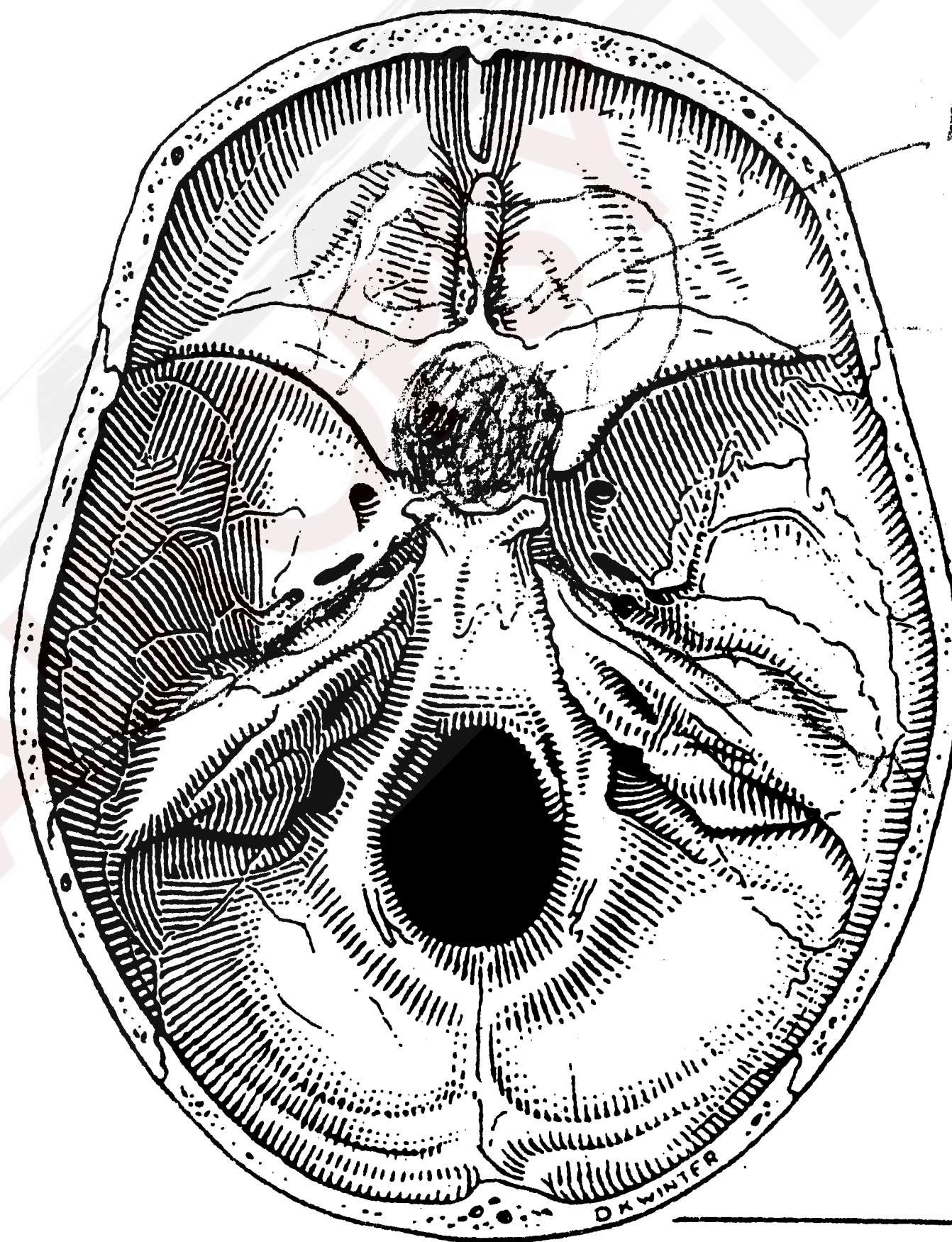
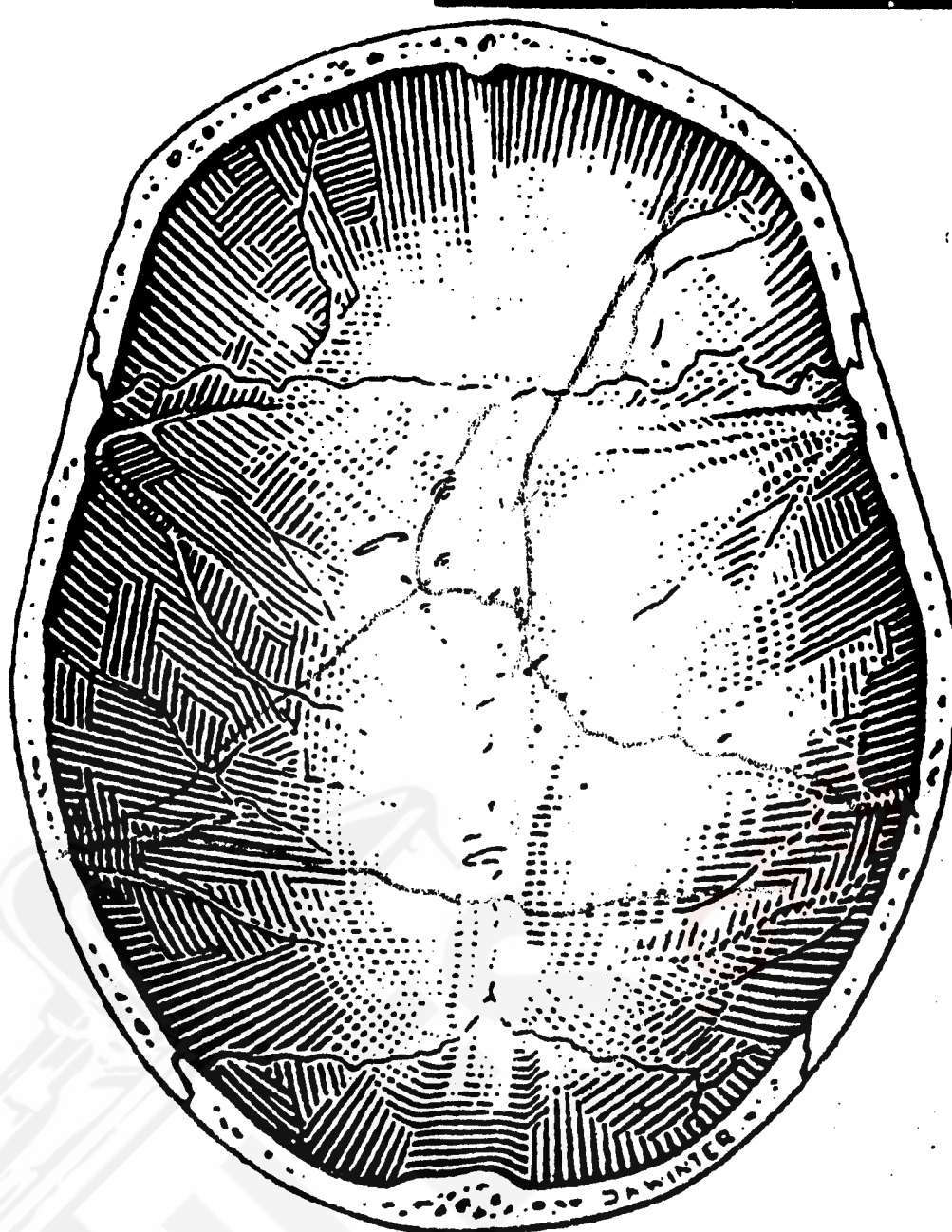
M.D.

Deputy Medical Examiner

28



ethmoidal
foramina
about 6/10
1/2 x 1/2



multiple fractures

about 1/2 x 1/2

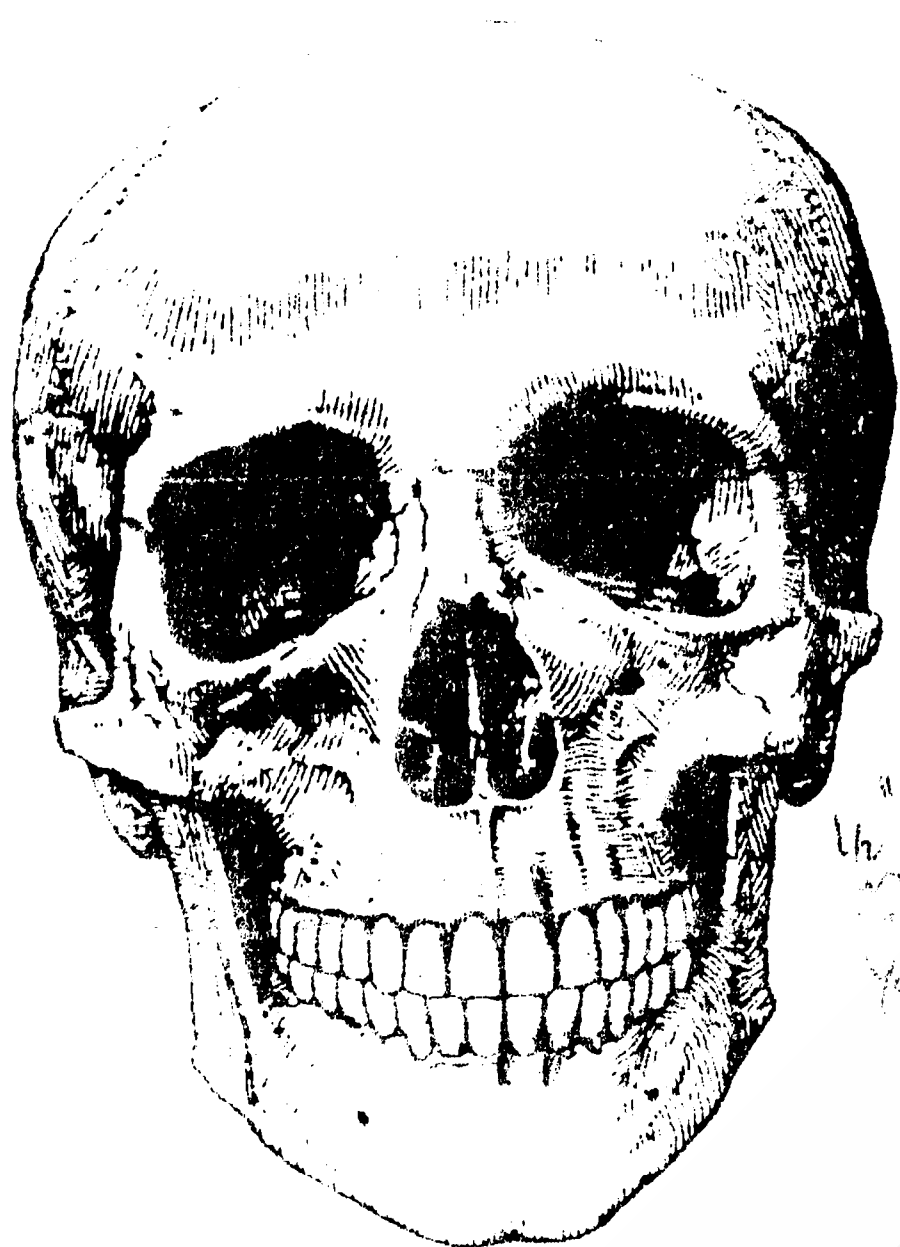[Signature]

Deputy Medical Examiner

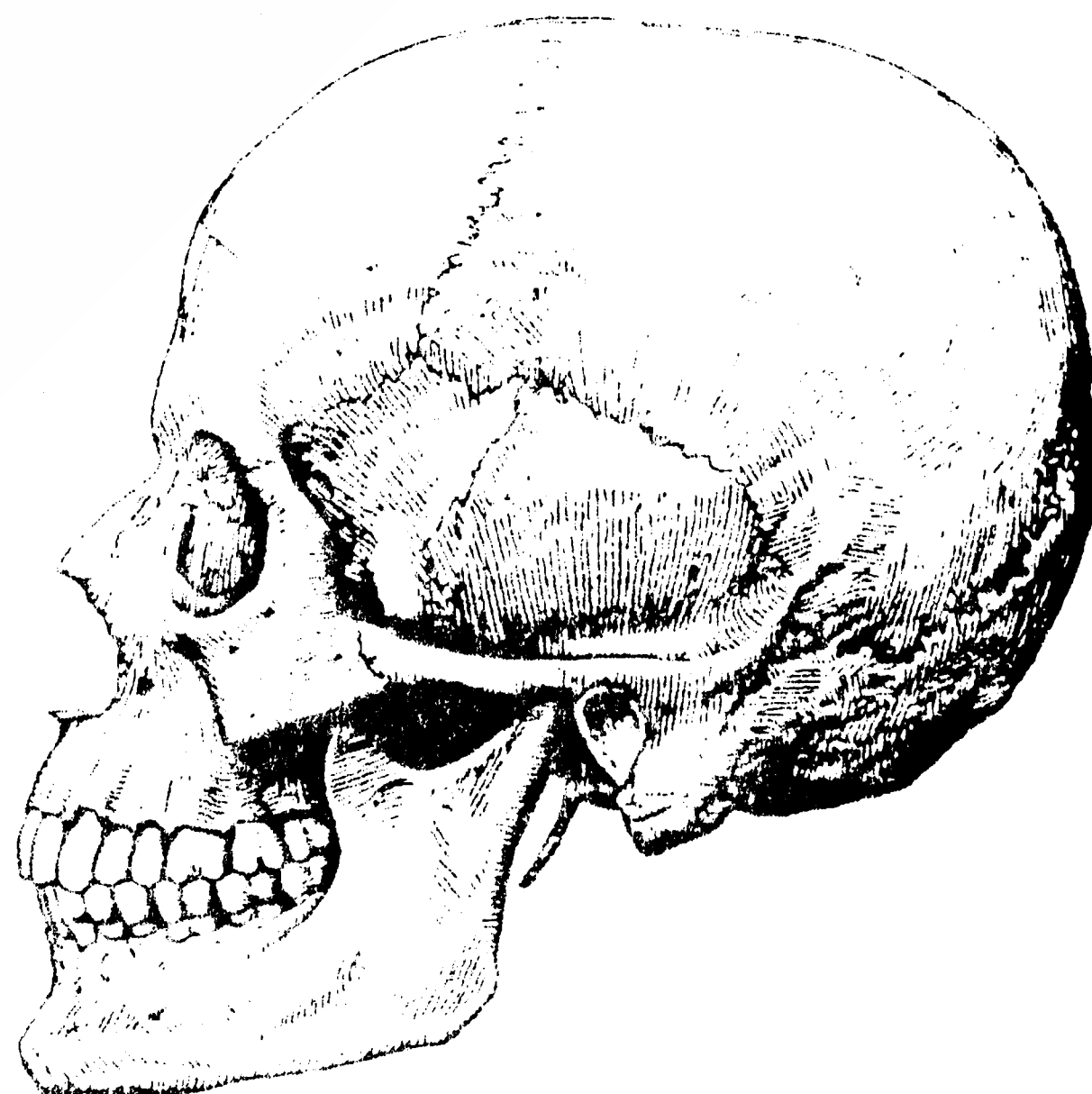
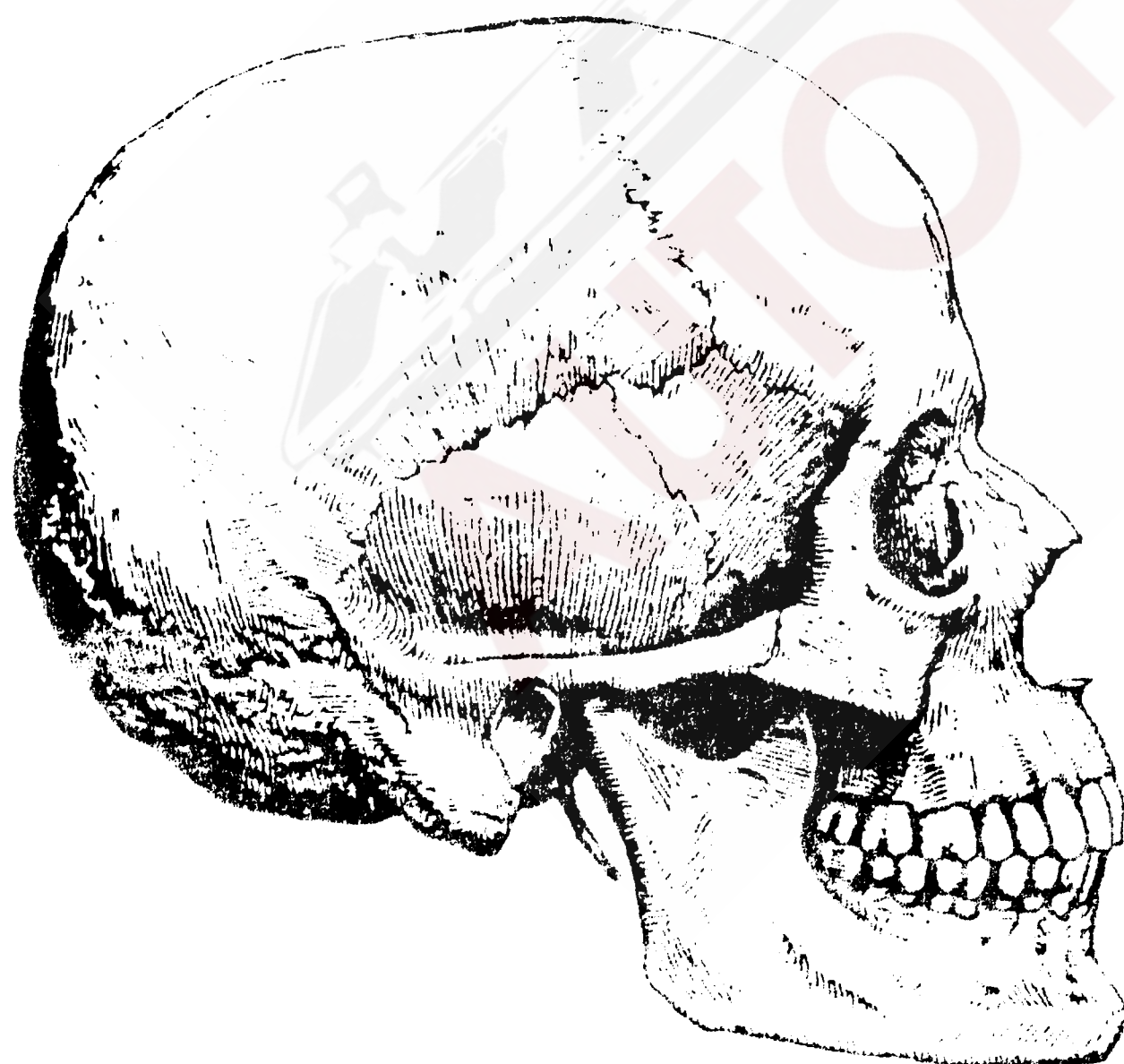
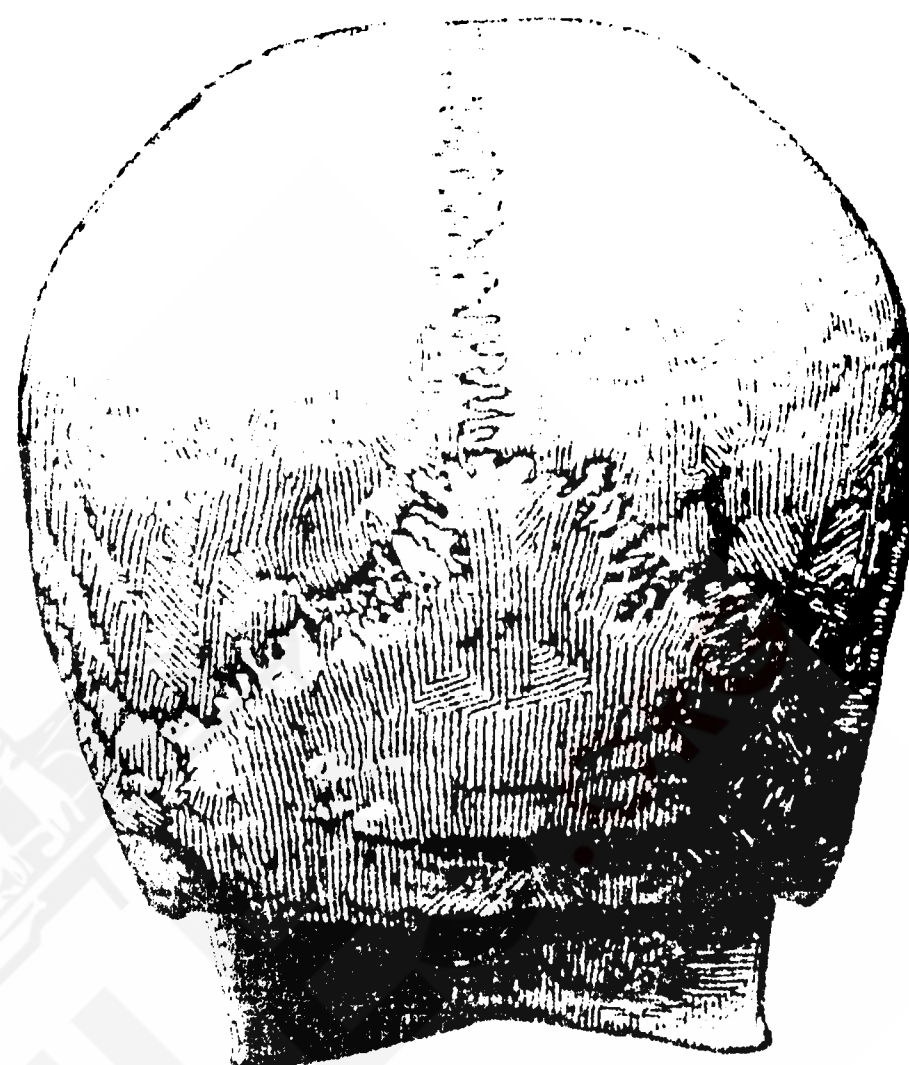M.D.

2018-09-01
P. 38 100 1000000
S. 100 100 1000000

34



1/2 jaw
1/2 nose
1/2 mouth



[Signature]

[Signature]

MD

Dr. Bruce Pardo

6

WAS ORIGINAL SCENE DISTURBED BY OTHERS? Y() N()
IF YES, NOTE CHANGES IN NARRATIVE FORM #3.
DATE 12/25/8
AMBIENT #1 55.4 °F TIME 1306
AMBIENT #2 _____ °F TIME _____
WATER _____ °F TIME _____

Pardo, Bruce
2008-09019
THERMOMETER # 07-19

LIVER TEMPERATURE #1 92.8 °F TIME 1310
LIVER TEMPERATURE #2 _____ °F TIME _____

DATE & TIME FOUND 12/25/8 0310 CST LAST KNOWN ALIVE 12/24/8 2330 CST

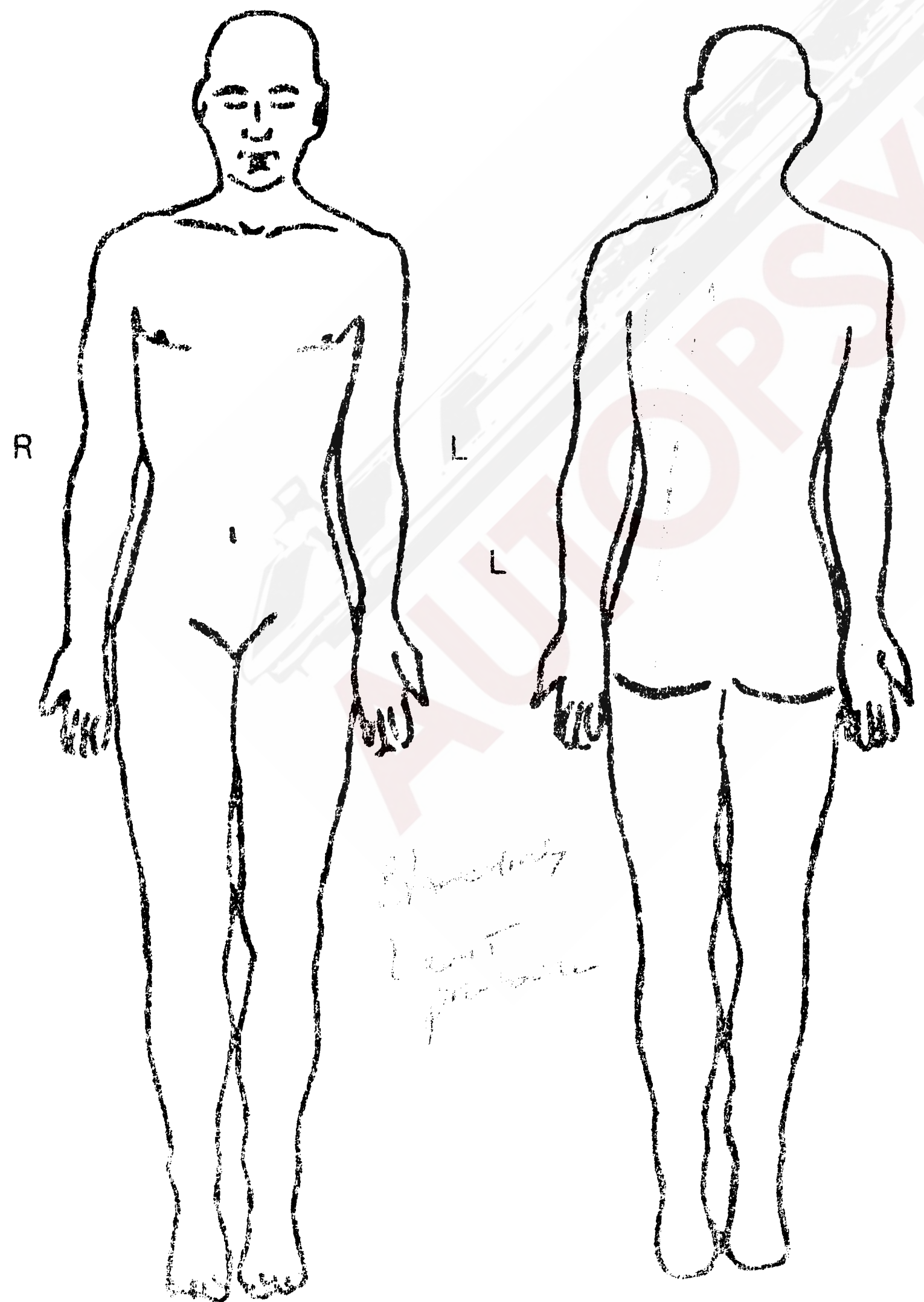
APPROX. AGE 45 SEX M EST. HEIGHT 75 EST. WEIGHT 250 CLOTHED? YES ☒ NO ☐ IF YES, DESCRIBE:
Black Thinner shirt, Black Belt, Black Pants, Green Boxers,
Cap, Black Socks, Black Slippers

DESCRIPTION AS TO WHERE REMAINS FOUND AND CONTACT MATERIAL TO BODY:
Sitting on Couch

SCENE TEMPERATURE REGULATED? YES ☐ NO ☒ IF YES, THERMOSTAT SET AT _____ DEGREES F.

LIVOR MORTIS. TIME OBSERVED 1320 RIGOR MORTIS. TIME OBSERVED 1318

NECK FLEXION:



ANTERIOR 2
POSTERIOR 2
RT. LATERAL 2
LT. LATERAL 2
JAW 2 HIP 2
SHOULDER 2 KNEE 2
ELBOW 2 ANKLE 2
WRIST 2

SCALE
0 = ABSENT/NEGATIVE
1 +
2 +
3 +
4 = EXTREME DEGREE

USE SCALE TO DESCRIBE INTENSITY OF RIGOR MORTIS.

SHADE DIAGRAMS TO ILLUSTRATE THE LOCATION OF LIVOR MORTIS.

DESCRIBE INTENSITY OF COLORATION AND WHETHER LIVOR MORTIS IS PERMANENT OR BLANCHES UNDER PRESSURE.

[Signature]
CORONER'S INVESTIGATOR
REVIEWED BY

82

- ☐ Accident
- ☐ Homicide
- ☒ Suicide
- ☐ Questionable Accident/Homicide
- ☐ Questionable Accident/Suicide
- ☐ Questionable Suicide/Homicide
- ☐ Investigator Requests Rush

Kit #

C
3973

2008-09019

franco, Rocio

INFORMATION ABOUT DECEDENT/SHOOTING

☐ Right Handed ☐ Left Handed ☒ Unknown

☒ Male ☐ Female

Occupation _____ ☒ Unknown

Activity Prior to Shooting voluntary

Have the decedent's hands been touched by anyone prior to taking the GSR sample? ☐ Yes ☐ No ☒ Unknown

If yes, by whom? ☐ Paramedics ☐ Family ☐ Police ☐ Hospital Personnel
☐ Other _____

Was the weapon found in the decedent's hand? ☐ Yes ☒ No ☐ Unknown - Moved prior arrival

If yes, which one? ☐ Right ☐ Left

If no, describe weapon's location in relationship to decedent on table 2 feet
of decedent

Shooting Occurred: ☒ Indoors ☐ Outdoors ☐ Unknown

Location of Body: ☒ Indoors ☐ Outdoors ☐ Automobile ☐ Hospital
Other _____

Number of Shots Fired: 2

Date Unknown and Time _____ of Shooting

Date 12/25/8 and Time 1223 GSR samples were taken.

GSR evidence collected ☒ At Scene ☐ At FSC ☐ At Hospital
☐ Other _____ By: Hunter

Body transported to FSC via ☒ Coroner ☐ Contractor _____

FIREARM

☐ Revolver ☒ Semi-automatic/automatic ☐ Rifle ☐ Shotgun

☐ Other _____

Make/Model S&W S&W Caliber 9mm

AMMUNITION

Brand of Ammunition Lucas + P Caliber of Ammunition 9mm

Bullet Configuration: ☐ Round Nose ☒ Hollow Point ☐ Wad Cutter ☐ Pointed

Other _____

Bullet Surface: ☒ Jacketed ☐ Semi-jacketed ☐ Bare Lead ☐ Plated

Comments: 2 weapons - GSR S&W T&T no shot

Investigator

Date

Do not write below this line

RESULTS:

White: Medical file
Pink: Laboratory Copy
Yellow: Laboratory Copy

**County of Los Angeles, Department of Coroner**
Investigator's Narrative

Case Number: 2008-09019

Decedent: PARDO, BRUCE JEFFREY

Information Sources:

1. Detective J. Freund, LAPD Mission division 818- [REDACTED]

Investigation:

On 12/25/2008 at 0959 hours Detective Macciarella reported the apparent Suicide (gunshot wound) death of this adult male to Sylvia Hernandez. At 1115 hours Supervising Investigator Dietz assigned me to investigate this death and handle it as a homicide. I arrived at the scene at 1140 hours and departed the scene at 1438 hours.

Location:

INJURY/DEATH: residence/living room located at [REDACTED] Joseph CT Sylmar, 91342.

Informant/Witness Statements:

All information is preliminary and subject to change.

Detective Freund provided the following: the decedent had gone through a bitter divorce and had gone to a location in the City Of Covina dressed as Santa Claus and reportedly shot several people and ignited that location on fire. He was then discovered by his brother Brad Pardo [REDACTED] in Brad's residence when Brad returned home about 0310 hours on 12/25/2008. 911 was called with LAFD paramedics responding and pronouncing death at 0320 hours on 12/25/2008. One gun had been in the decedent's lap and the second in his hand unknown which. Both had been moved to the table by the decedent's brother at the direction of the 911 operator. An apparent suicide death gunshot wound to the head, no note. Covina Police Detectives are handling this investigation. Detective Stacy Franco 626-[REDACTED] and Detective Brian Kingwill 626-[REDACTED] 444 North Citrus Avenue Covina, 91723.

Two handguns, magazines and rounds were recovered at the scene and released to Covina PD Detectives.

1) Sig Sauer mod. P226 9mm semi-auto serial number U777822. This weapon had one round in the chamber with the hammer in the cocked position. There are 16 rounds in the magazine. Rounds are Luger +P 9mm jacketed hollow point.

2) Sig Sauer mod. P226 9mm semi-auto serial number U459976. This weapon had one round in the chamber and this magazine is empty. The round is a Luger +p 9mm jacketed hollow point.

Scene Description:

The scene is a single-family residence. The decedent is seated on the living room couch; there are two handguns on the table in front of him. A flashlight next to the decedent was dropped there by the decedent's brother. There is an apparent bullet hole in the ceiling above the decedent. There is damage to the wall behind the decedent. The residence is furnished and neat. When the decedent was moved there was a projectile recovered beneath him which was recovered by Covina PD Detectives. A spent casing had been recovered prior to my arrival on the couch by the decedent's buttocks and a second casing was located during my investigation under the decedent's right arm and collected by Covina Detectives.

Evidence:

Physical evidence was collected at the scene on 12/25/2008 including Hair kit, Nail kit, GSR kit #C3973 and physical evidence consisting of hair. Additional evidence including US Currency, keys, wig, gloves, paper and batteries were recovered from the decedent and released to Covina PD Detectives see evidence log for details. A special processing tag was initiated at the scene and transported with the decedent.

**County of Los Angeles, Department of Coroner
Investigator's Narrative**

Case Number: 2008-09019

Decedent: PARDO, BRUCE JEFFREY

Body Examination:

My initial field body examination revealed a supine adult male. He has short brown hair, blue eyes, natural teeth and is clean shaven. He is wearing a black thermal "T" shirt, black belt, black pants, green boxer style underpants, "girdle" with hard cup, black socks and black shoes. There are what appear to be remnants of a "Santa suit" around the left ankle and remnants of red material on his remaining clothing. There is a watch on the left wrist and ring on the left ring finger. The left front pants pocket contained a wallet, keys and fourteen cents. The right front pants pocket contained a pen, single key and quarter. The left rear pants pocket contained two white gloves and two batteries. The right rear pants pocket contained two papers and six batteries. There are burns, blistering and skin slippage on the hands and forearms. There is hair on the right hand stuck to the burns (recovered and booked into evidence). There is what appears to be masking tape around both forearms, with sections missing. This was left in place for examination by DME and later recovery. There is a scar on the left lower outer leg. There is an apparent entrance gunshot wound to the mouth with an apparent exit wound to the top of the head. Ambient temperature at 1306 hours is 55.4 degrees F and liver temperature at 1310 hours is 92.8 degrees F. Livor mortis is blanching with light pressure and consistent with found position. Rigor mortis is moderate (2). The decedent's tongue is clenched between his teeth. Additionally during the body examination a stack of money wrapped in clear plastic was found by the left calf with additional packages of money also wrapped in plastic in the "girdle" along with a wig and handcuff key with clear tape on it.

Identification:

The decedent is identified as Bruce Jeffrey Pardo by his California Drivers License [REDACTED]

Next of Kin Notification:

Who was notified by police and confirmed by Detective Freund.

Tissue Donation:

Next of kin not approached.

Autopsy Notification:

Detective Regan, Covina Police Department requests three hour examination notice.

RICHARD HANNA

LARRY DIETZ

12/25/2008

Date of Report

COUNTY OF LOS ANGELES

CASE REPORT

DEPARTMENT OF CORONER

APPARENT MODE

SUICIDE

CASE NO

2008-09019

SPECIAL CIRCUMSTANCES

Gunshot Wound

CRYPT

LAST, FIRST MIDDLE

AKA

#

PARDO, BRUCE JEFFREY

ADDRESS

LKA 4004 SUNSET AVENUE

CITY

MONTROSE

STATE

CA

ZIP

91020

SEX	RACE APPEARS	DOB	AGE	HGT	WGT	EYES	HAIR	TEETH	FACIAL HAIR	VIEW	CONDITION
MALE	CAUCASIAN	3/23/1963	45	in.	lbs.	BLUE	BROWN	ALL NATURAL TEETH	CLEAN SHAVEN	Yes	FAIR

MARK TYPE

MARK LOCATION

MARK DESCRIPTION

SCAR

LEFT LEG

NOK

ADDRESS

CITY

STATE

ZIP

RELATIONSHIP

PHONE

NOTIFIED BY

DATE

TIME

12/25/2008

SSN

DL ID

N9536618

STATE

CA

PENDING BY

ID METHOD

CALIFORNIA DRIVER'S LICENSE

LA #

MAIN #

CII #

FBI #

MILITARY #

POB

IDENTIFIED BY NAME (PRINT)

RELATIONSHIP

PHONE

DATE

TIME

RICHARD HANNA

NONE

(818) 364-3323

12/25/2008

PLACE OF DEATH / PLACE FOUND

ADDRESS OR LOCATION

CITY

ZIP

PRIVATE RESIDENCE

15835 JOSEPH CT

SYLMAR

91342

PLACE OF INJURY

AT WORK

DATE

TIME

LOCATION OR ADDRESS

ZIP

RESIDENCE/LIVING ROOM

No

15835 JOSEPH CT, SYLMAR, CA

91342

DOD

TIME

FOUND OR PRONOUNCED BY

PARAMEDICS LAFD

OTHER AGENCY INV OFFICER

PHONE

REPORT NO.

NOTIFIED BY

NO

LAPD MISSION HILLS - DETECTIVE FREUND

(818) 838-9952

TRANSPORTED BY

TO

DATE

TIME

LOS ANGELES FSC

FINGERPRINTS?

No

CLOTHING

No

PARPT

No

MORTUARY

MED. EV

No

INVEST. PHOTO #

11

SEAL TYPE

NOT SEALED

HOSP RPT

No

PHYS. EV

Yes

EVIDENCE LOG

Yes

PROPERTY?

Yes

HOSP CHART

No

SUICIDE NOTE

No

GSR NO

C3973

RGPT. NO.

218700

PF NO

SYNOPSIS

DECEDENT IS A 45 YEAR-OLD MALE WITH NO REPORTED SOCIAL OR MEDICAL HISTORY. REPORTEDLY BITTER OVER A DIVORCE, POSSIBLY RESPONSIBLE FOR THE HOMICIDE DEATHS OF AT LEAST THREE OTHERS AND ARSON OF THE RESIDENCE. DECEDENT WAS DISCOVERED WITH AN APPARENT SELF-INFLICTED GUNSHOT WOUND BY HIS BROTHER IN HIS BROTHERS RESIDENCE. SUICIDE, NO NOTE.

RICHARD HANNA

459892

DATE

12/25/2008

REVIEWED BY

DATE

INVESTIGATOR

TIME

18 42

TIME

FORM #3 NARRATIVE TO FOLLOW? ✓



Autopsyfiles.org - Bruce Pardo Autopsy Report