

San Bernardino County Sheriff - Coroner Division

Coroner Investigation



1	MODE Homicide STATUS Post	CASE # 701509091 DEPUTY Lela Perriello	Sub File To 701509087
---	--	---	---------------------------------

CASE INFO

REPORTED BY ****	AGENCY San Bernardino Police Department (SBPD)	DATE 12/03/2015	TIME 0052	Call Back Phone ****	
NEWS RELEASE ****	NAME RELEASABLE ****	ROLL-OUT? Yes	# OF PHOTOS ****	MEDIUM ****	SPECIAL CIRCUMSTANCES None

DECEDENT INFO

1 NAME (FIRST) Larry	2 (MIDDLE) Daniel Eugene	3 (LAST) Kaufman
AKA Daniel Kaufman		DOE TYPE/NUMBER ****
20 ADDRESS ****		21 CITY Rialto
		25 STATE CA
		23 ZIP 92377
6 SEX Male	14 RACE White	4 DOB 08/12/1973
		5 AGE 42 yrs
RELATED CASE NUMBERS Yes		
BODY BAG # 5209175	TOE TAG 41375	10 SS # *****
		HEIGHT 68.5 in
		WEIGHT 195.0 lbs
		HAIR Brown
		EYES Blue
DRIVER S LIC # ****	STATE CA	HOW IDENTIFIED Positive ID by CAL-ID on 12-3-15 via Denise Little at 0341 hours.

LEGAL NEXT OF KIN

NAME Mark Sandefur	RELATIONSHIP Uncle/Legal NOK	DOB/AGE ****	DATE/TIME NOTIFIED 12/03/2015 1034	NOTIFIED BY L. Wells
ADDRESS ****		21 CITY Rialto	25 STATE CA	23 ZIP 92377
PHONE ****		ALTERNATE PHONE # ****		

PLACE/DEATH OCCURRED

7 DATE 12/02/2015	8 TIME 1204	DAY OF DEATH Wednesday	PRONOUNCED BY San Bernardino City Fire Department
101 PLACE OF DEATH Outside Conference Center		102 IP-ER/OP-DOA ****	FAC OTHER THAN HOSPITAL Other
105 FACILITY ADDRESS OR LOCATION WHERE FOUND 1425 S. Waterman Ave.		106 CITY San Bernardino	

INVESTIGATIVE SUMMARY

ADDITIONAL NARRATIVE ATTACHED YES NO

MASS SHOOTING INCIDENT – VICTIM 5 OF 14:

On Wednesday, December 2, 2015, at 1059 hours, a shooting incident was reported to the San Bernardino Police Department from the Inland Regional Center (IRC) in San Bernardino.

Two suspects, dressed in dark clothing, entered the south building and began indiscriminately shooting with semi-automatic rifles at the attendees of a Christmas party hosted for employees of the San Bernardino County Department of Public Health. The suspects left the scene prior to law enforcement arrival.

Law enforcement entered the building. Emergency medical services personnel removed multiple injured people to a triage point that was established directly across the street from the scene.

Two gunshot victims, a male and a female, designated as Victims #1 and #2, respectively, were pronounced dead at the triage point. Paramedics from the San Bernardino City Fire Department entered the auditorium and pronounced 12 victims dead at the scene.

Three victims, a female and two males, designated from south to north as Victims #3, #4 and #5, were pronounced dead outside the IRC conference room, on the east side of the building.

Nine victims, designated from east to west as Victims #6 through #14, were pronounced dead within the IRC auditorium.

All 14 victims died as a result of multiple gunshot wounds.

Victim #5 was subsequently identified by fingerprint comparison as Larry Daniel Eugene Kaufman, a 42 year old resident of Rialto.

The incident is under joint investigation by the San Bernardino Police Department and the Federal Bureau of Investigation.

Associated cases: 701509087, 701509088, 701509089, 701509090, 701509092, 701509093, 701509094, 701509095, 701509096, 701509097, 701509098, 701509099, and 701509100.

NOTE TO PATHOLOGY

San Bernardino County Sheriff - Coroner Division

Coroner Investigation

2

MODE Homicide

CASE # 701509091

Sub File To

701509087


STATUS Post

DEPUTY Lela Perriello

MEDICAL

TRANSPORTED FROM	ADMITTED TO?	DATE	TIME	M/R ORDERED	MED REC #	BLOOD ORDERED
N/A	N/A			No		Not Available

CAUSE OF DEATH

107 CAUSE (A)	TIME INTERVAL Minutes	109 BIOPSY PERFORMED?
Gunshot wound of the chest		<input type="checkbox"/> YES <input checked="" type="checkbox"/> NO
(B)		110 AUTOPSY PERFORMED?
		<input checked="" type="checkbox"/> YES <input type="checkbox"/> NO
(C)		AUTOPSY # EXAM #
		A1601-15 FS
(D)		INDIGENT #

112 OTHER SIGNIFICANT CONDITIONS CONTRIBUTING TO DEATH BUT NOT RELATED TO CAUSE GIVEN IN 107

113 WAS OPERATION PERFORMED FOR ANY CONDITION IN ITEM 107 OR 112? IF "YES" LIST TYPE OF OPERATION & DATE.

No

ATTENDING PHYSICIAN	PHONE	DATE LAST ATTENDED	CAUSE GIVEN BY
N/A			Frank Sheridan
115 PHYSICIAN TO SIGN D.C. Coroner	ADDRESS	PHONE	DATE
			12/04/2015
			TIME
			0000

INJURY

119 SPECIFY MODE	123 PLACE OF INJURY	120 AT WK?	121 DATE	122 HOUR
Homicide	Outside Conference Center	Yes	12/02/2015	1059

125 LOCATION (include Zip Code)

1425 S. Waterman Ave. San Bernardino 92408

DESCRIBE HOW INJURY OCCURRED

Shot by assailant(s).

PROPERTY

PROPERTY?	PROP RLS D?
<input checked="" type="checkbox"/> YES <input type="checkbox"/> NO	<input checked="" type="checkbox"/> YES <input type="checkbox"/> NO

LAW ENFORCEMENT

AGENCY	AGENT	REPORT NUMBER
San Bernardino Police Department (SBPD)	Det. William Flesher	2015-132854
FBI	TFO Jeff Chase	

AUTOPSY

ORDERED BY	DATE	TOX ORDERED	TOX RECEIVED	AGENT(S) TO ATTEND
ML	12/03/2015	12-04-2015	12/30/2015	****

DISPO OF REMAINS

PRESENT LOCATION	MORGUE STATUS	VEHICLE TOWED BY
****	****	
TRANSPORTED BY	NOTIFIED BY	DATE
****	****	****
		TIME

		ARRIVED

44 MORTUARY	PHONE OF MORTUARY	
****	****	

<input checked="" type="checkbox"/>	REVIEWED BY	Emon	12/04/2015 03:58
-------------------------------------	-------------	------	------------------

San Bernardino County Sheriff - Coroner Division

Coroner Investigation

3

MODE **Homicide**

CASE # **701509091**

Sub File To

701509087

STATUS **Post**

DEPUTY **Lela Perriello**



Coroner Investigation

12/03/2015

NOTIFICATION TO THE CORONER DIVISION:

On Wednesday, December 2, 2015, at 1208 hours, the San Bernardino County Coroner's Office received a report of multiple fatalities resulting from a shooting at the Inland Regional Center (IRC), located at 1425 S. Waterman Ave., in San Bernardino.

Coroner chain of command personnel, including the division commander, Captain Kevin Lacy, responded to the Incident Command Post (ICP) established just north of the incident location, and began coordinating with the investigating agencies that included the San Bernardino Police Department (SBPD), which would have primary investigative responsibility, the San Bernardino County Sheriff's Department (SBCSD), the Federal Bureau of Investigation, Bureau of Alcohol, Tobacco, Firearms and Explosives, Department of Homeland Security, and other supporting agencies.

PRELIMINARY LAW ENFORCEMENT INFORMATION:

According to Capt. Lacy, the preliminary incident assessment was as follows:

At 1059 hours, a shooting incident was reported to the SBPD from the IRC, where a Christmas party was being hosted for employees of the San Bernardino County Department of Public Health. Witnesses subsequently reported that at least two suspects, dressed in dark clothing and wearing ski masks, entered the south building and began indiscriminately shooting with semi-automatic rifles. Following the shooting, the suspects fled in a black sport utility vehicle.

Law enforcement entered the building and extracted survivors. Emergency medical services personnel assisted multiple injured persons to a triage point that was established directly across the street from the scene.

VICTIM INFORMATION:

It was subsequently learned that multiple attendees were injured; 21 were transported to local hospitals and 14 victims were pronounced dead at the scene.

Two gunshot victims, a male and a female, designated as Victims #1 and #2, respectively, were pronounced dead at the triage point. Paramedics from the San Bernardino City Fire Department pronounced three victims dead outside the south building conference room and pronounced nine victims dead inside the conference room.

Three victims, a female and two males, designated from south to north as Victims #3, #4 and #5, were pronounced dead outside the conference room, on the east side of the building. Nine victims, designated from east to west as Victims #6 through #14, were pronounced dead within the IRC conference room.

Additional briefings were conducted at the Coroner Division to activate a Family Assistance Center and a scene response plan was prepared.

SCENE DESCRIPTION: EAST SIDE OF EXTERIOR OF SOUTH BUILDING

I was assigned to respond with Deputy Coroner Investigator C. Rhea-Hudgens and Deputy Coroner Investigator M. Leyva to the scene in order to coordinate the Coroner response for the investigation and recovery of remains.

On 12/03/2015 at 0052 hours, we responded from the Coroner Division in San Bernardino and arrived at 0111 hours. There we met with SBPD Det. William Flesher, who was assigned to act as our primary liaison.

The Inland Regional Center (1365 S. Waterman Ave.) was located on the east side of Waterman Ave., surrounded by Park Center Circle. The primary complex consisted of three large buildings on approximately five acres. The buildings were surrounded by paved parking lots encircling the complex. The two northern buildings were multi-story structures (from north to south, 1365 and 1395 S. Waterman Ave, respectively). The south building (1425 S.

San Bernardino County Sheriff - Coroner Division

Coroner Investigation

4

MODE **Homicide**

CASE# **701509091**

Sub File To

701509087



STATUS **Post**

DEPUTY **Lela Perriello**

Waterman Ave.), which contained multi-purpose rooms, consisted of two floors. There were glass entrance doors to the north and three doors located on the east side, accessing the east parking lot.

The glass doors on the east side of the building were designated as follows:

1. South door
2. Center door (Glass door was shattered)
3. North door

There was a sidewalk that ran north and south next to the east side of the building. There was a bench located between the south and central door on the west side of the sidewalk. There was a bench located in front of the center door on the east side of the sidewalk. There was a bench located between the center door and north door on the west side of the sidewalk. There were three metal table and chair sets located to the east and northeast of the north door.

Three decedents, designated as Victim #3 (701509089), Victim #4 (701509090), Victim #5 (701509091), were located outside the east side of the south building. Victim #3 lay on the sidewalk about 6'4" southeast of the center door. Victim #4 was seated on the bench about 14'5" northeast of the center door. Victim #5 lay about 21'2" east of the north door near a table.

The metal table and chair set contained four seats attached to the table. A pack of cigarettes, a lighter, food in a plastic container, and a spoon in the food, were on the table. There was a large defect, possibly from a bullet strike, in the backrest portion of the southwest chair.

On scene, we received information that there may have been explosives in the building with one or more detonated. It was later determined there were no explosives detonated inside the building.

EXAMINATION OF THE BODY OF VICTIM #5 (LARRY DANIEL KAUFMAN):

I began my examination of the body at 0145 hours. I stopped the exam at 0220 hours due to a possible explosive device located inside the building. I cleared the scene at 0238 hours and submitted fingerprints to CAL-ID. I returned to the scene at 0315 hours and resumed the body exam.

The body was mainly supine on the ground to the south of the metal table and chair set. The left leg was raised and the calf was resting on the seat portion of the southwest chair. The right leg was abducted with the knee pointing to the north east, the knee was bent, and the lower portion of the leg was over the metal bar connecting the chair to the table. The head was to the south. The left arm was extended straight from the torso with the hand pointed to the southwest. The right, upper arm was perpendicular to the torso, the elbow was bent, and the hand was pointed to the south. (It appeared the decedent had been sitting in the southeast chair and fell to his right.)

The body was that of a White male, appearing to be about 5'9" tall and 175 pounds.



San Bernardino County Sheriff - Coroner Division

Coroner Investigation

5

MODE **Homicide**

CASE # **701509091**


Sub File To

701509087



STATUS **Post**

DEPUTY **Lela Perriello**



IDENTIFICATION:

On Scene:

I located a wallet in the decedent's rear pants pocket and a California driver license was inside. The name on the license was L. Daniel Eugene Kaufman, a 42 year old male resident of Rialto.

Confirmation:

On 12/3/15 at 0341 hours, the decedent was confirmed to be Larry Daniel E. Kaufman by fingerprints submitted to CAL-ID.

BODY TRANSPORTED TO CORONER MORGUE FACILITY:

Coroner Morgue personnel, Autopsy Assistants Mark Schrader and Karina Gomez, transported the body from the scene at 0349 hours to the Coroner Morgue Facility in San Bernardino, arriving at 0355 hours.

NOTIFICATION OF DEATH TO NEXT OF KIN:

On 12/03/2015 at 1034 hours, the notification of death to family was made by Deputy Coroner Investigator L. Wells.

DISPOSITION:

Submitted to pathology for autopsy.

San Bernardino County Sheriff - Coroner Division

Coroner Investigation

6

MODE **Homicide**

CASE # **701509091**

Sub File To

701509087




STATUS **Post**

DEPUTY **Lela Perriello**

Coroner Supplemental Report

12/04/2015

Investigator: Lisa Wells



175 South Lena Road
San Bernardino, CA 92415-0037
(909) 387-2542
Fax (909) 387-2989



Frank Sheridan, M.D.
Chief Forensic Pathologist

_____, M.D.
Forensic Pathologist

**San Bernardino County Sheriff's Department
Coroner Division**

Autopsy Protocol

Coroner's Case Number: 701509091

Autopsy Number: A-1601-15

Name: Larry Daniel Eugene Kaufman **Age:** 42 **Sex:** Male
Time of Death: Reported 1204 hours, December 2, 2015 **Race:** White
Time of Autopsy: 0945 hours, December 4, 2015
Place of Autopsy: San Bernardino County Coroner's Facility **Deputy:** Perriello

HISTORY OF DEATH: The history as obtained by the deputy coroner investigating officer is to the effect that on Wednesday, December 2, 2015 at 1059 hours an active shooting incident was reported to San Bernardino Police Department from the Inland Regional Center (IRC) in San Bernardino. Reportedly two suspects dressed in dark clothing had entered the south building and had begun shooting with semi-automatic rifles at the attendees of a Christmas party hosted for employees of the San Bernardino County Department of Public Health. The suspects had fled the scene prior to the arrival of law enforcement.

Law enforcement made entry into the building and emergency medical personnel set up a triage point directly across the street from the scene.

Two victims were pronounced dead at the triage point. Three other victims were pronounced dead outside the IRC conference room on the east side of the building and nine victims were pronounced dead within the IRC conference room.

All of the fourteen victims died as a result of gunshot wounds.





Reference: 701509087, A-1609-15, Shannon Hilliard Johnson
701509088, A-1608-15, Beneta Bet-Badel
701509089, A-1608-15, Aurora Luz Godoy
701509090, A-1610-15, Isaac G. Amanios Gebreslassie
701509092, A-1625-15, Harry Albert Bowman
701509093, A-1605-15 Yvette Alexandra Velasco
701509094, A-1617-15 Sierra Simone Clayborn
701509095, A-1619-15, Robert C. Adams
701509096, A-1604-15, Nicholas James Thalasinis

KAUFMAN AUTOPSY CONTINUED
PAGE 2
A-1601-15

701509097, A-1618-15, Tin Thanh Nguyen
701509098, A1620-15, Juan Espinoza
701509099, A1626-15, Damian Lawrence Meins
701509100, A-1600-15 Michael Raymond Wetzel

Also refer to Coroner's Investigative Report 701509091.





Injuries: The injuries described below are depicted in the accompanying diagram.

Posterior Torso: There are three gunshot wounds in the back of the chest, one in the right scapular area, one in the left lower chest and one in the right posterior shoulder area.

The gunshot wound in the right scapular area is situated 54 inches above the sole of the right foot and approximately 1 inch to the right of the midline. The wound is oval shaped, obliquely oriented from lower medial to upper lateral. The wound length is 8 mm, the width 4 mm. The lower medial edge of the wound is abraded, the abrasion about 3 mm in width. There is no associated soot or stippling.

The wound in the lower left posterior chest is at a height of 48 inches above the sole of the left foot. The wound is obliquely oriented from lower lateral to upper medial. The wound measures about 7 mm in length and about 4 mm in width. The lower medial edge is abraded to a width of about 2 mm. There is no associated soot or stippling.

There is a gunshot wound in the back of the right shoulder at a height of 59 inches above the sole of the right foot. The wound is approximately oval shaped measuring about 15 x 12 mm and has torn, non-abraded, partially avulsed edges. There is no associated soot or stippling.

Anterior Torso: There are three gunshot wounds on the front of the torso.

There is a large gaping gunshot wound consistent with an exit wound in the left pectoral area. The center of the wound is situated approximately 54 inches above the sole of the left foot. The wound is irregular in shape, measuring about 5-6 cm in diameter, with torn non-abraded edges.

There is a large gaping exit gunshot wound at the apex of the right axilla, the center of which is about 53-1/2 inches above the sole of the right foot. The wound has torn, non-abraded edges and is irregularly shaped measuring about 5 x 2 cm. There is no associated soot or stippling. There is palpable deformity of the neck of the right humerus.

There is a gunshot wound of entry in the left anterolateral chest wall 50 inches above the sole of left foot. The wound is in approximately the anterior axillary line. The wound is approximately circular with a total diameter of about 1 cm. The lower lateral edge is abraded to a width of about

3-4 mm. There is no associated soot or stippling.

Right Upper Extremity: There are three or four small abrasions on the back of the right hand, one over the back of the proximal interphalangeal joint measuring about 3 mm in diameter, another on the back of the second metacarpophalangeal joint measuring about 4 mm in diameter, and a curvilinear 2.5 cm abrasion on the dorsum of the hand. There are several very small superficial punctate injuries on the thenar eminence with associated ecchymosis. There are also two slightly larger wounds in this area, each about 2 mm in diameter, and there is another wound on the palmar surface of the right thumb over the proximal phalanx. The latter wound is about 3 to 4 mm in width with surrounding ecchymosis. Immediately proximal to the right wrist on the volar surface of the forearm is a slit shaped wound, horizontally oriented, measuring about 12 mm x 3 mm. There is surrounding ecchymosis and there is hemorrhage in the depths of the wound. Also noticed in the depths of the wound is a small metallic copper-colored fragment. The fragment is deformed and measures about 1 cm x 7 mm. There is attached black wooly fabric attached to it consistent with the fabric of the hooded jacket described earlier.

Left Upper Extremity: There are multiple superficial wounds on the back of the left hand, wrist and forearm with a few smaller scattered superficial wounds above the elbow. There is one superficial linear wound on the palm of the hand. The wounds on the back of the hand number at least 20, most of which are punctate or linear. The wounds are red and some have surrounding ecchymosis. Within this area are also two small abrasions situated over the back of the second metacarpophalangeal joint of the second finger and between the second and third fingers. Proximal to the main cluster of wounds on the back of the hand and wrist is a vertically oriented superficial wound measuring 3.5 cm in length and up to about 4 to 5 mm in width. There is surrounding ecchymosis and there are also a few small surrounding punctate superficial small injuries. Proximal to the wrist is another elongated, slightly curvilinear 3.5 cm long vertically oriented superficial wound measuring about 2 mm in width with surrounding ecchymosis. Proximal to this and towards the radial side of the back of the forearm is a deeper wound, vertically oriented, measuring about 4 cm in length and up to 12 mm in width. This wound goes through the full thickness of the skin, exposing underlying fascia and muscle. Proximal to the above, on the upper part of the forearm, are at least four superficial linear vertically oriented injuries ranging from about 15 mm to about 8 mm in length with surrounding ecchymosis. In addition to the above, on the back of the upper arm are two, possibly three, very small punctate like superficial injuries ranging from about 2 mm to 1 mm in diameter. The wounds described here on the back of the hand, wrist, forearm and upper arm are consistent with one gun discharge with an intermediate target, resulting in fragmentation of the bullet. The trajectory appears to be upwards in relation to the standard anatomical position.

On the anteromedial aspect of the upper left arm is a patterned red abrasion consisting of two parallel linear marks, one 5 cm in length, the other about 4 cm with a faint additional linear mark of about 4.5 cm linking the two, forming an approximately square or rectangular pattern. There are no gunshot wounds or fragment injuries in this area.

INTERNAL EXAMINATION:

CHEST & ABDOMEN: There is minimal muscle hemorrhage in the left pectoralis muscle associated with the gunshot wound of entrance wound in the left anterolateral chest wall. The bullet path from this entrance wound goes up through the musculature of the anterior chest wall without entering the chest cavity and exits through the large exit wound in the upper left pectoral area. A blunt probe is readily passed along the wound track but there is minimal hemorrhage along the length of the track, which is primarily through the subcutaneous fat.

Summary of Gunshot Wound: The gunshot wound entering the left anterolateral chest wall is of indeterminate range. The bullet path is through the subcutaneous tissue of the anterior chest wall, the trajectory upwards and left to right (lateral to medial).

There are two foci of intercostal muscle hemorrhage on the right side, one in the right chest wall adjacent to the right axilla, the other over the right 5th and 6th ribs. There are posterior fractures of the 2nd, 3rd and 4th right ribs and anterolateral fractures of the right 5th and 6th ribs. There is at least 500 ccs of blood in the right pleural cavity.


The bullet path from the entry wound in the left lower posterior chest goes into the spinal column at T9-T10, extensively fracturing the spine in this area. The bullet then appears to have fragmented with two resulting paths through the right lung, both exiting in the right axilla. Dissection of the spine at T9-T10 reveals blood in the subdural space. The spinal cord is contused but not transected.


Summary of Gunshot Wound: The gunshot wound of entry in the lower posterior chest is of indeterminate range. The trajectory is left to right, upwards and slightly back to front.

The bullet path from the entry wound in the right scapular area passes through the posterior musculature of the upper posterior chest wall, fracturing the right posterior 2nd, 3rd and 4th ribs and continuing into the right shoulder. There is a displaced fracture of the neck of the humerus. There are a few scattered tiny metallic fragments on x-ray in this area but the most of the bullet exited through the exit wound in the right upper posterior shoulder area.

Summary of Gunshot Wound: The gunshot wound of entry in the right scapular area is of indeterminate range. The trajectory is left to right and upwards through the musculature of the posterior chest wall and the right shoulder joint. There is no penetration of the chest cavity.

There is no other evidence of trauma to the chest, abdomen or pelvis. The clavicles and sternum are intact. The ribs, apart from those mentioned above, are intact. The thoracic and lumbar spine and pelvis are intact, apart from T9 and T10. The pleural, pericardial and peritoneal membranes are smooth and glistening. There is no abnormal fluid accumulation in the pericardial cavity, left pleural cavity or peritoneal cavity.





- DIAGNOSIS:**
- I. 42-year-old male; one of fourteen individuals shot dead at Inland Regional Center.
 - A. Multiple gunshot wounds.
 - 1. Indeterminate range gunshot wound of entry in left lower posterior chest with bullet path through thoracic spine and right lung with partial fragmentation and exit wound in the right axilla.
 - a) Right hemothorax.
 - 2. Indeterminate range gunshot wound of entry in right scapular area with bullet path through posterior chest wall musculature and right shoulder with partial bullet fragmentation, fracture of the neck of the humerus, and exit wound in the back of the right shoulder.
 - 3. Indeterminate range gunshot wound of entry in left anterolateral chest with bullet path through anterior chest wall subcutaneous tissue to exit wound in the upper left pectoral area.
 - 4. Multiple fragment injuries from probable ricocheted bullet, left upper extremity.
 - 5. Multiple fragment injuries to palmar surface of right hand.
 - a) One copper-jacketed fragment retrieved from right wrist

B. [REDACTED]


C. [REDACTED]

CAUSE OF DEATH: Gunshot wound of the chest, minutes.

Manner of Death: Homicide

WITNESSES PRESENT: Angelica Ordonez and Sharon Binshire; San Bernardino Police Department; Elizabeth Hadley, Seth Witten, Natalie Arnold, Liza Fornaciari, and Victoria Milko; Federal Bureau of Investigation.

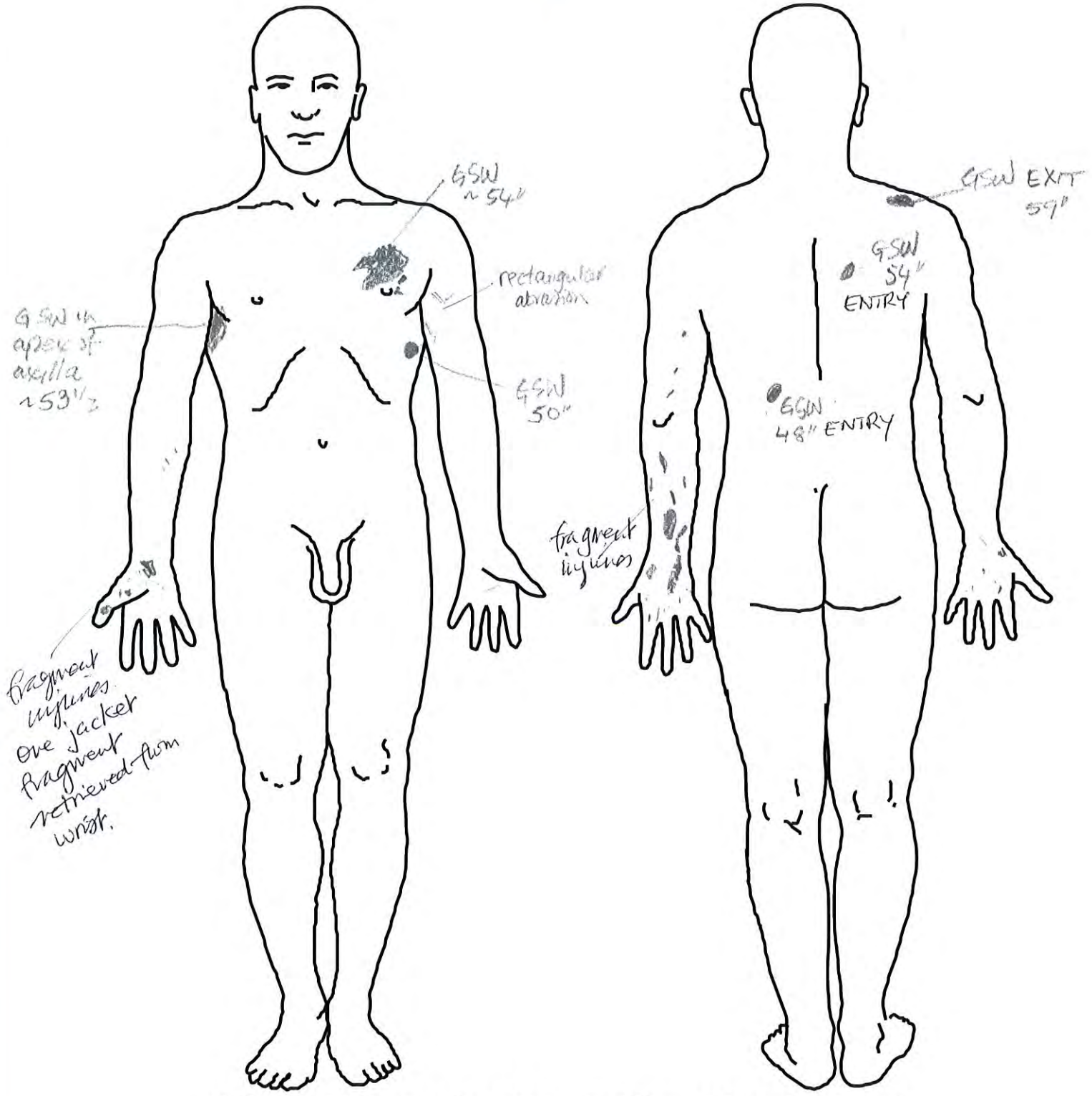
Autopsy Completed 1300 hours, December 4, 2015


Frank Sheridan, M.D.
Pathologist

Date: 3/14/16

FS:rlc

San Bernardino County Sheriff/Coroner



Full Body Male, Anterior & Posterior Views, (Ventral & Dorsal).

Name LARRY DANIEL EUGENE KAUFMAN Coroner's Case # 701509091 Autopsy No. A1601-15FS
Age 42 Race W Sex M Date 12/4/15