

CHRISTINA-TAYLOR GREEN

ML 11-00069

AUTOPSY REPORT

PIMA COUNTY, ARIZONA

PIMA COUNTY SHERIFF'S OFFICE

CASE # 110108078

JANUARY 10, 2011

ML 11-00069

Re: CHRISTINA-TAYLOR GREEN


Page 2

PATHOLOGIC DIAGNOSES:

1. Gunshot wound to torso with perforations of aorta, right kidney, stomach, small intestine, and left hemidiaphragm

OPINION:

Death of this female is due to a gunshot wound to the torso with perforation of the aorta and right kidney. The manner of death is certified as homicide.

 2-3-11
Eric D. Peters, M.D.
Forensic Pathologist

EDP/aef

ML 11-00069

Re: CHRISTINA-TAYLOR GREEN

Page 3

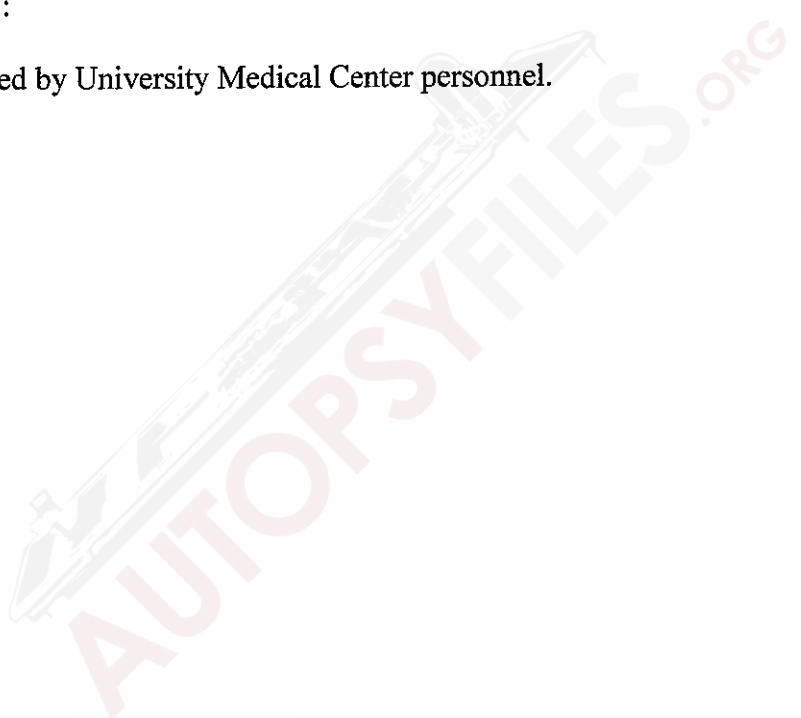
MEDICOLEGAL INVESTIGATION

AUTHORIZATION:

The postmortem examination is performed under the authorization of the Pima County Medical Examiner's Office.

IDENTIFICATION:

The body is identified by University Medical Center personnel.



ML 11-00069

Re: CHRISTINA-TAYLOR GREEN

Page 4

POSTMORTEM EXAMINATION

CIRCUMSTANCES OF THE EXAMINATION:

The postmortem examination of Christina-Taylor Green is performed at the Forensic Science Center, 2825 E. District Street, Tucson, Arizona on January 10, 2011 commencing at 8:40 AM. Assisting in the examination are Krystal Poulin, Louie Goad and Ernest Hernandez. X-rays of the entire body are made and retained.

GENERAL DESCRIPTION:

The body is received in an unsealed white vinyl pouch.

EXTERNAL EXAMINATION:

The body is of a light-skinned, well-developed, thin, 4' 11", 100 pound female whose appearance is consistent with the reported age of 9 years. The hair is thick, brown and of medium length. The irides are status post corneal harvest with corneal cups in place. The oral cavity contains natural teeth in good repair. The torso and extremities are well developed and unremarkable. The genitalia are of an unremarkable immature female. Each ear is pierced.

POSTMORTEM CHANGES:

Rigor mortis is strong throughout. Livor mortis is non-fixed and posterior. The body is cool.

CLOTHING/BELONGINGS:

- 1) Yellow metal earrings with blue stones are in place.

THERAPEUTIC PROCEDURES:

Surgical incisions closed by surgical string are at both knee regions (Comment: status post bone and soft tissue harvest). A chest tube exits the right lateral torso through a 1-7/8 inch long incision. Beneath the left nipple is a thoracotomy incision, 8 inches, closed by suture material. Multiple therapeutic punctures are at the groins and at the clavicular regions.

Internally, a catheter secured by a single suture enters the right atrium.

ML 11-00069

Re: CHRISTINA-TAYLOR GREEN

Page 5

INJURIES, EXTERNAL AND INTERNAL:

There is a single perforating gunshot wound to the torso.

A gunshot entrance wound is at the right flank, 20 inches from the top of the head and 4-1/4 inches right of the posterior midline. It is a 1/4 inch circular perforation with a 1/32 – 1/16 inch red rim of abrasion. There is no fouling or stippling.

After penetrating the skin and soft tissues of the right flank, the bullet entered the abdomen perforating the mid-portion of the right kidney. The bullet then passed upward and leftward to perforate the aorta just superior to the take-off of the renal arteries, a small intestinal loop, the posterior aspect of the stomach (two defects), and the left hemidiaphragm before exiting the left lateral chest cavity through the seventh intercostal space. There is a slight amount of left lingula hemorrhage without perforation. There is approximately 500 – 1000 ml of blood in the abdominal cavity.

The bullet exited the left chest through a 1/2 inch slit-like defect, 17-1/2 inches from the top of the head and 5 inches left of the anterior midline. The exit wound is surrounded by a 2-1/2 x 2-1/2 inch purple contusion. There is no fouling or stippling.

No bullet is recovered.

The direction this bullet traveled is right-to-left, back-to-front and upward.

These injuries, having been described, will not be repeated.

INTERNAL EXAMINATION:

Head:

The scalp has no contusion. The skull has no fracture. The leptomeninges are clear, thin, and delicate. There is no epidural, subdural or subarachnoid hemorrhage. The gray and white matter, deep nuclei, and ventricles are unremarkable. There is an unremarkable distribution of cerebral vessels and cranial nerves. The brain weighs 1440 gm.

Neck Organs:

The cervical vertebrae, hyoid bone, and tracheal and laryngeal cartilages are unremarkable. The base of the tongue and paratracheal soft tissues are unremarkable.

Body Cavities:

There are no fibrous adhesions in any of the body cavities.

ML 11-00069

Re: CHRISTINA-TAYLOR GREEN

Page 6

Cardiovascular System:

The aorta is without atherosclerosis. The venae cavae and pulmonary arteries are without thrombus or embolus. The heart weighs 200 gm and has an unremarkable distribution of right dominant coronary vessels without atherosclerotic stenoses. The myocardium is uniformly red-brown without hemorrhage, softening, fibrosis or pallor. The left ventricle is 1.1 cm thick. The endocardial surfaces and four cardiac valves are unremarkable.

Respiratory System:

The right lung weighs 170 gm; the left lung weighs 130 gm. Both lungs are dark red without consolidation or obstruction. There are no mass lesions. The bronchial vasculature and architecture are unremarkable.

Liver, Gallbladder and Pancreas:

The liver weighs 880 gm, has an intact, smooth capsule, and a medium brown parenchyma without slippery or fibrous texture. The gallbladder is unremarkable and contains approximately 10 ml of green bile without calculi. The pancreas is of normal lobulation, color, and texture.

Hemic and Lymphatic Systems:

The spleen weighs 60 gm, has an intact, smooth capsule, and a dark red parenchyma without prominent white pulp. There are no lymph node enlargements.

Genitourinary System:

The right kidney weighs 90 gm; the left kidney weighs 90 gm. Both kidneys have smooth subcapsular surfaces with an unremarkable underlying architecture and vasculature. Both ureters are normal caliber and drain into an unremarkable bladder that is empty. The fallopian tubes, ovaries, uterus, cervix, and vagina are unremarkable.

Endocrine System:

The pituitary, thyroid, and adrenal glands are of normal size, color and consistency.

Digestive System:

The esophagus and gastroesophageal junction are unremarkable. The stomach contains negligible brown-red fluid including numerous unidentifiable partially digested chunks of food. There are no pill or tablet fragments. The gastric mucosa, duodenum, remainder of small intestines, appendix, and large intestines are unremarkable.

Musculoskeletal System:

The clavicles, sternum, vertebrae, ribs, and pelvis are without fracture. The musculature is normally distributed and unremarkable.