

JOHN MCCARTHY ROLL

ML 11-00064

AUTOPSY REPORT

PIMA COUNTY, ARIZONA

PIMA COUNTY SHERIFF'S OFFICE

CASE # 110108078

JANUARY 9, 2011

ML 11-00064

Re: JOHN MCCARTHY ROLL


Page 2

PATHOLOGIC DIAGNOSES:

- 1) Gunshot wound to torso, with:
 - a) Perforation of aorta and resultant hemoperitoneum
 - b) Perforation of small intestines
- 2) Blunt impact to head and left upper extremity without underlying vital injury

OPINION:

Death of this man is due to gunshot wound to the torso with perforation of the aorta. The manner of death is certified as homicide.

 2-3-11
Eric D. Peters, M.D.
Forensic Pathologist

EDP/aef

ML 11-00064

Re: JOHN MCCARTHY ROLL

Page 3

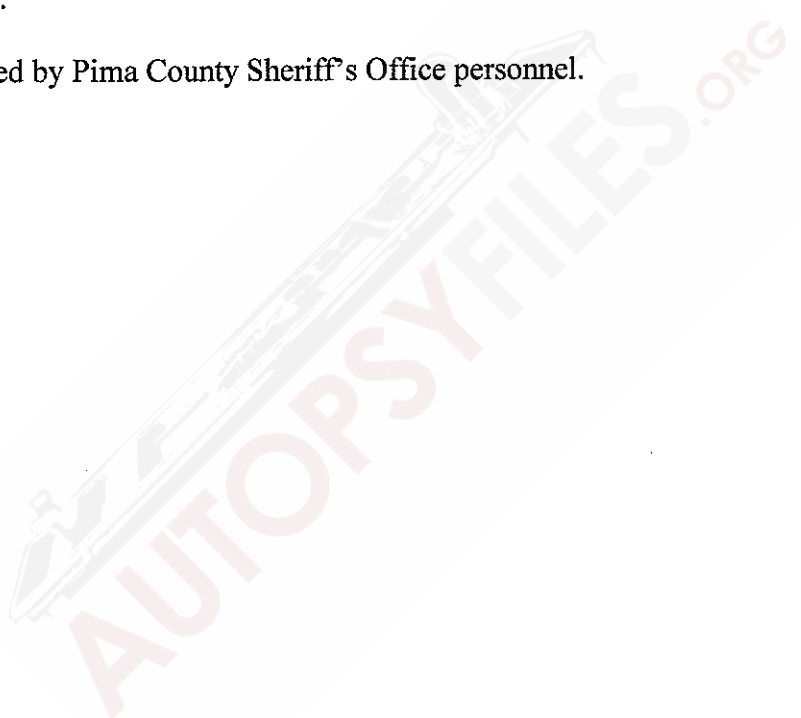
MEDICOLEGAL INVESTIGATION

AUTHORIZATION:

The postmortem examination is performed under the authorization of the Pima County Medical Examiner's Office.

IDENTIFICATION:

The body is identified by Pima County Sheriff's Office personnel.



ML 11-00064

Re: JOHN MCCARTHY ROLL

Page 4

POSTMORTEM EXAMINATION

CIRCUMSTANCES OF THE EXAMINATION:

The postmortem examination of John Roll is performed at the Forensic Science Center, 2825 E. District Street, Tucson, Arizona on January 9, 2011 commencing at 10:40 AM. Assisting in the examination are Louie Goad, Krystal Poulin and Ernest Hernandez. X-rays of the abdomen are made and retained.

GENERAL DESCRIPTION:

The body is received in a sealed white vinyl pouch.

SCENE DESCRIPTION:

I arrived at 7110 N. Oracle Road (Safeway Shopping Center) at approximately 5:45 PM on January 8, 2011 where I was met by personnel from the Pima County Sheriff's Office and the Federal Bureau of Investigation. This was the site of a multiple shooting with five dead at the scene. This decedent was supine with full rigor mortis and blanchable dependent livor mortis. The body was cool. There was one perforating gunshot wound to the torso (See description below). The hands were bagged and the decedent was removed to the Office of the Medical Examiner for examination.

EXTERNAL EXAMINATION:

The body is of a light-skinned, well-developed, well-nourished, 6' 1", 178 pound man whose appearance is consistent with the reported age of 63 years. The hair is thick, brown with gray and up to 6 inches. The nose and ears are well-formed. The irides are brown and the conjunctivae are anicteric without petechiae or hemorrhage. The oral cavity is atraumatic and contains natural teeth. The torso and extremities are well developed and unremarkable. The genitalia are of a circumcised adult with descended testes.

POSTMORTEM CHANGES:

Rigor mortis is strong throughout. Livor mortis is non-fixed and posterior. The body is cool.

ML 11-00064

Re: JOHN MCCARTHY ROLL

Page 5

CLOTHING/BELONGINGS:

On or accompanying the body are:

- 1) One black leather jacket
- 2) One blue shirt
- 3) One white undershirt
- 4) One pair of stone-colored pants
- 5) One black belt
- 6) One pair of white socks
- 7) One pair of white sneakers
- 8) One white and yellow metal wrist watch at left wrist
- 9) One yellow metal ring at left fourth finger

Note: Perforations of the back of the leather jacket, and back and front of both the undershirt and blue shirt are present corresponding to the underlying perforating gunshot wound described below. See Personal Effect Receipt for other items not catalogued above.

INJURIES, EXTERNAL AND INTERNAL:

There is a single perforating gunshot wound to the torso. There are blunt impact injuries to the head and left upper extremity.

Gunshot Wound to Torso:

A gunshot entrance wound is at the left lower back, 24 inches from the top of the head and 3 inches left of midline. It is a 1/4 inch circular perforation with a 1/16 inch red rim of abrasion at the upper outer margin and a negligible red rim of abrasion at the remaining margins. There is no fouling or stippling. (Comment: there is slight amount of grey bullet wipe discoloration to the perforation at the back of the white undershirt).

After penetrating the skin and soft tissues of the left lower back, the bullet passed rightward, forward, and slightly downward, perforating the entire posterior aspect of the descending aorta approximately 2 inches inferior to the take-off of the renal arteries. There is approximately 1.5 – 2 liters of blood and blood clot in the abdominal cavity. The bullet then passed through a few small intestinal loops before exiting the right lower abdominal quadrant.

The exit wound lies 27-3/4 inches from the top of the head and 3-1/2 inches right of midline. It is a 1/8 inch circular perforation with a 1/8 inch red symmetric rim of abrasion (Comment: shored exit wound). There is no fouling or stippling.

ML 11-00064

Re: JOHN MCCARTHY ROLL

Page 6

Gunshot Wound to Torso (cont'd):

No bullet is recovered.

The direction this bullet traveled is left-to-right, back-to-front, and slightly downward.

Blunt Impact to Head and Extremities:

There is a 1-1/2 inch red contusion with associated smaller 1/8 inch red abrasions at the left side of the forehead. There are a few small, up to 1/4 inch red abrasions, at the left mustache region. There is a 1/2 inch red abrasion along the outer aspect of the right eyebrow. There is a 1 inch curvilinear laceration of the left elbow.

These injuries, having been described, will not be repeated.

THERAPEUTIC PROCEDURES:

None.

INTERNAL EXAMINATION:

Head:

The scalp has no contusion. The skull has no fracture. The leptomeninges are clear, thin, and delicate. There is no epidural, subdural or subarachnoid hemorrhage. The gray and white matter, deep nuclei, and ventricles are unremarkable. There is an unremarkable distribution of cerebral vessels and cranial nerves. The brain weighs 1530 gm.

Neck Organs:

The cervical vertebrae, hyoid bone, and tracheal and laryngeal cartilages are unremarkable. The base of the tongue and paratracheal soft tissues are unremarkable.

Body Cavities:

There are no fibrous adhesions in any of the body cavities.

Cardiovascular System:

The aorta has slight atherosclerosis. The venae cavae and pulmonary arteries are without thrombus or embolus. The heart weighs 360 gm and has an unremarkable distribution of right dominant coronary vessels without atherosclerotic stenoses. The myocardium is uniformly red-brown without hemorrhage, softening, fibrosis or pallor. The left ventricle is 1.2 cm thick. The endocardial surfaces and four cardiac valves are unremarkable.

ML 11-00064

Re: JOHN MCCARTHY ROLL

Page 7

Respiratory System:

The right lung weighs 480 gm; the left lung weighs 420 gm. Both lungs are dark red without hemorrhage, consolidation or obstruction. There are no mass lesions. The bronchial vasculature and architecture are unremarkable.

Liver, Gallbladder and Pancreas:

The liver weighs 1590 gm, has an intact, smooth capsule, and a medium brown parenchyma without slippery or fibrous texture. The gallbladder is unremarkable and contains approximately 20 ml of green bile without calculi. The pancreas is of normal lobulation, color, and texture.

Hemic and Lymphatic Systems:

The spleen weighs 100 gm, has an intact, smooth capsule, and a dark red parenchyma without prominent white pulp. There are no lymph node enlargements.

Genitourinary System:

The right kidney weighs 160 gm; the left kidney weighs 160 gm. Both kidneys have smooth subcapsular surfaces with an unremarkable underlying architecture and vasculature. Both ureters are normal caliber and drain into an unremarkable bladder containing approximately 500 ml of clear, yellow urine. The testes are unremarkable.

Endocrine System:

The pituitary, thyroid, and adrenal glands are of normal size, color and consistency.


Digestive System:

The esophagus and gastroesophageal junction are unremarkable. The stomach contains approximately 250 ml of brown nondescript fluid including a single partially digested gel tab. The gastric mucosa, duodenum, remainder of small intestines, appendix, and large intestines are unremarkable.

Musculoskeletal System:

The clavicles, sternum, vertebrae, ribs, and pelvis are without fracture. The musculature is normally distributed and unremarkable.

TOXICOLOGY (SEE ATTACHED REPORT)



AIT Laboratories

A HIGHER STANDARD OF SERVICE™

2265 Executive Drive, Indianapolis, IN 46241
 Telephone: (800) 875-3894 / Fax: (317) 243-2789

LABORATORY CASE NUMBER: 1494895	Subject's Name: ROLL, JOHN
Client Account: 13399 / FSC01-PETERS Physician: Report To: Forensic Science Center ATTN: Dr. Eric Peters 2825 E. District Street Tuscon, AZ 85710 Fx: 520-243-8610	Agency Case#: 11-00064 Date of Death: 01/08/2011 Test Reason: Other Investigator: Date Received: 01/13/2011 Date Reported: 01/24/2011

Laboratory Specimen No: 40205845	Date Collected: 01/09/2011
Container(s) :01: Red Top Tube Blood, CAVITY, NOT	Test(s) : 70615 Drugs of Abuse Panel, Blood


Analyte Name	Result	Concentration	Units	Therapeutic Range	Loc
AMPHETAMINES	Negative				
BARBITURATES	Negative				
BENZODIAZEPINES	Negative				
CANNABINOIDS	Negative				
COCAINE/METABOLITES	Negative				
FENTANYL	Negative				
METHADONE/METABOLITE	Negative				
OPIATES	Negative				
PHENCYCLIDINE	Negative				
PROPOXYPHENE/METABOLITE	Negative				
SALICYLATES	Negative				
ALCOHOLS	Negative				
Methanol	Negative				
Ethanol	Negative				
Acetone	Negative				
Isopropanol	Negative				

Specimens will be kept for one year from the date received.

ROLL, JOHN

Laboratory Case #: 1494895

Print Date/Time: 01/24/2011, 07:54:03



AIT Laboratories
A HIGHER STANDARD OF SERVICE™

2265 Executive Drive, Indianapolis, IN 46241
Telephone: (800) 875-3894 / Fax: (317) 243-2789

Laboratory Specimen No: 40205847	Date Collected: 01/09/2011
Container(s) : 01: Bottle-Yellow Urine, Random	Test(s) : 70080 Drugs of Abuse Panel (900U)


Analyte Name	Result	Concentration	Units	Therapeutic Range	Loc
AMPHETAMINES	Negative				
BARBITURATES	Negative				
BENZODIAZEPINES	Negative				
CANNABINOIDS	Negative				
COCAINE/METABOLITES	Negative				
METHADONE/METABOLITE	Negative				
OPIATES	Negative				
OXYCODONE/METABOLITE	Negative				
PHENCYCLIDINE	Negative				
ALCOHOLS	Negative				

ROLL, JOHN

Laboratory Case #: 1494895

Print Date/Time: 01/24/2011, 07:54:03

EP



AIT Laboratories
A HIGHER STANDARD OF SERVICE[®]

2265 Executive Drive, Indianapolis, IN 46241
Telephone: (800) 875-3894 / Fax: (317) 243-2789

Laboratory Specimen No: 40205848	Date Collected: 01/09/2011
Container(s) : 01: Vitreous Vitreous, EYE	Test(s) : 70570 Autopsy Panel, Volatiles (900V1)

Analyte Name	Result	Concentration	Units	Therapeutic Range	Loc
ALCOHOLS	Negative				
Methanol	Negative				
Ethanol	Negative				
Acetone	Negative				
isopropanol	Negative				

AUTOPSYFILES.ORG

The Specimen identified by this Laboratory Specimen Number has been handled and analyzed in accordance with all applicable requirements.

ROLL, JOHN

Laboratory Case #: 1494895

Print Date/Time: 01/24/2011, 07:54:03

